

# Contribution of High-Resolution Manometry in Normal Endoscopic Dysphagia

S. Lajouad, I. Serraj, M. Salihoun, N. Kabbaj

Department of Functional Explorations of the digestive system - gastroenterology hepato, University Hospital Center Ibn Sina, Rabat – Morocco

DOI:10.21276/sjmps.2019.5.7.15

| Received: 15.07.2019 | Accepted: 24.07.2019 | Published: 30.07.2019

\*Corresponding author: Sanae Lajouad

## Abstract

**Introduction:** Dysphagia is a common reason for gastroenterology consultation. Esophageal manometry is recommended for the exploration of dysphagia, when gastroscopy is normal and esophageal biopsies are negative. The advent of high-resolution manometry (HRM) has led to the development of a new classification of esophageal motor disorders. The goal of this study is to evaluate the frequency and identify the type of esophageal motor disorders in dysphagic patients with normal upper digestive endoscopy. **Materials and Methods:** 141 patients with dysphagia with normal upper gastrointestinal endoscopy, negative esophageal biopsies and HRM were included. Esophageal motor disorders have been identified according to the Chicago classification. **Results:** HRM was pathological in 87 cases (61.7%). It revealed achalasia in 74 patients (52.5%). It was a type I achalasia in 23 patients (16.3%), type II in 44 patients (31.2%) type III in 7 cases (5%). It showed motor disorders that could correspond to scleroderma in 6 patients (4.2%), obstruction of the oesogastric junction in 4 cases (2.8%), and a jackhammer oesophagus in 3 cases (2.1%). HRM was normal in 54 patients (38.3%). **Conclusion:** The HRM of the esophagus represents an undeniable progress in the exploration of the motor system of the esophagus, mainly dysphagia with normal endoscopy. Achalasia, which can now be classified into 3 types according to HRM results, remains the most frequently found primary motor disorder.

**Keywords:** HRM, Dysphagia, Normal endoscopy, Achalasia.

**Copyright © 2019:** This is an open-access article distributed under the terms of the Creative Commons Attribution license which permits unrestricted use, distribution, and reproduction in any medium for non-commercial use (NonCommercial, or CC-BY-NC) provided the original author and source are credited.

## INTRODUCTION

Dysphagia is a frequent reason for consultation in gastroenterology. Esophageal manometry is recommended for the exploration of dysphagia, when gastroscopy is normal and esophageal biopsies are negative. The advent of high-resolution manometry (HRM) has led to the development of a new classification of esophageal motor disorders. The goal of this study is to evaluate the frequency and identify the type of esophageal motor disorders in dysphagic patients with normal upper digestive endoscopy.

## MATERIAL AND METHODS

141 patients with dysphagia with normal upper gastrointestinal endoscopy and negative esophageal biopsies received an HRM for digestive functional investigations at the Ibn Sina University Hospital Center in Rabat. Esophageal motor disorders have been identified according to the Chicago classification.

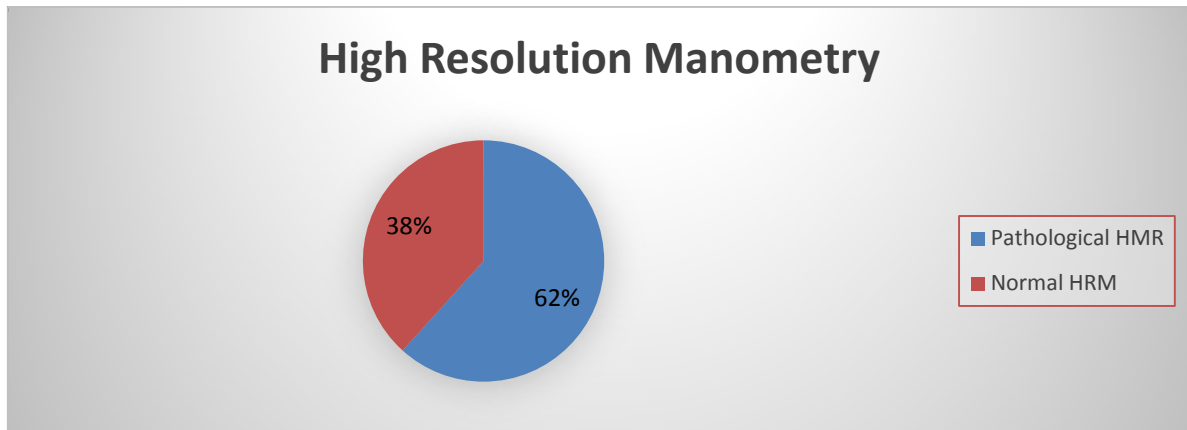
Some drugs that may affect digestive motility function were stopped before the HRM was performed in our patients, such as: calcium channel blockers;

nitrated derivatives; prokinetics; antispasmodics; anxiolytics; and neuroleptics.

All HRM were performed using a probe with 36 pressure sensors spaced 1 cm apart, inserted into the esophagus through the nose. Then the patient is placed in a lying position and asked to swallow small sips of water on a regular basis, which allows the functioning of the esophagus to be measured. The probe is removed after the examination. All HRMs were performed by an experienced and specially trained doctor who is assisted by a nurse. The examination will not cause pain, but the placement of the probe may be uncomfortable. The placement of the probe is done in 1 to 3 minutes and the entire procedure lasted about 20 minutes.

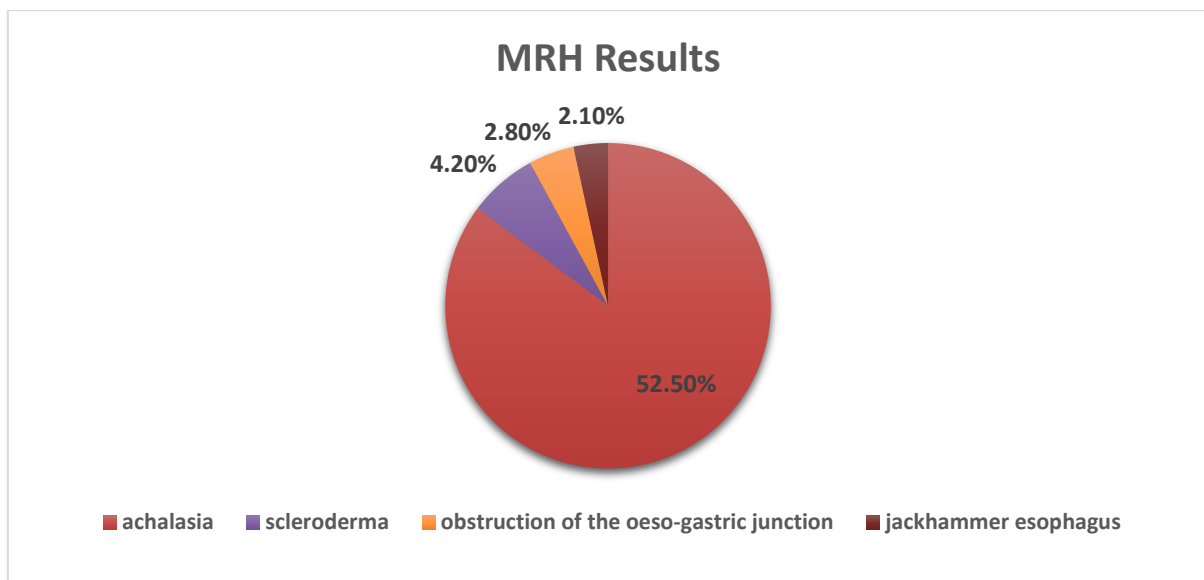
## RESULTS

From a total of 141 patients with dysphagia with normal upper gastrointestinal endoscopy and negative esophageal biopsies, HRM was pathological in 87 cases (61.7%) and normal in 54 patients (38.3%) (**Figure 1**). This was 50.4% men and 49.6% women with sex Ratio M/F=1. The average age of our patients was 42 years (16-71 years).



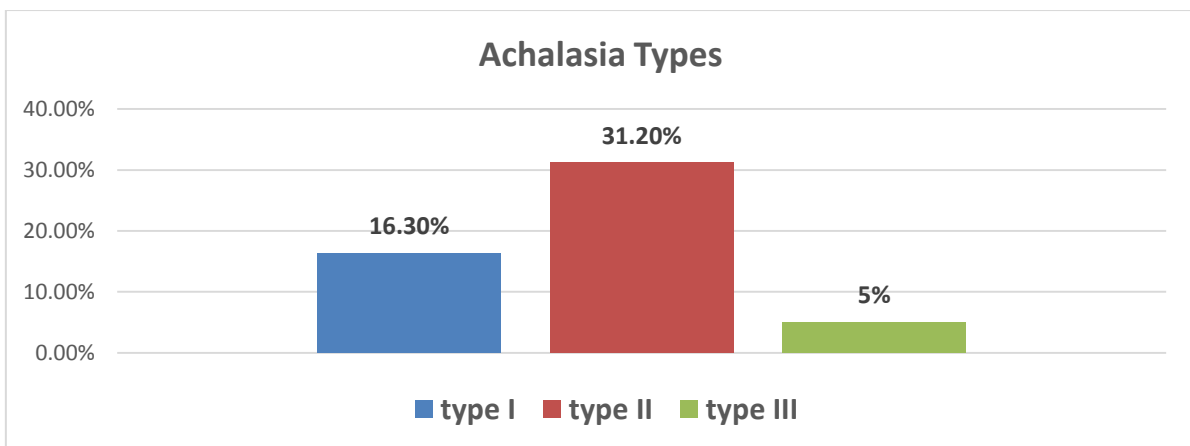
**Fig-1: High Resolution Manometry Results**

The results of HRM were as follows: achalasia in 74 patients (52.5%) scleroderma in 6 patients (4.2%), obstruction of the esophageal junction in 4 cases (2.8%), esophagus hammer-dryer in 3 cases (2.1%) (Figure 2).



**Fig-2: Anomalies found in the HRM**

It was type I achalasia in 23 patients (16.3%), type II in 44 patients (31.2%) type III in 7 cases (5%) (Figure 3).



**Fig-3: Achalasia Results**

## DISCUSSION

High resolution manometry (HRM) differs from conventional manometry by two innovations: the increase in the number of pressure measurement points and a topographical representation of pressure variations. The increase in the number of pressure sensors and the small space between two sensors (less than 2 cm) allow a more precise analysis of motor skills, especially in the sphincters. Thus, the functional anatomy of the sphincters and the different segments of the digestive tract can be studied [1].

A Tunisian study by Mahmoudi *et al.* was comparable to our study, involving 450 patients with the objective of determining the frequency and type of esophageal motor disorders in patients with non-obstructive dysphagia (NOD); high-resolution esophageal manometry was normal in 42.4% [2] and in our study was 38.3% of cases.

In our study, 61.7% of our NOD patients had esophageal motility disorders, achalasia being the most common diagnosis in our series. Our results are consistent with those of an earlier study by Burgess *et al.*, which also indicated that achalasia was the most common diagnosis in their cohort of NDD patients, while 9.8% of patients had normal manometry [3], the same results are described in a Taiwanese study by Chia-Chu Yeh *et al.* conducted on 120 NDD patients; 80% had disorders of oesophageal motility, achalasia being the most frequent diagnosis [4].

Similarly, Abbas *et al.* reported that NOD patients most often had achalasia (65.4%) [5]. Based on these results and current data, achalasia is the most common disorder in NOD patients and should always be considered in the initial differential diagnosis. Achalasia can be subdivided into three subtypes, with type II having the most favourable results [6]. The ratio of achalasia subtypes in this study was similar to that reported by Crespin *et al.* with Type II being the most common [7] as in our study.

According to the study by Mahmoudi *et al.*, the main motor abnormalities were achalasia found in 49% of cases, followed by sclerodermic esophagus in 17% of cases [2], in our study it was comparable, with achalasia and the main motor disorder found in 52.5% of cases followed by sclerodermic esophagus in 4.2% of cases.

The results of our study are consistent with those in the literature. Indeed, during non-obstructive dysphagia, achalasia is the most common motor disorder.

## CONCLUSION

The HRM of the esophagus represents an incontestable progress in the exploration of the motricity system of the esophagus, mainly dysphagia with normal endoscopy. Achalasia, which can now be classified to 3 types according to HRM results, remains the most frequently found primary motor disorder.

## REFERENCES

1. Fox, M. R., & Bredenoord, A. J. (2008). Oesophageal high-resolution manometry: moving from research into clinical practice. *Gut*, 57(3), 405-423.
2. Mahmoudi, M., Eljeri, K., Ayedi, S., Mouelhi, L., Houissa, F., Bouzaïdi, S., ... & Debbèche, R. (2014). Résultats de la manométrie œsophagienne au cours des dysphagies non obstructives. *La Revue de Médecine Interne*, 35, A162.
3. Burgess, N. G., & Wyeth, J. W. (2011). An audit of combined multichannel intraluminal impedance manometry in the assessment of dysphagia. *Journal of gastroenterology and hepatology*, 26, 79-82.
4. Yeh, C. C., Chen, C. C., Wu, J. F., Lee, H. C., Lee, Y. C., Liu, K. L., ... & Tseng, P. H. (2019). Etiologies and clinical characteristics of non-obstructive dysphagia in a Taiwanese population: A prospective study based on high-resolution impedance manometry. *Journal of the Formosan Medical Association*.
5. Yeh, C. C., Chen, C. C., Wu, J. F., Lee, H. C., Lee, Y. C., Liu, K. L., ... & Tseng, P. H. (2019). Etiologies and clinical characteristics of non-obstructive dysphagia in a Taiwanese population: A prospective study based on high-resolution impedance manometry. *Journal of the Formosan Medical Association*.
6. Pandolfino, J. E., & Gawron, A. J. (2015). Achalasia: a systematic review. *Jama*, 313(18), 1841-1852.
7. Crespin, O. M., Tatum, R. P., Xiao, K., Martin, A. V., Khandelwal, S., Pellegrini, C. A., & Oelschlager, B. K. (2017). The relationship between manometric subtype and outcomes of surgical treatment for patients with achalasia. *Surgical endoscopy*, 31(12), 5066-5075.