

A Study on Position of Minor Duodenal Papilla Related to Major Duodenal Papilla among South Indians - A Cadaveric Study

N. Vinay Kumar¹, S. Lokanadham^{2*}

¹Associate professor, Department of Anatomy, Government Medical College, East Yakkara, Palakkad, Kerala, India

²Assistant Professor, Department of Anatomy, Santhiram Medical College, Nandyal, Andhra Pradesh, India

Original Research Article

***Corresponding author**
S. Lokanadham

Article History

Received: 01.10.2018

Accepted: 09.10.2018

Published: 30.10.2018



Abstract: Recurrent pancreatitis is associated with minor duodenal papilla. Minor and major duodenal papillae are necessary for the endoscopist to perform the dilation, stenting, or papillotomy of the minor papilla. 50 formalin fixed cadavers (Male - 41; Female - 9) with age group ranged between 35 - 60 years from the departments of Anatomy, J.J.M Medical College, Davengere, Karnataka & Chennai Medical College, Trichy, Tamilnadu were utilized to study the position of minor duodenal papilla related to major duodenal papilla in pancreatoco-duodenal specimens. The minor duodenal papilla was present in 46 (92%) out of 50 specimens whereas in 4 specimens (8%) the minor duodenal papilla was absent. The position of the minor duodenal papilla in relation to that of major duodenal papilla was recorded. In 37 specimens (80.43%) it was anterosuperior to the major papilla and in 9 specimens (19.56%) it was directly superior to the major papilla and opens at second part of duodenum. The distance between the minor and major papillae varied from 1.3 cm to 4.3 cm, the average being 2.35 cm was noted and recorded in the present study. Endoscopy assisted surgeries need anatomical knowledge in understanding the position of the minor duodenal papilla relation to the major duodenal papilla and its clinical importance.

Keywords: Duodenum, major, major, papilla.

INTRODUCTION

The minor duodenal papilla may be difficult to locate because of the mucosal folds of duodenum [1]. Its oval or slit like orifice lies at its tip, the posterior tip raises a longitudinal fold, the plica longitudinalis. The orifice is commonly filled by villous like projections called valvules or valvulae. A diverticulum lying near the papilla may cause difficulty for surgeons or endoscopists [2]. Due to its smaller size it is difficult to identify its position than major duodenal papilla. The most useful landmark is the gastro duodenal artery, under which lie the accessory duct and the minor papilla [3]. The distance between Major and minor duodenal papilla is about 2cm normally but it is decreased in the presence of inflammation of the cap or the post bulbar region of the duodenum. The accessory pancreatic duct of Santorini opens into minor duodenal papilla approximately 2 cm cranial and slightly anterior to the major papilla. It consists of the accessory pancreatic duct; pancreatic tissue of the dorsal pancreas, which penetrate the muscularis propria of the duodenum; and the surrounding fibrous connective tissue [4]. The present study aimed to position the minor duodena papilla relation to major duodenal papilla in south Indians.

MATERIALS AND METHODS

50 formalin fixed cadavers (Male - 41; Female - 9) with age group ranged between 35 - 60 years from the departments of Anatomy, J.J.M Medical College, Davengere, Karnataka & Chennai Medical College, Trichy, Tamilnadu were utilized to study the position of minor duodenal papilla related to major duodenal papilla in pancreatoco-duodenal specimens and their clinical importance in south Indians. Pancreas was removed along with duodenum and dissected on its posterior surface to expose the main and accessory pancreatic ducts till their opening in to duodenal papilla. The duodenum was opened along its convex margin and the interior was cleaned to expose the mucosal surface and observed for location of major and minor duodenal papilla. The position of minor duodenal papilla in relation to major duodenal papilla and distance between both the papilla were noted and photographs of each specimen were taken by digital camera and labelled.

RESULTS

All the 50 specimens presented with major duodenal papilla opening at second part of duodenum were noted. The minor duodenal papilla was present in

46 (92%) out of 50 specimens whereas in 4 specimens (8%) the minor duodenal papilla was absent (Figure-1). The position of the minor duodenal papilla in relation to that of major duodenal papilla was recorded. In 37 specimens (80.43%) it was anterosuperior to the major papilla (Figure-2) and in 9 specimens (19.56%) it was

directly superior to the major papilla (Figure-3) and opens at second part of duodenum (Table-1). The distance between the minor and major papillae varied from 1.3 cm to 4.3 cm, the average being 2.35 cm was noted and recorded in the present study.

Table-1: Position of Minor Duodenal Papilla In Relation to Major Duodenal Papilla

Position of minor papilla	No. of specimens	Incidence (%)
Anterosuperior to MJP	37	80.44
Superior to MJP	09	19.56
Absence of MNP	04	8.0
Total	50	100

Table-2: Comparison of Results of Various Workers on the Distance between Major and Minor Papillae

Sl. No.	Author	Average distance (cm)	Range (cm)
1	Letulle and Nattan [13]	1.8	1 to 3.5
2	Baldwin [14]	2.0	0.9 to 3.5
3	Singh I [7]	2.2	1 to 3.8
4	Present study	2.35	1.3 to 4.3

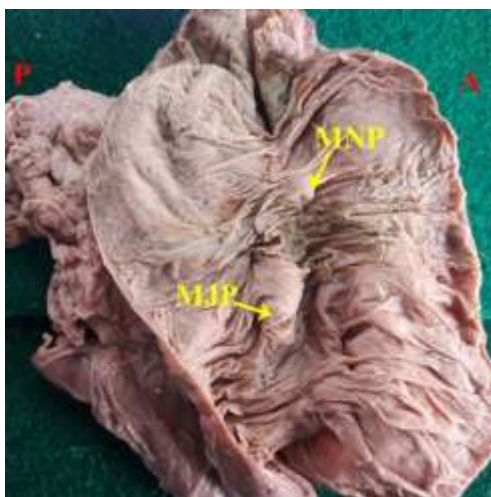


Fig-1: Antero Superior Position of Minor Duodenal Papilla in Relation to Major Duodenal Papilla (MJP: Major duodenal papilla; MNP: minor duodenal papilla)

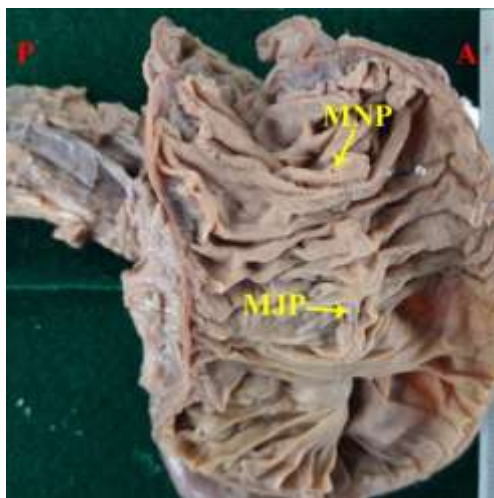


Fig--2: Superior Position of Minor Duodenal Papilla in Relation to Major Duodenal Papilla (MJP: Major duodenal papilla; MNP: minor duodenal papilla)

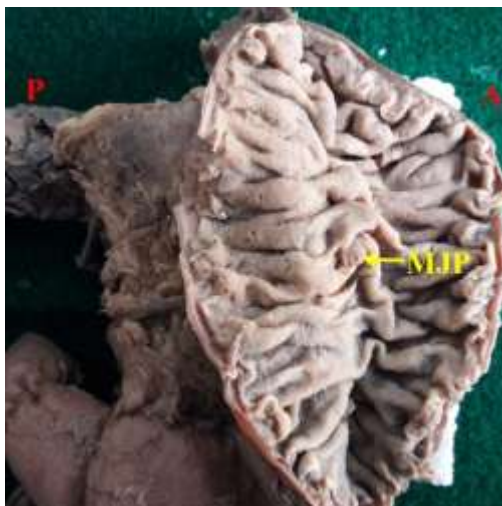


Fig--3: Complete Absence of Minor Duodenal Papilla Whereas Presence of Major Duodenal Papilla (MJP: Major duodenal papilla; MNP: minor duodenal papilla)

DISCUSSION

The position of major duodenal papilla is on the posteromedial wall of the second part of the duodenum to the right of L2 or L3 vertebra. It may lie at a slightly lower level with increased age. The distance from the pylorus varies from 7 cm to 10 cm (range, 1.5-12.0 cm) [5]. Howard observed the distances between the minor and the major papilla was 24.0 mm [6]. The minor duodenal papilla positioned cranio-ventral to major duodenal papilla with an average distance of 2.2 cm between the two papilla [7]. Accessory duct is a smaller duct, presents frequently and opening into duodenum 2 cm proximal to major duodenal papilla [8]. Study on 37 human autopsy specimens of duodenopancreas, which underwent pancreatography, manometrically controlled perfusion and light microscopy the average distances between the minor and the major papilla was 24.0 mm [9, 10]. The minor papilla was situated anterosuperior to major papilla in 46% of specimens and it was directly superior to the major papilla in 9% of specimens. In 45% of specimens minor papilla was absent [11]. In the present study the distance between the major and minor papillae varied from 1.3 cm to 4.3 cm, with an average of 2.35 cm. The minor duodenal papilla was absent in more than 2% of cases. The findings in the present study are higher (Table-2) when compared to previous studies [9, 12].

CONCLUSION

The position of minor duodenal papilla and its variations in relation to major duodenal papilla have more clinical importance in endoscopy while planning surgeries.

ACKNOWLEDGEMENT

The authors are also grateful to authors, editors and publishers of all those articles, journals and books

from where the literature for this article has been reviewed and discussed.

REFERENCES

1. Dardinski, V. J. (1935). The anatomy of the major duodenal papilla of man, with special reference to its musculature. *Journal of anatomy*, 69(Pt 4), 469.
2. Khalid, A., & Slivka, A. (2001). Pancreas divisum. *Current treatment options in gastroenterology*, 4(5), 389-399.
3. Androulakis, J., Colborn, G. L., Skandalakis, P. N., Skandalakis, L. J., & Skandalakis, J. E. (2000). Embryologic and anatomic basis of duodenal surgery. *Surgical Clinics*, 80(1), 171-199.
4. Ohta, T., Nagakawa, T., Kobayashi, H., Kayahara, M., Ueno, K., Konishi, I., & Miyazaki, I. (1991). Histomorphological study on the minor duodenal papilla. *Gastroenterologia Japonica*, 26(3), 356-362.
5. Anson, B. J. (1966). Morris' human anatomy, a complete systematic treatise. 12th ed. New York: McGraw Hill Book Company, 1375-78.
6. Howard, J. M., Jordan, G. L., & Reber, H. A. (1987). *Surgical diseases of the pancreas* (pp. 40-1). Philadelphia: Lea & Febiger.
7. Singh, I. (1956). Observations on the mode of termination of the bile and pancreatic ducts, anatomical factors in pancreatitis. *J Anat Soc India*, 5, 54-60.
8. Kamisawa, T., & Okamoto, A. (2008). Pancreatographic investigation of pancreatic duct system and pancreaticobiliary malformation. *Journal of anatomy*, 212(2), 125-134.
9. Alempijević, T., Stimec, B., Micev, M., Milićević, M., Kovacević, N., & Bulajić, M. (2001). Topographic and structural characteristics of the minor duodenal papilla. *Acta chirurgica Iugoslavica*, 48(3), 93-97.

10. Alempijevic, T., Stimec, B., & Kovacevic, N. (2006). Anatomical features of the minor duodenal papilla in pancreas divisum. *Surgical and Radiologic Anatomy*, 28(6), 620-624.
11. Singh, I. (1962). The terminal part of the accessory pancreatic duct and its musculature. *Journal of anatomy*, 96(Pt 4), 505.
12. Hollinshead, W. H. (1971). *Anatomy for Surgeons: Volume 2: The Thorax, Abdomen, and Pelvis*. Harper & Row.
13. Letulle, M., & Nattan-Larrier, L. (1898). Region vaterienne du duodenum et ampoule de Vater. *Bull. Soc. anat. Paris*, 12, 491-506.
14. Baldwin, J. M. (1911). *The Individual and Society, Or, Psychology and Sociology* (Vol. 3). RG Badger.