

A Study on the Direction of the Nutrient Foramina in Adult Human Forearm Bones in Population of Uttar Pradesh

Rakesh Mishra^{1*}, Sneha Yadav²

¹Department of Human Anatomy, Sardar Patel Post Graduate Institute of Dental and Medical Sciences, Raibareli Rd, Utrathia, Chaudhary Vihar, Lucknow, Uttar Pradesh 226025, India

²Department of Pharmacology, Sardar Patel Post Graduate Institute of Dental and Medical Sciences, Raibareli Rd, Utrathia, Chaudhary Vihar, Lucknow, Uttar Pradesh 226025, India

*Corresponding author: Dr. Rakesh Mishra

| Received: 04.04.2019 | Accepted: 13.04.2019 | Published: 19.04.2019

DOI: [10.21276/sijap.2019.2.4.2](https://doi.org/10.21276/sijap.2019.2.4.2)

Abstract

The present study has been carried out to determine the direction of the nutrient foramina in adult human forearm bones. The nutrient foramina are cavities that conduct the nutrient arteries and the peripheral nerves. The nutrient artery provides the main source of blood supply to the long bones. The present study was done on 114 adult human forearm bones comprising 57 radii and 57 ulnae to observe direction of nutrient foramina and our result shows that 100% of nutrient foramina in radii and ulnae directed away from growing end. We can conclude from the result the nutrient foramen is directed towards the upper end of forearm bones.

Keywords: Nutrient Foramina, Direction, Radius, Ulna.

Copyright © 2019: This is an open-access article distributed under the terms of the Creative Commons Attribution license which permits unrestricted use, distribution, and reproduction in any medium for non-commercial use (NonCommercial, or CC-BY-NC) provided the original author and source are credited.

INTRODUCTION

The nutrient foramina are cavities that conduct the nutrient arteries and the peripheral nerves. The major blood supply for long bones originates from the nutrient arteries, mainly during the growing period and during the early phases of ossification [1-3]. The direction of the nutrient foramen is determined by the growing end of the bone. The growing end of the bone grows at least twice as fast as the non-dominant growing end. This is the reason for the nutrient vessels to move away from the growing end of the bone [4]. Experiments in mammals indicates that at epiphysial plates, rate of growth is initially equal at both ends of bones possessing two epiphyses, but that after birth one grows faster [5]. As popularly stated, nutrient foramen seek the elbow and flee from knee [6]. However only a few study has reported variation in direction of the nutrient foramen in upper limb bones [7]. Variations in the direction of the nutrient foramina have been observed in many tetrapods and there is some similarity in the pattern of nutrient foramina in mammals and birds [8]. The obliquity of the foramina was similar in young bones as in older ones. Similarly, there was no

change in the obliquity when the foramina were in the centre of the bone as compared to when they were nearer the ends [9].

MATERIAL AND METHODS

The study was conducted in the Department of Anatomy, Integral Institute of Medical Science and Research and King George Medical University, Lucknow. The material for present study consisted of 114 adult human forearm bones comprising 57 radii (34 right + 23 left) and 57 ulnae (26 right + 31 left), each irrespective of sex and age. For determination of direction of canal thin metallic wire was passed through the foramen to confirm its direction. When more than one foramen was present, the larger one was considered as Dominant Nutrient Foramen, and nutrient foramina smaller than a size of 26 hypodermic needle were considered as being Secondary Nutrient Foramina. The Foramina at the ends of the bone were ignored.

OBSERVATION AND RESULT

Table-1: Direction of Nutrient Foramina (NF)

Bone	Total No. of NF both dominant and secondary	Towards growing end	Away from growing end
Radius n=57	59	-	59(100%)
Ulna n=57	62	-	62(100%)
Total forearm Bones n= 114	121	-	121 (100%)

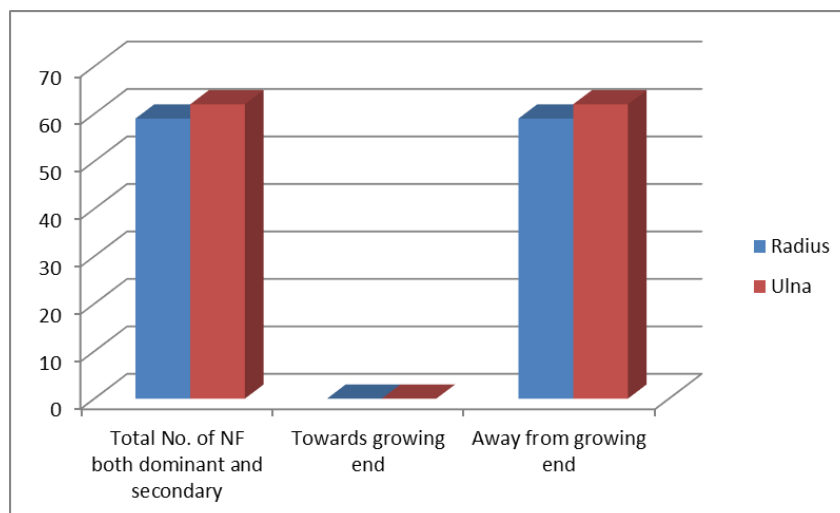


Fig-1: Direction of Nutrient Foramina

Table-1 and Fig-1 shows that 100% of nutrient foramina in radii and ulnae directed away from growing end.

DISCUSSION

In present Study Table-1 shows that the direction of all the nutrient foramina of radii and ulnae were away from growing end (towards the proximal end in radius and ulna). Similar observations were reported by Mysorekar, Solanke *et al.*, and Roul Bichitrananda *et al.*, [9-11].

CONCLUSIONS

We can conclude from the result the nutrient foramen is directed towards the upper end of forearm bones. The anatomical data of nutrient foramen is important for orthopedic surgeons during operations on the forearm bone for bone grafting and traumas.

REFERENCES

- Lewis, O. J. (1956). The blood supply of developing long bones with special reference to the metaphyses. *The Journal of bone and joint surgery. British volume*, 38(4), 928-933.
- Sendemir, E., & Cimen, A. (1991). Nutrient foramina in the shafts of lower limb long bones: situation and number. *Surgical and Radiologic Anatomy*, 13(2), 105-108.
- Gümüşburun, E., Yücel, F., Ozkan, Y., & Akgün, Z. (1994). A study of the nutrient foramina of lower limb long bones. *Surgical and Radiologic Anatomy*, 16(4), 409-412.
- Malukar, O., & Joshi, H. (2011). Diaphysial Nutrient Foramina in Long Bones and Miniature Long Bones. *NJIRM*, 2(2): 23-26.
- Brookes, M. (1963). Cortical vascularization and growth in foetal tubular bones. *Journal of anatomy*, 97(Pt 4), 597-609.
- Patake, S. M., & Mysorekar, V. R. (1977). Diaphysial nutrient foramina in human metacarpals and metatarsals. *Journal of anatomy*, 124(Pt 2), 299-304.
- Kumar, S., Kathiresan, K., Gowda, M. S. T. (2012). Nagalaxmi. Study of Diaphysial Nutrient Foramina in Human Long Bones. *Anatomica Karnataka*, 6(2): 66-70.
- Hughes, H. (1952). The factors determining the direction of the canal for the nutrient artery in the long bones of mammals and birds. *Cells Tissues Organs*, 15(3), 261-280.
- Mysorekar, V. R. (1967). Diaphysial nutrient foramina in human long bones. *Journal of anatomy*, 101(Pt 4), 813-822.
- Solanke, K. S., Bhatnagar, R., & Pokhrel, R. (2014). Number and position of nutrient foramina in humerus, radius and ulna of human dry bones of Indian origin with clinical correlation. *OA Anatomy*, 2(1), 01-4.
- Roul, B., & Goyal, M. (2015). A study of nutrient foramen in long bones of superior extremity in human being. *International Journal of Current Research in Life Sciences*, 4(4), 198-200.