

Study of Morphology of Gantzer Muscle in Forearm and Its Clinical Significance

Ravi Prasanna KH¹, Aditya Krishna Das^{2*}, Anand L Kulkarni³

¹Associate Professor, Department of Anatomy, Mamata Medical College, Rotary Nagar, Khammam, Telangana, India

²Associate Professor, Department of Anatomy, Sree Narayana Institute of Medical Sciences, Chalakka, North Kuthiyathodu (PO), Ernakulam, Kerala, India

³Professor and Head, Department of Anatomy, Sree Narayana Institute of Medical Sciences, Chalakka, North Kuthiyathodu (PO), Ernakulam, Kerala, India

DOI:10.21276/sijap.2019.2.8.1

| Received: 10.08.2019 | Accepted: 19.08.2019 | Published: 26.08.2019

*Corresponding author: Dr. Aditya Krishna Das

Abstract

Kiloh-Nevin syndrome is one of the neuropathies where anterior interosseous nerve gets compressed by accessory head of flexor pollicis longus muscle. This study was designed to look for prevalence, morphology and relation of accessory head to anterior interosseous nerve. The present study was conducted in the Department of Anatomy, Sree Narayana Institute of Medical Sciences, and Ernakulam. 50 upper limb specimens were dissected to expose the accessory heads and its relation to anterior interosseous nerve. The number of accessory heads was noted down and length of the muscle belly was measured with vernier callipers. The accessory heads were present in 18 specimens (36%). 12 specimens with accessory head were observed to get inserted to tendon of flexor pollicis longus and 6 specimens to tendon of flexor digitorum profundus. Double accessory heads were observed in 3 specimens (6%). 3 specimens showed origin of accessory heads from flexor digitorum superficialis. Double accessory heads arising from flexor digitorum superficialis got inserted into flexor pollicis longus and flexor digitorum profundus separately. The accessory heads were related superficially to anterior interosseous nerve in all specimens. The mean length of accessory head on right side was 6.9 cms and 7.4 cms on the left side. The presence of accessory heads to flexor pollicis longus or flexor digitorum profundus acts as a triggering factor for compression of anterior interosseous nerve. The below results will give an additional information to surgeons who approach upper end of radius from anteriorly and even clinicians can plan appropriate management for compression syndromes.

Keywords: Flexor digitorum superficialis, Flexor pollicis longus, Flexor digitorum profundus, Gantzer's muscle, Kiloh-Nevin syndrome.

Copyright © 2019: This is an open-access article distributed under the terms of the Creative Commons Attribution license which permits unrestricted use, distribution, and reproduction in any medium for non-commercial use (NonCommercial, or CC-BY-NC) provided the original author and source are credited.

INTRODUCTION

Forearm muscles play an important role in movements related to day-to-day activities. The flexor digitorum superficialis, flexor digitorum profundus and flexor pollicis longus are muscles which help in flexion of metacarpophalangeal and interphalangeal joints. Flexor digitorum superficialis produces flexion of the middle phalanges of the fingers at the proximal interphalangeal joints and prolonged contraction leads to the flexion of the metacarpophalangeal joints and wrist joint. The flexor digitorum profundus being the bulkiest muscle in the deeper part of forearm arises mainly from the upper three-fourths of the anterior and medial surfaces of the shaft of the ulna, medial surface of the coronoid and olecranon processes and from the adjacent interosseous membrane. The flexor pollicis

longus chiefly arises from the anterior surface of the shaft of the radius intervening between radial tuberosity and to the upper attachment of pronator quadratus muscle and from the adjacent interosseous membrane [1]. In addition to normal origin, flexor digitorum profundus or flexor pollicis longus may have an additional head which will be arising from the medial border of the coronoid process of the ulna or from the medial epicondyle of the humerus, such accessory head was considered as anatomical variation and described by Gantzer in 1813 [2]. Muscular variations in the forearm are clinically significant while conducting operative procedures like tendon transfer or correction of hand deformities which may influence the biomechanics of wrist and hand at the same time. These variants may cause entrapment neuropathy or may simulate soft tissue tumours [3]. The position of

Gantzer muscle in relation to adjacent structures in the forearm is controversial. Mangini [4] and Hemmady *et al.*[5] stated that the accessory head passes posterior to median nerve and anterior to the anterior interosseous nerve, but few quoted in their article that Gantzer muscle was always located posterior to median nerve and anterior to anterior interosseous nerve[6,7,8]. Ballesteros *et al.* [9] reported that the Gantzer muscle was positioned parallel at the ulnar side in relation to the anterior interosseous nerve. The relation of the accessory head (Gantzer muscle) with the anterior interosseous nerve is clinically important where accessory head may compress the nerve to cause AIN syndrome.

MATERIALS / METHODS

The present study was conducted in the Department of Anatomy, Sree Narayana Institute of Medical Sciences, Ernakulam. 50 upper limb specimens (25 right and 25 left) were included in the study irrespective of age and gender. These specimens were fixed in 10% neutral buffered formalin and the dissection of the forearm was done to expose the deep muscles in the forearm. The deep group of flexor muscles were separately observed for accessory heads either from flexor pollicis longus or flexor digitorum profundus. The presence of accessory head was noted down and origin of accessory head was traced to know

whether it's from flexor pollicis longus or flexor digitorum profundus. Its relation with anterior interosseous nerve was observed and the length of the muscle belly was measured with the help of vernier callipers.

RESULTS

The observations of the present study in 50 upper limb specimens are depicted in tables numbered from 1 to 4. Presence of accessory head was demonstrated in 18 out of 50 specimens dissected (36%) which varied in shape from being fusiform to slender (Figure-1). 11 specimens belonged to right side (22%) and 7 specimens to left side (14%). 12 specimens with accessory head were observed to get inserted to tendon of flexor pollicis longus and 6 specimens to tendon of flexor digitorum profundus (Figure-2). Double accessory heads were observed in 3 specimens (6%). 3 specimens showed origin of accessory heads from flexor digitorum superficialis (Figure-3). Double accessory heads arising from flexor digitorum superficialis got inserted into flexor pollicis longus and flexor digitorum profundus separately (Figure-4). The accessory heads were related superficially to anterior interosseous nerve in all 18 specimens. The mean length of accessory head on right side was 6.9 cms with standard deviation of 1.377 and 7.4 cm on the left side with S.D of 1.24.

Table -1: Showing the presence of Gantzer muscle.

Side	Right	Left	Total
Number	25	25	50
Presence of accessory head	11	7	18
Percentage (%)	22	14	36

Table -2: Showing the presence of multiple heads of Gantzer muscle.

Side	Number	Single accessory head	Percentage (%)	Double accessory head	Percentage %
Right	25	9	18	2	4
Left	25	6	12	1	2
Total	50	15	30	3	6

Table -3: Showing the insertion of Gantzer muscle.

Side	Number	Insertion to FPL	Percentage (%)	Insertion to FDP	Percentage (%)
Right	25	8	16	3	6
Left	25	4	8	3	6
Total	50	12	24	6	12

Table -4: Showing the length of Gantzer muscle.

Side	Number of specimens	Mean (cm)	S. D	Range (cm)
Right	25	6.90455	1.377	4.65 – 9.16
Left	25	7.4	1.24	5.64 – 8.78

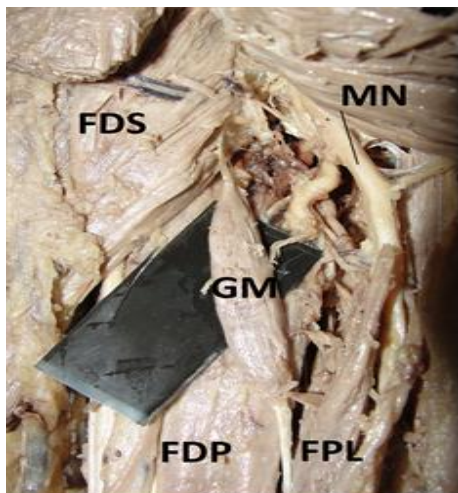


Fig-1: Showing fusiform shaped Gantzer's muscle.

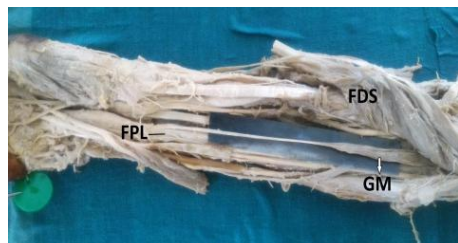

Fig-2: Showing tendon of Gantzer muscle insertion to flexor pollicis longus tendon.

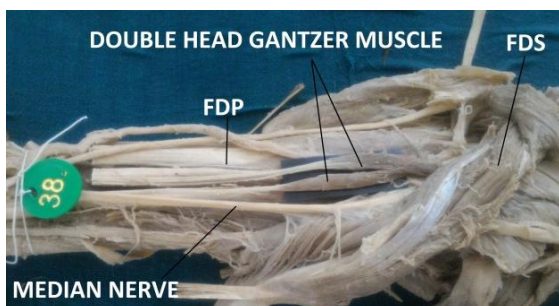


Fig-3: Showing double head Gantzer muscle.

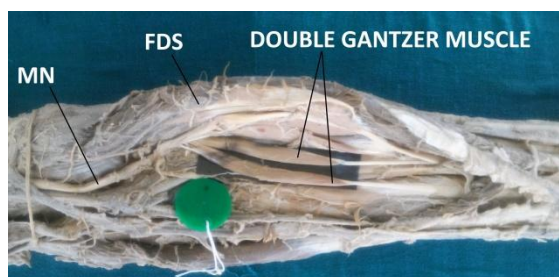


Fig-4: Showing insertion of double head Gantzer muscle to tendon of flexor pollicis longus and flexor digitorum superficialis respectively.

(Abbreviations: MN: Median Nerve, GM: Gantzer Muscle, FDS: Flexor Digitorum Superficialis, FDP: Flexor Digitorum Profundus, FPL: Flexor Pollicis Longus)

DISCUSSION

The common point of origin for Gantzer's muscle is the inferior surface of flexor digitorum superficialis muscle. European caucasians have the lowest incidence of presence of Gantzer's muscle (33%), highest in the blacks (89.3%), asian japanese being intermediate and in indian population (46.03%) it lies between the european caucasians and asian japanese [10]. The presence of accessory heads as observed in the present study may be due to incomplete cleavage of the forearm flexor muscles during development as the deep layer of the flexor muscle mass gives rise to the flexor digitorum superficialis, flexor digitorum profundus and FPL (Jones) [11]. Al Qattan M⁷ and Mahakkanukrauh P *et al.*[12] observed additional head of flexor pollicis longus originating from the medial epicondyle of humerus in 85% and 74.5% of cases respectively but, Oh CS *et al.*[13] observed the same to be merely 10.4% in Asian population. Compression of the anterior interosseous nerve between accessory head of flexor pollicis longus and flexor pollicis longus muscle can be one of the causes for Kiloh-Nevin syndrome (AIN syndrome). Surgeons should be aware of such type of muscular variations in relation to anterior interosseous nerve while approaching proximal part of radius and elbow joint anteriorly [3]. The AIN is the branch of median nerve which innervates the flexor pollicis longus, pronator quadratus and lateral half of flexor digitorum profundus. The physical signs are well known: making the "O" sign is disturbed due to the inability to flex the interphalangeal joint of thumb and the distal interphalangeal joint of index finger (Spinner's sign) [14]. Insertion of Gantzer's muscle is variable as it may get inserted to tendon of flexor pollicis longus or flexor digitorum profundus. The Gantzer's muscle is made of fusiform muscle fibres whereas the flexor pollicis longus is made of unipennate muscle fibres. The function of fusiform muscle fibre is in direct opposition to unipennate fibres. This could in turn lead to loss of precise and skilful movements [15]. Tabib *et al.* reported a case of incomplete anterior interosseous nerve syndrome due to mechanical compression by Gantzer's muscle [16]. Degreef and de smet mentioned in their case report that an older female patient with paralysis of the anterior interosseous nerve was reported; on exploration an accessory muscle slip running from the coronoid process of the ulna towards the flexor pollicis longus (Gantzer's muscle) was found compressing the nerve [17]. The multiple accessory heads like in present study should be kept in mind to avoid complications during any surgical procedures in these regions. Orthopaedic surgeons should be aware about these variations as the accessory heads can cause chronic inflammation, nerve compression syndromes and tenosynovitis. Imaging techniques like computed tomography and magnetic resonance imaging can be used to detect these anatomical variations related to accessory heads. Variations in muscle bellies should

also be kept in mind while approaching the forearm for FDS tendon transfer.

CONCLUSION

The Gantzer muscle if present and gets hypertrophied can compress the nerves in relation to the muscle and cause neuropathies like anterior interosseous nerve syndrome. Proper knowledge of muscular variations is essential not only for anatomists to teach but also for surgeons to conduct tendon transfer and correct any hand deformities. The knowledge regarding the relations of accessory heads to the median nerve or anterior interosseous nerve facilitates determination of the exact cause of entrapment and allows a safe surgery.

Acknowledgements

We wish to thank with due respect and deep gratitude to the staff from the Department of Anatomy, Sree Narayana Institute of Medical Sciences, Ernakulam for suggestions and advice that helped us to a great extent.

Conflict of interest: NIL

REFERENCE

1. Standring, S., Ellis, H., Healy, J., Johnson, D., Williams, A., Collins, P., & Wigley, C. (2005). Gray's anatomy: the anatomical basis of clinical practice. *American Journal of Neuroradiology*, 26(10), 2703.
2. Wood, J. (1868). XVII. Variations in human myology observed during the winter session of 1867-68 at King's College, London. *Proceedings of the royal society of London*, (16), 483-525.
3. Chakravarthi, K. K. (2013). Gantzer's muscle an accessory muscle of forearm—Its Anatomical Variations and Clinical Insight. *International Journal of Chemical and Lifesciences*, 2(7), 1199-1203.
4. Mangini, U. (1960). Flexor pollicis longus muscle: its morphology and clinical significance. *JBJS*, 42(3), 467-559.
5. Hemmady, M. V., Subramanya, A. V., & Mehta, I. M. (1993). Occasional head of flexor pollicis longus muscle: a study of its morphology and clinical significance. *Journal of postgraduate medicine*, 39(1), 14.
6. Dellon, A. L., & Mackinnon, S. E. (1987). Musculoaponeurotic variations along the course of the median nerve in the proximal forearm. *The Journal of Hand Surgery: British & European Volume*, 12(3), 359-363.
7. Al-Qattan, M. M. (1996). Gantzer's muscle: an anatomical study of the accessory head of the flexor pollicis longus muscle. *Journal of Hand Surgery*, 21(2), 269-270.
8. Raviprasanna KH, Dakshayani KR. (2016). Sch J Med Case Rep, 4(7), 562-564.
9. Ballesteros, J., Mendes, A., Lusa, M., & Carrera, A. (2007). Fascículo de Gantzer del músculo flexor pollicis longus. Considerações anatomo clínicas. In *IX Congresso da SECHC, Gijón*.
10. Pai, M. M., Nayak, S. R., Krishnamurthy, A., Vadgaonkar, R., Prabhu, L. V., Ranade, A. V., ... & Rai, R. (2008). The accessory heads of flexor pollicis longus and flexor digitorum profundus: incidence and morphology. *Clinical Anatomy: The Official Journal of the American Association of Clinical Anatomists and the British Association of Clinical Anatomists*, 21(3), 252-258.
11. Jones, M., Abrahams, P. H., Sanudo, J. R., & Campillo, M. (1997). Incidence and morphology of accessory heads of flexor pollicis longus and flexor digitorum profundus (Gantzer's muscles). *The Journal of Anatomy*, 191(3), 451-455.
12. Mahakkanukrauh, P., Surin, P., Ongkana, N., Sethadavit, M., & Vaidhayakarn, P. (2004). Prevalence of accessory head of flexor pollicis longus muscle and its relation to anterior interosseous nerve in Thai population. *Clinical Anatomy: The Official Journal of the American Association of Clinical Anatomists and the British Association of Clinical Anatomists*, 17(8), 631-635.
13. Oh, C. S., Chung, I. H., & Koh, K. S. (2000). Anatomical study of the accessory head of the flexor pollicis longus and the anterior interosseous nerve in Asians. *Clinical Anatomy: The Official Journal of the American Association of Clinical Anatomists and the British Association of Clinical Anatomists*, 13(6), 434-438.
14. Lister G. The Hand: Diagnosis and Indications. Churchill Livingstone, Edinburgh, 3rd Ed, 292-294.
15. Mani, S. S., Vishnumaya, G., & Sij, M. K. (2010). Accessory head of flexor pollicis longus and its significance in anterior interosseous nerve neuropathies and precision handling clinical entity. *International Journal of Anatomical Variations*, 3(1).
16. Tabib, W., Aboufarah, F., & Asselineau, A. (2001). Compression of the anterior interosseous nerve by Gantzer's muscle. *Chirurgie de la main*, 20(3), 241-246.
17. Degreef, I., & De Smet, L. (2004). Anterior interosseous nerve paralysis due to Gantzer's muscle. *Acta orthopaedica belgica*, 70(5), 482-484.