

An Unusual Case of Maxillary Osteomyelitis in a Young Female: A Case Report

Dr. M. Chandra sekhar, MDS^{1*}, Dr. D. Ayesha thabusum, MDS², Dr. M. Charitha, MDS², Dr. G. Chandrasekhar, BDS², Dr. M. Shalini³

¹Prof & HOD, Department of Oral medicine and Radiology, Government Dental College and Hospital, Kadapa, Andhra Pradesh, India

²Department of Oral Medicine and Radiology, Government Dental College and Hospital, Kadapa, Andhra Pradesh, India

³Post Graduate Student, Department of Oral medicine and Radiology, Government Dental College and Hospital, Kadapa, Andhra Pradesh, India

DOI:10.21276/sjm.2019.4.8.20

| Received: 02.08.2019 | Accepted: 24.08.2019 | Published: 30.08.2019

*Corresponding author: Dr. M. Chandra Sekhar

Abstract

Osteomyelitis is an inflammatory disease which is heterogeneous in pathophysiology, clinical presentation and management. It occurs more commonly in the mandible than in the maxilla as the maxilla has a significant collateral blood flow, thin cortical bones which make it less prone to infection. Factors that predispose an individual to osteomyelitis of jaw is virulence of the microorganism, compromised vascular perfusion in the host bone at the local, regional or systemic level, and environment distressing host resistance or defense. Early diagnosis and management is of utmost importance so as to avoid the potentially serious consequences of the disease. We report an unusual case of maxillary osteomyelitis in a 33 year old female patient with poorly controlled diabetes and recurrent maxillary sinusitis.

Keywords: Osteomyelitis, maxilla, immune suppression, diabetes mellitus.

Copyright © 2019: This is an open-access article distributed under the terms of the Creative Commons Attribution license which permits unrestricted use, distribution, and reproduction in any medium for non-commercial use (NonCommercial, or CC-BY-NC) provided the original author and source are credited.

INTRODUCTION

The word “Osteomyelitis” originates from the ancient Greek words osteon (bone) and muelinos (marrow) [1]. Osteomyelitis is the inflammation of the bone which begins as an infection of the medullary cavity with rapid involvement of the haversian systems and extension into the periosteum. It was first described by the French surgeon Edouard Chassaignac in 1852 [2]. Osteomyelitis involving maxilla is rare which is attributed to the fact that maxilla has more extensive collateral blood supply that hinders the bacterial colonization. It has a thin cortical plate and a relatively rare paucity of medullary tissue with confinement of infection in the bone and permits the dissipation of oedema and pus into the soft tissues and Para nasal sinuses.

In the recent years the occurrence of osteomyelitis which was once considered as a dreadful condition has declined drastically due to improved medical knowledge on the pathogenesis of the disease, availability of oral antibiotics and improved dental care [3].

Macbeth in 1952 classified the etiology of osteomyelitis of maxilla into traumatic, rhinogenic and odontogenic [4]. Factors that contribute to osteomyelitis are systemic diseases which compromise the immune

system of an individual such as diabetes mellitus, HIV, malnutrition and use of chemo therapeutic agents [5]. We report an unusual case of maxillary osteomyelitis in a 33 year old female patient with poorly controlled diabetes and recurrent maxillary sinusitis.

CASE REPORT

A 33 year old female patient reported to the Department of Oral Medicine and Radiology with a chief complaint of pain and pus discharge in the left upper posterior tooth region since one month. Pain was mild, dull aching, localized in nature. Patient gives history of blockage of left nostril, difficulty in swallowing and Numbness on the left cheek. Patient was a type 2 diabetic and was on insulin therapy since 7 years.

Her past medical history also revealed that the patient had history of maxillary sinusitis, diabetic keto acidosis and was in diabetic coma for 1 week. Patient had earlier visited a dentist with the same complaint and was put on medication, but the healing was uneventful. There was no significant family history. Patient was poorly built and nourished.

On extra oral examination no gross asymmetry was present. On palpation there was mild tenderness in

the left maxillary sinus region. Left sub mandibular lymph node was palpable which is 1.5 cms in size approximately, soft in consistency, mobile with mild tenderness on palpation.

Local examination revealed an area of denudation with exposed cortical bone and pus discharge in the left posterior palatal region in relation to 23,24,25,26 measuring approximately about 2x2.5 cms in dimension with yellowish discoloration of the bone suggestive of the sequestrum formation (Figure-3). On palpation it was tender with rough surface texture and pus discharge was present on the application of pressure. A provisional diagnosis of chronic suppurative osteomyelitis was given. Patient was then subjected to routine hematological investigations, culture and sensitivity. Intra oral periapical radiograph (Figure-4), maxillary occlusal radiograph (Figure-5), panoramic radiograph (Figure-6), Computed tomograph (Figure 7 & 8) were also taken.

Intra oral peri apical radiograph, maxillary occlusal radiograph, panoramic radiograph did not reveal any significant changes. Computed tomograph showed bony erosion and destruction (Figure-7) haziness in the left anterior and posterior ethmoidal sinus (Figure-8) and confirmed our diagnosis as osteomyelitis of the left maxilla.

Culture and sensitivity report revealed that the patient was resistant to most of the antibiotics that are used in routine clinical practice like pencyllin, co-trimoxazole, methicillin, cloxacillin, linezolid, teichoplanin, piperacillin, tazobactam, vancomycin. However, intermediate response to ofloxacin was reported.

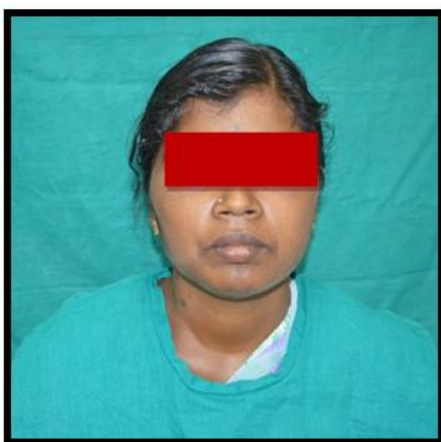

Fig-1: Facial profile of the patient

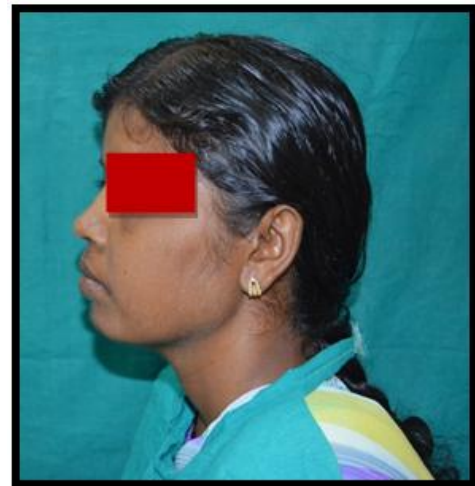

Fig-2: Left lateral side of the patient

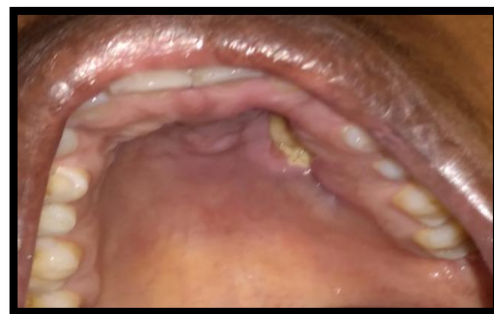

Fig-3: Lesion seen on the left side of the palate

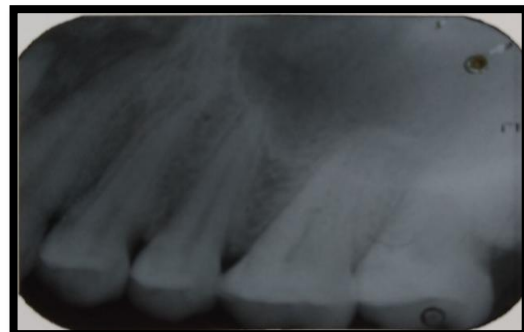

Fig-4: Intra oral peri apical radiograph of the patient

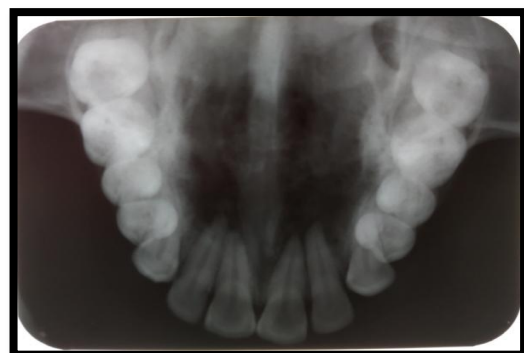


Fig-5: Maxillary occlusal radiograph of the patient

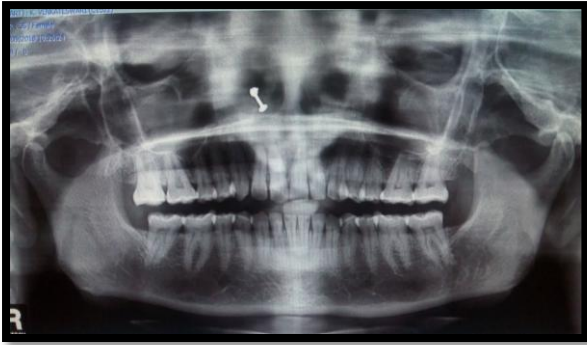

Fig-6: Panoramic radiograph of the patient

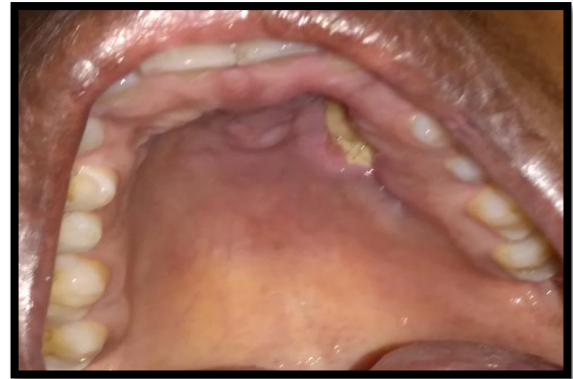

Fig-9: Purulent discharge in the posterior hard palate during the initial visit of the patient

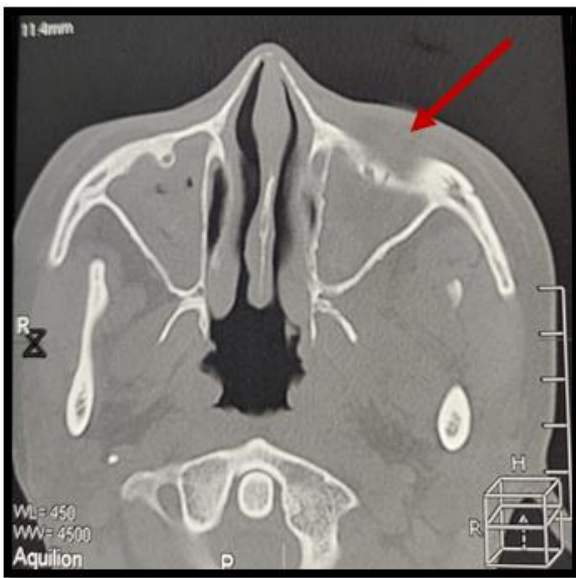


Fig-7: CT shows bony erosion of the left maxilla

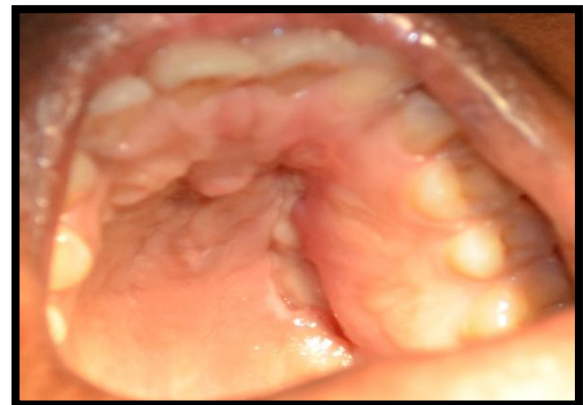

Fig-10: Follow up of the patient 2 weeks after the administration of the medication shows resolving of the purulent discharge

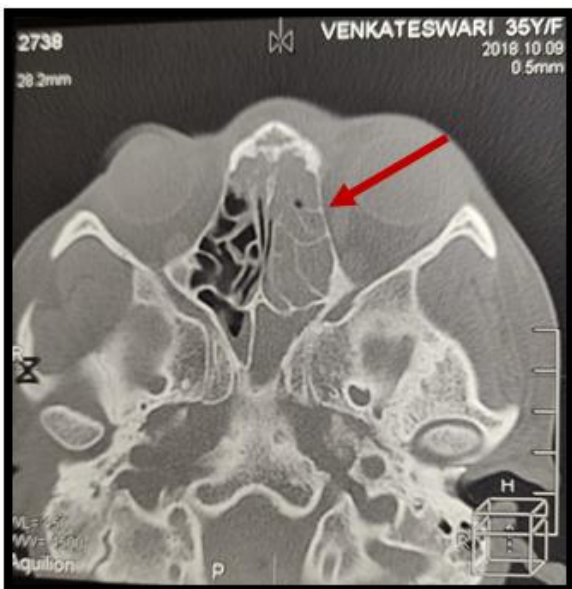

Fig-8: CT shows haziness in the anterior and posterior ethmoidal sinus

DISCUSSION

In this era of advanced antibiotics, osteomyelitis presents as a sub chronic condition and is more commonly associated with debilitated, immunocompromised or medically compromised patients and the varied clinical presentation of the disease pose a diagnostic dilemma. It is important to consider the diagnosis in immunocompromised patients as it remains one of the most difficult to treat diseases. Diminished host defenses both systemic and local can contribute significantly to the emergence and clinical course of the disease.

Clinical features of the disease include fever, swelling, purulent discharge, intra oral or Extra oral fistulae, neuropalsy in the involved area, pathological fractures and trismus [6]. Age does not have a major role in the incidence of osteomyelitis, it is more frequent in adolescents and adults between 40 and 60 years of age [7]. Diagnosis of the disease is made by clinical and radiological criteria along with hematological and histological inputs. Progressive bony destruction and formation of sequestra are the hall marks of the disease [8], both of which were seen in our case.

Osteomyelitis has been associated with multiple systemic diseases including diabetes, auto immune status, malnutrition and acquired immune deficiency syndrome. Factors predisposing to osteomyelitis of the maxilla include dental infections, maxillary sinusitis, trauma and radiation. The two main causes are dental infections and sinusitis. When caused by sinusitis it more frequently involves the frontal bone and rarely the maxilla due to its relatively extensive blood supply and thin bone structure [9].

Diabetes mellitus is a known suppressor of the host response. It causes arteritis of small vessels compromising vascularity leading to reduced tissue perfusion, poor healing area and poor host response against infection, thereby aggravating the osteomyelitis process [5]. In one study by Pervali *et al.*, incidence of maxillary osteomyelitis among poorly controlled diabetes in rural Indian population was 45.1 % [5]. In the same study he inferred that 68% of the cases of maxillary osteomyelitis are related to diabetes mellitus as hyperglycemia weakens the immune system by altering the blood flow distribution to the maxilla. In our case the patient had both recurrent maxillary sinusitis and poor glycemic control both of which could aid in the rapid progression of the disease.

The treatment for maxillary osteomyelitis range from a non invasive approach to a more invasive surgical treatment. A combination of antibiotic treatment with surgery has shown to be effective in treating the condition [10]. Surgical treatment includes the removal of sequestra, debridement, resection and reconstruction. In our case the patient was treated with a prolonged course of ofloxacin (200mg) and ornidazole (500mg) alone making a good recovery (Figure-10).

CONCLUSION

Despite many advances in the diagnosis and treatment of the disease, Osteomyelitis still continues to pose a challenge for both the clinician and patient and remains one of the most difficult to treat infectious disease. When left untreated osteomyelitis may spread to the surrounding structures causing serious complications like brain abscess. Moreover when the disease is caused by immune compromised states such as poor diabetic control where aggressive surgical therapy cannot be performed, the primary focus of the clinician is to reduce the morbidity and alleviate the pain of the patient by administering the required antibiotics as done in this case. This case gives us an insight about the vital importance of early diagnosis and

management of patients with osteomyelitis in debilitated conditions where extensive surgical procedures cannot be performed through careful monitoring of the patient with good course of antibiotics.

REFERENCES

1. Gomes, D., Pereira, M., & Bettencourt, A. F. (2013). Osteomyelitis: an overview of antimicrobial therapy. *Brazilian Journal of Pharmaceutical Sciences*, 49(1), 13-27.
2. Shamanna, K., Rao, R., & Banu, A. (2014). Osteomyelitis of maxilla: A rare case. *J Pub Health Med Res*, 2(1), 50-52.
3. Habib, A., Shivaji, N., & Ashraf, T. (2016). Osteomyelitis: A rare entity. Hindawi publishing corporation; case reports in Otolaryngology.
4. Rege, S. R., Shah, K. L., & Marfatia, P. T. (1970). Osteomyelitis of maxilla with extrusion of teeth in the floor of the nose requiring extraction. *The Journal of Laryngology & Otology*, 84(5), 533-535.
5. Peravali, R. K., Jayade, B., Joshi, A., Shirganvi, M., Rao, C. B., & Gopalkrishnan, K. (2012). Osteomyelitis of maxilla in poorly controlled diabetics in a rural Indian population. *Journal of maxillofacial and oral surgery*, 11(1), 57-66.
6. Baltensperger, M., & Eyrich, G. K. (Editors). (2009). Osteomyelitis of the jaws. Netherlands: Springer.
7. Baltensperger, M., Grätz, K., Bruder, E., Lebeda, R., Makek, M., & Eyrich, G. (2004). Is primary chronic osteomyelitis a uniform disease? Proposal of a classification based on a retrospective analysis of patients treated in the past 30 years. *Journal of Cranio-Maxillofacial Surgery*, 32(1), 43-50.
8. Singh, M., Singh, S., Jain, J., & Singh, K. T. (2010). Chronic suppurative osteomyelitis of maxilla mimicking actinomycotic osteomyelitis: a rare case report. *National journal of maxillofacial surgery*, 1(2), 153.
9. Koorbusch, G. F., Fotos, P., & Goll, K. T. (1992). Retrospective assessment of osteomyelitis: etiology, demographics, risk factors, and management in 35 cases. *Oral surgery, oral medicine, oral pathology*, 74(2), 149-154.
10. Yadav, S., Malik, S., Mittal, H. C., & Puri, P. (2014). Chronic suppurative osteomyelitis of posterior maxilla: A rare presentation. *Journal of oral and maxillofacial pathology: JOMFP*, 18(3), 481.