

Institutional Spectrum of Rare Histological Types of Breast Carcinoma

Swarnalatha P¹, Rajasekhar Reddy S¹, Chaitanya B^{2*}

¹Department of Pathology, ACSR Government Medical College, Nellore, Andhra Pradesh, India

²Department of Pathology, RDT Hospitals, Bathalapalli, Anantapuramu, Andhra Pradesh, India

DOI: 10.36348/SJPM.2019.v04i09.009

| Received: 15.09.2019 | Accepted: 25.09.2019 | Published: 30.09.2019

*Corresponding author: Dr. B. Chaitanya

Abstract

Background: Invasive breast cancer is a heterogeneous disease in its presentation, pathological classification and clinical course. Most tumors are derived from mammary ductal epithelium, principally the terminal duct-lobular unit. However, there are more than a dozen histological variants which are less common but still very well defined by the World Health Organization (WHO) classification. The prime objective of the current study is to document our institutional experience of such rare histological entities with review of literature of the same. **Methods:** The clinicopathological records of resected breast lesions submitted to histopathology department over the period of three years from Jan 2016 to December 2018 were reviewed retrospectively. It was observational, retrospective and descriptive analysis of 4 unusual histological types of breast carcinoma. The most common lesions like infiltrating ductal carcinoma (IDC) and infiltrating lobular carcinoma in malignant category and benign lesions were excluded from the study. **Results:** Among 528 breast malignancies reported in the institute, 48 unusual histological types were recognized, of which 4 are very rare histological types with less than 1% incidence. **Conclusions:** Here in we highlighted the rare varieties of cribriform, squamous, apocrine and signet ring cell carcinoma of breast with relevance to clinical, histopathological and immunohistochemical features. It is with significance to the fact that histological diversity of breast carcinoma has relevant prognostic implications.

Keywords: Breast carcinoma, unusual histological types, clinicopathological features.

Copyright @ 2019: This is an open-access article distributed under the terms of the Creative Commons Attribution license which permits unrestricted use, distribution, and reproduction in any medium for non-commercial use (NonCommercial, or CC-BY-NC) provided the original author and sources are credited.

INTRODUCTION

Breast Cancer (BC) is the most common malignant tumour in women accounting for one – quarter of all cancers in females worldwide. Breast Cancer is characterized by a remarkable degree of morphological and molecular heterogeneity, not only between tumours (inter tumoral heterogeneity) but also among the same tumours (intra tumoral heterogeneity) [1]. Intra tumour heterogeneity which denotes the co existence of subpopulations of cancer cells that differ in their genetic, phenotypic or behavioural characteristics can be attributed to genetic, epigenetic factors and to non hereditary mechanisms [2].

Two potentially complementary theories describing tumour heterogeneity are the Cancer Stem Cell (CSC) hypothesis and the clonal evolution/selection model [3, 4]. In addition, in individual breast cancers, subpopulations of cancer cells may exist across geographical region of a tumour (spatial heterogeneity) or evolve over time between the primary tumour and a subsequent local or distal recurrence (temporal heterogeneity) [5].

Tumour heterogeneity of breast cancer has been the platform for the traditional, mainly histology-driven classification of breast cancer put forth by World Health Organization (WHO). This has been refined and at times replaced by the more recent molecular classification which has been used successfully for the design of individual therapies.

WHO presents a detailed classification of breast cancers based on histology which in turn is associated with different epidemiology, diagnostic issues, clinical course and prognosis. There are “rare/unusual types of breast cancer” that are less common, but still very well defined by the WHO classification [6].

The aim of this research is to present our institutional experience of these less encountered/rarer entities with their histopathological features along with review of their literature.

MATERIALS AND METHODS

The present study is retrospective and was based on the hospital records of women diagnosed with unusual variants of breast cancer. The study was conducted in the department of Pathology, Indian Red Cross Cancer Hospital, Nellore by retrieval of clinicopathological data of patients between January 2016 to December 2018.

As per our institutional protocol, every woman presenting clinically with a breast lump was evaluated by mammography and core needle biopsy. The standard Formalin Fixed Paraffin Embedding (FFPE) technique of tissue processing was followed and slides were stained using Haematoxylin and Eosin dyes. The same routine was also carried out on tissue specimens following surgical excision.

Histopathological diagnosis was confirmed by double blind peer review of H & E slides by two Pathologists. WHO guidelines on histological classification were followed and reporting was done as per College of American Pathologists (CAP) protocol. Immunohistochemistry with relevant markers was performed when deemed necessary and results obtained.

Exclusion Criteria

Histopathologically, benign lesions and commonly diagnosed malignant lesions i.e Invasive Ductal Carcinoma No Special Type and Infiltrating Lobular Carcinoma were excluded in our study.

RESULTS

During a period of 3 years from January 2016 to December 2018, a total of 528 malignant breast lesions were diagnosed, of which 48 were unusual histological types. Out of the remaining 480 cases, 422 (79.9 %) were diagnosed as Invasive duct cell carcinoma of no special type, 28 cases (5.3 %) were invasive lobular and 30 cases (5.68 %) were medullary carcinomas.

In the unusual category of malignant tumours we encountered 6 cases each of invasive papillary and metaplastic carcinoma, 10 cases of intracystic papillary carcinoma, 18 cases of mucinous carcinoma, 2 cases each of pure squamous cell and invasive cribriform carcinoma, 2 cases of stromal sarcomas and one case each of signet ring cell carcinoma and apocrine carcinoma.

Case-1

A 55 year old female presented to surgery outpatient department with a 2.5 x 2 cm lump in the upper medial quadrant of the right breast. She had a previous history of malignancy of left breast for which she received surgery followed by 6 cycles of chemotherapy and radiotherapy. The histological diagnosis was invasive duct cell carcinoma NOS in the left breast. Modified radical mastectomy was done with axillary lymph node dissection for the right breast. Gross examination showed a greyish white firm solid growth with specks of necrosis. On microscopic examination, there was predominant cribriform pattern and focal comedo pattern with central necrosis. These cribriform areas of tumour cells were seen invading into the stroma. The tumour cells displayed malignant nuclear features with focal lymphatic invasion. The tumour was staged as T2N0Mx. On IHC, the cells were strongly positive for ER, PR.

Case-2

A 52 year old female presented with a lump in right breast which grossly measured 2.5 x 2 cms, grey white, solid in consistency and had irregular pushing margins. On histopathological examination, there was invasive cribriform pattern of tumour cells with focal areas showing in situ duct cell carcinoma. Stroma shows desmoplastic response with lymphocytes and multinucleated giant cells. Lymphatic invasion was also noted. The tumour was staged as T2N0Mx. On IHC, the cells were negative for ER, PR. A diagnosis of cribriform carcinoma was rendered in both cases Figures 1 & 2.

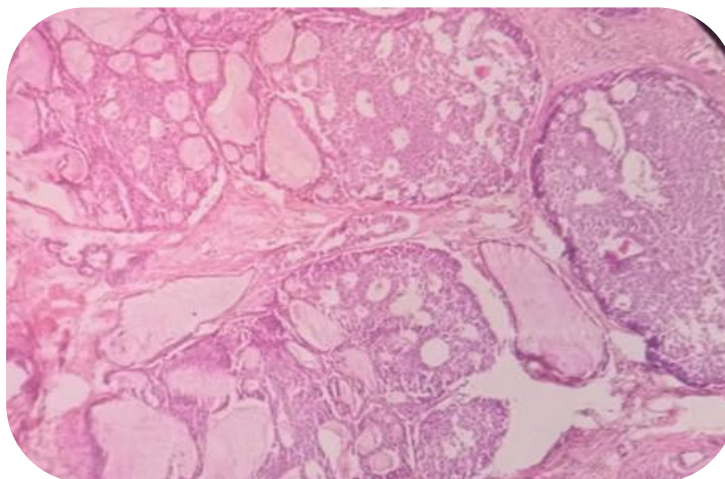


Fig-1: Microphotograph showing cribriform differentiation (H & E, 100x)

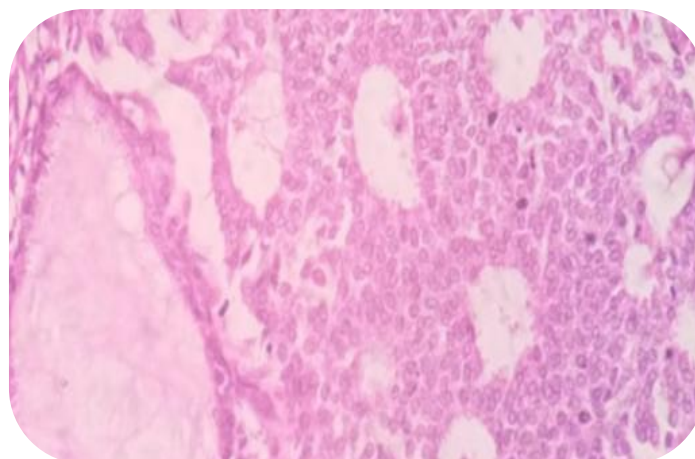


Fig-2: Microphotograph showing sieve like pattern of tumour cells (H & E, 400x)

Case-3

We received mastectomy specimen of a 45 year old female with 6 x 4 x 3 cm lump in upper outer quadrant of left breast. On cut section, the tumour showed partly solid and partly cystic consistency. On histopathological examination, the tumour cells showed high grade nuclear atypia with multiple areas showing signet ring cell morphology. These signet ring cells

showed peripheral nuclei with abundant intracellular mucin. Metastases to axillary lymph nodes was also noted with signet ring cell deposits. Staging was given as T3N3Mx. On IHC, the tumour was negative for ER, PR. Upper GI Endoscopy, CT neck, chest, abdomen were normal, henceforth ruling out metastasis. Figure 3 depicts signet ring carcinoma.

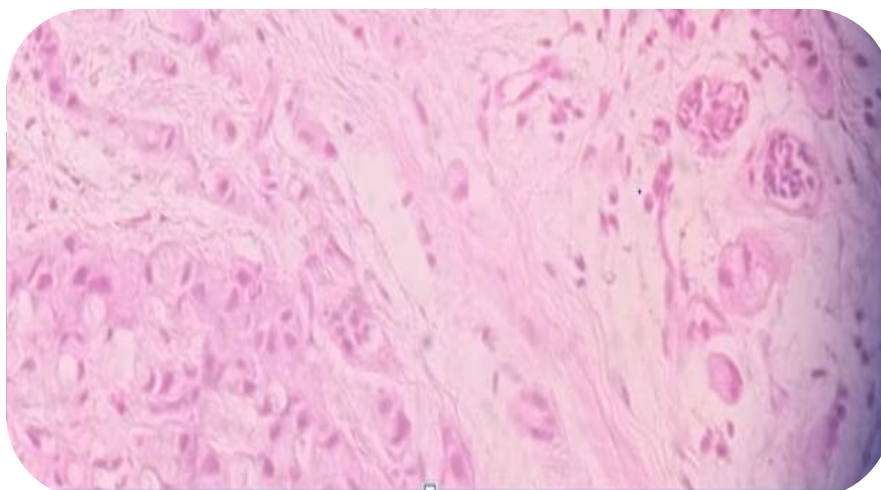


Fig-3: Microphotograph showing signet ring cell morphology (H & E, 400x)

Case 4 & 5

We encountered two female patients of age 48 years and 49 years respectively. The former presented with a 4 x3 cm lump in the upper medial quadrant of right breast. The latter showed a 3.5 x 2.5 lump in the upper outer quadrant of left breast. Both underwent modified radical mastectomy for the same along with axillary node dissection following a core biopsy report of squamous cell carcinoma. On serial slicing, both the cases showed a large grey white growth with normal

overlying skin, nipple and areola. Microscopic examination revealed invasive lesion with nests, sheets and trabeculae of cells with squamoid morphology. Keratin pearl formation was also appreciated. Tumour was staged as T2N0Mx. On IHC, ER and PR were negative, tumour cells showed positivity for pan cytokeratin. One patient additionally got IHC marker positivity for P63 and high molecular weight cytokeratin. Figure-4 depicts squamoid differentiation.

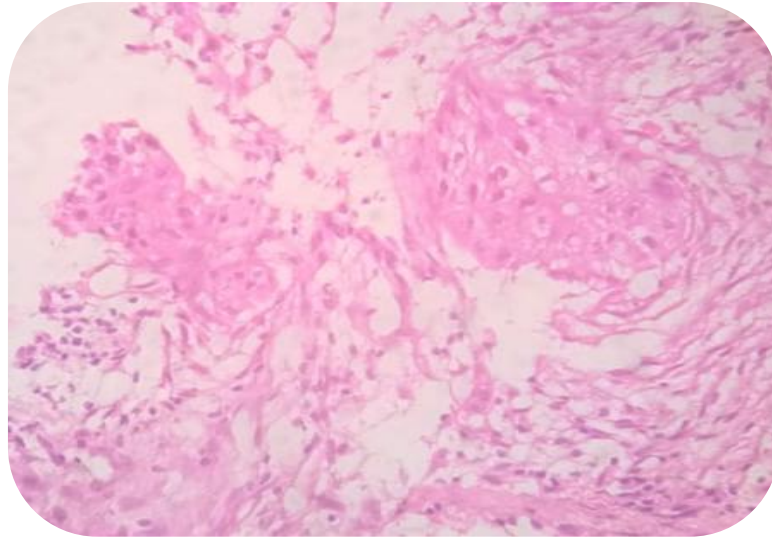


Fig-4: Microphotograph showing squamoid differentiation (H & E, 400x)

Case-6

We received a mastectomy specimen of a 62 year old female diagnosed with poorly differentiated duct cell carcinoma left breast on core biopsy. Cut section showed a 5 x 4 cm grey white solid tumour in the upper quadrants of left breast with grey white deposits in axillary nodes. On histopathological

examination, sheets and glandular pattern of cells with large nuclei, prominent nucleoli and abundant eosinophilic cytoplasm was noted. The tumour was staged as T2N1Mx. The patient also was positive for squamous cell carcinoma in situ cervix. IHC showed the tumour negative for ER and PR. Diagnosis of apocrine carcinoma was rendered Figure-5.

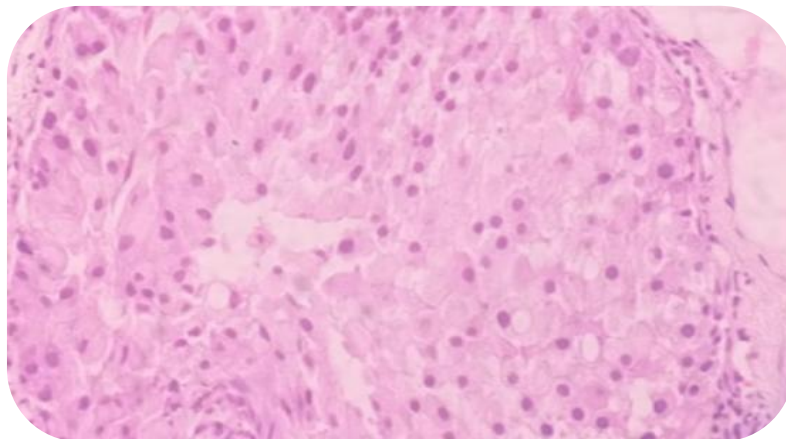


Fig-5: Microphotograph showing apocrine differentiation (H & E, 400x)

Table-1: Summary of Clinical presentation, Core biopsy and Histopathological diagnosis with Immunohistochemistry findings

S. No	Clinical Findings	Core Biopsy Diagnosis	Histopathological Diagnosis	Immunohistochemistry
1	55 years Female with 2.5 x 2 cm lump in upper medial quadrant of right breast	Cribriform Carcinoma	Invasive Cribriform Carcinoma with focal comedo pattern	ER – Positive (60%) PR – Positive (70%)
2	52 year old Female with 2.5 x 2 cm lump in upper outer right breast	Intraductal Carcinoma	Invasive Cribriform Carcinoma with in situ ductal component, Multinucleated giant cells in stroma	ER – Negative (<1%) PR – Negative (<1%)
3	45 year old Female with 6 x 4 x 3 cm lump in upper lateral quadrant of left breast	Signet Ring cell carcinoma	Poorly differentiated duct cell carcinoma Not otherwise specified with 80% area of signet ring cell differentiation	ER – Negative PR - Negative
4	49 year old Female with 3.5 x 2.5 cm lump in upper lateral quadrant of left breast	Squamous cell carcinoma	Squamous cell carcinoma	ER – Negative PR – Negative Pan Cytokeratin – Positive P63 – Positive High Mol. Wt Cytokeratin - Positive
5	48 year old Female with 4 x 3 cm lump in upper medial quadrant of right breast	Squamous cell carcinoma	Squamous cell carcinoma	ER – Negative PR – Negative Cytokeratin - Positive
6	62 year old Female with 4 x 5 cm lump in upper quadrants of left breast	Poorly differentiated carcinoma	Apocrine Carcinoma	ER – Negative PR - Negative

*ER –Estrogen receptor, PR – Progesterone receptor

DISCUSSION

Breast cancer is a heterogeneous disease, comprising multiple entities associated with distinctive histological and biological features, clinical presentations and behaviours and responses to therapy [7].

Most of the research is primarily focused on invasive ductal carcinoma of no special type as it accounts for nearly 50 – 80 % of cases.

Histological special types of breast cancer account for up to 25 % of all invasive breast cancer. Owing to the relative rarity of special types of breast cancer, information about the biology and clinical behaviour of breast cancers conveyed by histological type has not been taken into account.

Herein we made an attempt to present our institutional perspective of few special types.

Cribriform Carcinoma

It is a well differentiated, low grade variant of invasive duct carcinoma. Exhibits a sieve like growth pattern with distinctive holes in between the cancer cells.

Epidemiology: Accounts for up to 3.5 % of the breast cancers [8].

Immunohistochemistry: ER is positive in 100 % and PR in nearly 69 % of cases [9].

Clinical Features: The mean age is 53–58 years. Low frequency of axillary node metastases.

Prognosis: The outcome is remarkably favourable.

Signet Ring Cell Carcinoma

Until 2003, primary signet ring cell carcinoma of the breast was placed under 'mucin producing carcinomas' by WHO. It is a very rare tumour, which shows a significant number of tumour cells resembling gastric carcinoma cells with intracellular mucin displacing the nucleus to the periphery [10].

Epidemiology: Variable from 2–4.5%

Immunophenotype: ER is very often positive. High intensity MUC 1 positivity distinguishes primary signet ring cell carcinoma from metastatic deposits [11].

Clinical features: Deemed to be more aggressive.

Prognosis: Very little is known about the prognostic outcome of primary signet ring cell carcinomas.

Squamous cell carcinoma (SCC)

A breast carcinoma entirely composed of metaplastic squamous cells that may be keratinizing, non keratinizing or spindled; they are neither derived from the overlying skin nor represent metastases from other sites [10].

Epidemiology: Metaplastic carcinomas account for less than 1 % of all invasive mammary carcinomas

Immunophenotype: Nearly all SCC's are negative for both estrogen and progesterone receptors [12]. Positivity for high molecular weight cytokeratins confirms epithelial nature of these cells.

Clinical features: Clinical presentation is not different from that of infiltrating duct cell carcinoma not otherwise specified. Approximately 10–15 % of pure SCC's have axillary node metastases.

Prognosis: Metaplastic carcinomas with squamous differentiation have a 63% 5- year survival.

Apocrine Carcinoma

It is a carcinoma showing cytological and immuno histochemical features of apocrine cells in > 90

% of the tumour cells. Apocrine cells are characterized by abundant cytoplasm that can be densely eosinophilic, granular or vacuolated and by large nuclei with prominent nucleoli.

Structurally it tends to be poorly differentiated.

Epidemiology: Based on light microscopy alone, incidence is only 0.3 – 4 % [13]. Variability is probably the result of inconsistent diagnostic criteria.

Immunophenotype: Usually ER negative and AR (Androgen Receptor) positive.

Clinical features: There is no difference between the clinical, mammographic and gross features among apocrine and non – apocrine lesions.

Prognosis: Prognosis is determined mainly by conventional prognostic factors such as grade, tumour size and nodal status [14].

There exists a drawback of limited case series regarding unusual lesions in breast. We compared a handful of studies with our study [15-20].

Table-2: Comparison of Unusual breast lesions with other researchers

Unusual lesions (%)	Desai M	Malik R & Bharadwaj VK	Kulkarni S et al.,	Dayanand V et al.,	Danda AM et al.,	Dhiraj Nikumbh B et al.,	Present Study
Benign	1.17	-	0.72	-	-	1.12	-
Malignant	-	13.0	15.15	13.9	10.2	5.48	9.09

CONCLUSIONS

To conclude, as for the rare conditions, future research should be directed in collecting and evaluating a larger cohort of patients with the aim to better understand the biological pathways and clinical behavior of these uncommon histological types of breast cancer, in order to improve the clinical management strategies and outcomes.

REFERENCES

- Aleskandarany, M. A., Vandenberghe, M. E., Marchiò, C., Ellis, I. O., Sapino, A., & Rakha, E. A. (2018). Tumour heterogeneity of breast cancer: from morphology to personalised medicine. *Pathobiology*, 85(1-2), 23-34.
- Martelotto, L. G., Ng, C. K., Piscuoglio, S., Weigelt, B., & Reis-Filho, J. S. (2014). Breast cancer intra-tumour heterogeneity. *Breast Cancer Research*, 16(3), 210.
- Meacham, C. E., & Morrison, S. J. (2013). Tumour heterogeneity and cancer cell plasticity. *Nature*, 501(7467), 328-337.
- Greaves, M., & Maley, C. C. (2012). Clonal evolution in cancer. *Nature*, 481(7381), 306-313.
- Ellsworth, R. E., Blackburn, H. L., Shriver, C. D., Soon-Shiong, P., & Ellsworth, D. L. (2017, April). Molecular heterogeneity in breast cancer: state of the science and implications for patient care. In *Seminars in cell & developmental biology*, 64:65-72.
- Yerushalmi, R., Hayes, M. M., & Gelmon, K. A. (2009). Breast carcinoma—rare types: review of the literature. *Annals of oncology*, 20(11), 1763-1770.
- Steponavičienė, L., Gudavičienė, D., & Meškauskas, R. (2012). Rare types of breast carcinoma. *Acta Medica Lituanica*, 19(2): 81-91.
- Page, D. L., Dixon, J. M., Anderson, T. J., Lee, D., & Stewart, H. J. (1983). Invasive cribriform carcinoma of the breast. *Histopathology*, 7(4), 525-536.
- Venable, J. G., Schwartz, A. M., & Silverberg, S. G. (1990). Infiltrating cribriform carcinoma of the breast: a distinctive clinicopathologic entity. *Human pathology*, 21(3), 333-338.
- Ellis, I. O., Schnitt, S. J., Sastre-Garau, X., Bussolati, G., Tavassoli, F. A., Eusebi, V., ... & Cornelisse, C. J. (2003). Invasive breast cancer. Neuroendocrine tumours. *WHO classification of tumours of the breast and the female genital organs. IARC, Lyon*, 32-34.
- Li, X., Feng, Y. F., Wei, W. D., Liu, P., Xie, Z. M., Wang, J., & Xie, X. M. (2013). Signet-ring

- cell carcinoma of the breast: a case report. *World journal of surgical oncology*, 11(1), 183.
12. Behranwala, K. A., Nasiri, N., Abdullah, N., Trott, P. A., & Gui, G. P. (2003). Squamous cell carcinoma of the breast: clinico-pathologic implications and outcome. *European Journal of Surgical Oncology (EJSO)*, 29(4), 386-389.
 13. Frable, W. J., & Kay, S. (1968). Carcinoma of the breast. Histologic and clinical features of apocrine tumors. *Cancer*, 21(4), 756-763.
 14. Abati, A. D., Kimmel, M., & Rosen, P. P. (1990). Apocrine mammary carcinoma: a clinicopathologic study of 72 cases. *American journal of clinical pathology*, 94(4), 371-377.
 15. Desai, M. (2003). Role of obstetrician and gynecologist in management of breast lump. *J Obstet Gynaecol India*, 53, 389-91.
 16. Malik, R., & Bharadwaj, V. K. (2003). Breast lesions in young females--a 20-year study for significance of early recognition. *Indian journal of pathology & microbiology*, 46(4), 559-562.
 17. Kulkarni, S., Vora, I. M., Ghorpade, K. G., & Shrivastava, S. (2009). Histopathological spectrum of breast lesions with reference to uncommon cases. *Journal Obstetrics Gynaecology India*, 59(5); 444-452.
 18. Dayanand, V., Shashidhar, H. B., Sandhya, M., Ashwini, N. S., & Bharathi, M. (2015). Spectrum of Breast Neoplasms in Females: A 10 Years Histopathological Review in a Tertiary Care Hospital. *Int J Sci Stud*, 3(2), 79-84.
 19. Dauda, A. M., Misauno, M. A., & Ojo, E. O. (2011). Histopathological types of breast cancer in Gombe, North Eastern Nigeria: A seven-year review. *African journal of reproductive health*, 15(1):107-9.
 20. Nikumbh, D. B., Kanthikar, S. N., Suryawanshi, K. H., Jagtap, S. V., Dravid, N. V., & Gondane, S. R. (2016). Histopathological Spectrum of Unusual Breast Lesions: A Seven Year Retrospective. *Indian Journal of Pathology and Oncology*, 3(3), 456-462.