

# “Cracked Tooth Syndrome – A Diagnostic Enigma”

Dr. Shazia Salim<sup>1\*</sup>, Dr. Abdul Afsal Latheef<sup>2</sup>, Dr. Feroze Raheem<sup>3</sup>, Dr. Mohamed Irfan<sup>4</sup>, Dr. Sharath Chandrashekhar<sup>5</sup>, Dr. Shahina Salim<sup>6</sup>

<sup>1</sup>Assistant Professor, Department of Conservative & Endodontics Dentistry, Mahe Institute of Dental Sciences and Hospital, Mahe, Kerala India

<sup>2</sup>Post graduate, Department of Conservative & Endodontics Dentistry, Mahe Institute of Dental Sciences and Hospital, Mahe, Kerala India

<sup>3</sup>Registrar Endodontist, Armed Forces Hospital Southern Region, Saudi Arabia

<sup>4</sup>Registrar Endodontist, Armed Forces Hospital Southern Region, Saudi Arabia

<sup>5</sup>Senior Lecturer, Department of Paedodontics & Preventive Dentistry, Mahe Institute of Dental Sciences and Hospital, Mahe Kerala India

<sup>6</sup>General Practitioner, Nanthancode, Thiruvananthapuram Kerala India

DOI: [10.36348/SJODR.2019.v04i10.001](https://doi.org/10.36348/SJODR.2019.v04i10.001)

| Received: 01.10.2019 | Accepted: 07.10.2019 | Published: 16.10.2019

\*Corresponding author: Dr. Shazia Salim

## Abstract

Cracked Tooth Syndrome is a relatively common occurrence in general practice. The term cracked tooth syndrome is misleading as there are a range of symptoms that do not form a distinct and reliable pattern. A lack of awareness of the condition coupled with its varied clinical features can make diagnosis of cracked tooth difficult. Crack may initiate from coronal tooth structure or from within the root and affect healthy, restored or root treated teeth. The location, direction and extent of a crack have a profound effect on the choice of treatment, so clarity is important. With these considerations, many teeth with cracks can be saved! This clinical report describes the diagnostic procedures and management of incompletely fractured and unrestored mandibular molar in a 32 year old male patient. Clinical examination revealed teeth with crack line and associated pulpal inflammation. The tooth was splinted with orthodontic stainless steel band and root canal treatment was carried out. The tooth was then restored. Thus, the key factor in the management of cracked tooth is early diagnosis and immediate splinting so as to limit the propagation of the crack.

**Keywords:** Cracked tooth syndrome, Tooth fracture, Transillumination, Bite test, Mandibular molars, Splinting, Orthodontic band stabilization.

**Copyright @ 2019:** This is an open-access article distributed under the terms of the Creative Commons Attribution license which permits unrestricted use, distribution, and reproduction in any medium for non-commercial use (NonCommercial, or CC-BY-NC) provided the original author and source are credited.

## INTRODUCTION

Cracked Tooth Syndrome is a clinical diagnostic enigma, often manifested like phantom pain. The term cracked tooth syndrome is misleading as the cracked teeth show a variety of symptoms and this unpredictability often makes it a perplexing diagnostic and treatment entity. The term Cracked Tooth Syndrome (CTS) refers to an incomplete fracture of a vital posterior tooth that involves the dentin and occasionally extends into the pulp [1]. It is also defined as a fracture plane of unknown depth and direction passing through tooth structure that, if not already involving, may progress to communicate with the pulp and/or periodontal ligament. The term Cracked Tooth Syndrome was first introduced by Cameron in 1964. He

called it a syndrome in order to explain the wide range of symptoms ranging from occasional discomfort to severe and prolonged pain associated with incomplete crack in the posterior tooth. Other authors had previously described the incomplete fracture as “cuspal fracture odontalgia”, “fissured fractures” and “green stick fracture of the tooth crown” [2]. Several authors have proposed classifications which are generally based on either the type or location of the crack, the direction and extent of the crack, and/or the risk of symptoms and/or pathological processes. The American Association of Endodontists [3] in a document titled “Cracking the Cracked Tooth Code” identified five types of cracks in teeth which are described in Table 1.

**Table-1**

Classification	Origin	Direction	Symptoms	Pulp status	Prognosis
Craze lines	Crown	Variable	None	Vital	Excellent
Fractured cusp	Crown	M-D or F-L	Mild pain on biting or cold	Usually vital	Good
Cracked tooth	Crown and root	M-D often Central	Acute pain on biting or cold	Variable	Questionable
Split tooth	Crown and root	M-D	Marked pain on chewing	Often root filled	Poor
Vertical root fracture	Root	F-L	Often shows no symptom	Mainly root filled	Poor

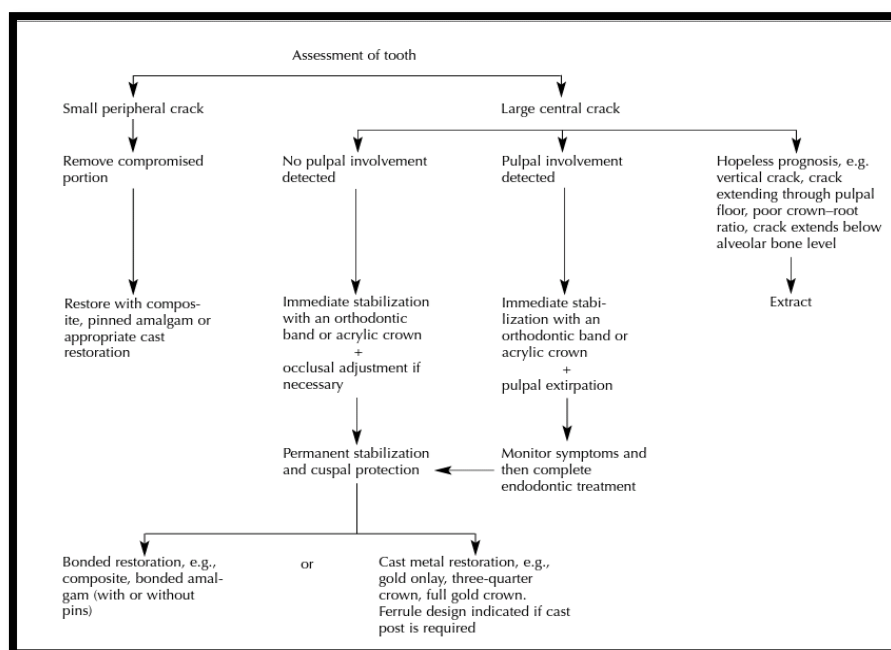
**Table 1[3]**

Both men and women are equally affected. The most commonly affected teeth are mandibular second molar followed by mandibular first molar and maxillary premolars [4]. Patients often present with a protracted history of pain of varying intensity; the origin of which may be difficult to locate. The cracks may occur in both horizontal and vertical directions involving crown and / or root. The etiology is generally related to abnormal occlusal forces and iatrogenic procedures. The signs and symptoms associated with this syndrome are:

1. Acute pain on mastication (pressure or release) of grainy, tough foods and sharp, brief pain with cold.
2. Vary according to position and extend of incomplete fracture.
3. Pain associated with release of pressure called rebound pain is a consistent finding.
4. Sensitivity to sweets is seen occasionally.
5. Pulpal and periodontal symptoms occur when fracture extends to involve pulp.

6. May not be tender to percussion.
7. Radiographs are inconclusive (cracks tend to run in mesiodistal direction).
8. Gives history of pain which has been difficult to diagnose.
9. History of treatments which failed to relieve symptoms.
10. Difficulty identifying affected tooth.

Successful diagnosis of CTS requires awareness of its existence and of the appropriate diagnostic tests. Pain on biting that ceases after the pressure has been withdrawn is a classical sign. Significantly, symptoms can be elicited when pressure is applied to an individual cusp [5]. Bite tests can be performed using various aids such as a toothpick, cotton roll, burlew wheel, wooden stick, or the commercially available Tooth Slooth. Early diagnosis is important to limit the propagation of the crack, subsequent microleakage and involvement of the pulpal and periodontal tissues.

**Tabl- 2**

The treatment requirement of a cracked tooth is dependent on the position and extent of the fracture. An assessment of the stimuli, character and duration of the pain are influential guide for treatment. A decision flow chart indicating the treatment options available has been presented:

TABLE 2[6]

### CASE REPORT

A 32 year old male patient reported to the Department of Conservative Dentistry and Endodontics with complaint of severe pain in lower left posterior region of mouth on chewing food. Pain had started three weeks back which aggravated on chewing food and lasted for more than ten minutes. Spontaneous and diffuse type of pain was felt on the left side of face. Patient was unable to localize the area. Clinical examination revealed deep groove on distal aspect of the occlusal surface on tooth number 36 (Fig1).

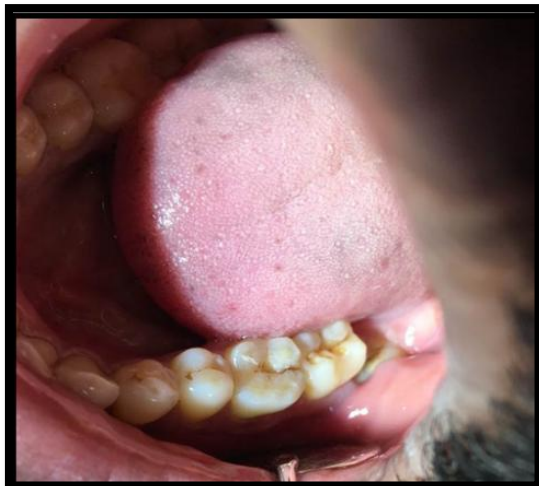

Fig-1: Pre-op photograph

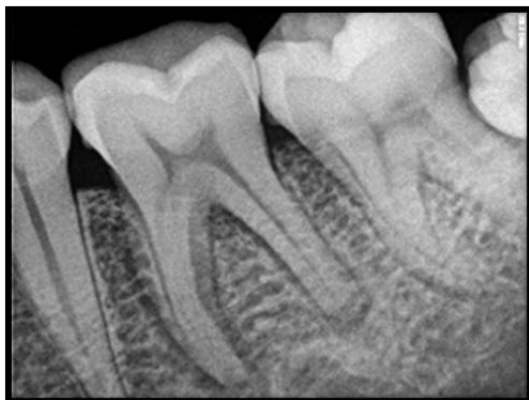

Fig-2: Pre-op radiograph

Tooth number 36 showed widening of PDL space on radiographic examination (Fig 2). Bite test performed using wooden stick elicited pain on releasing bite pressure. Based on the above findings, the

diagnosis was symptomatic apical periodontitis due to cracked tooth. On the first visit, access cavity was prepared on 36 which revealed crack line extending upto pulpal floor (Fig 3).

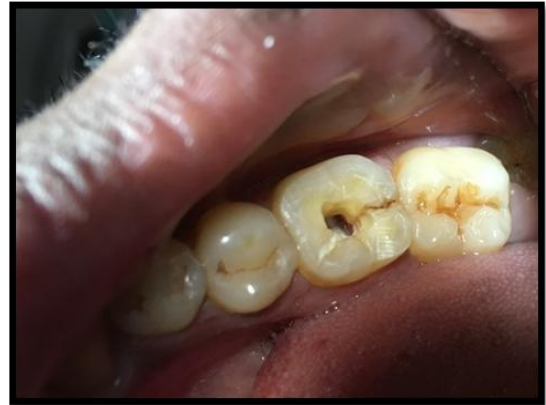

Fig-3: Access cavity preparation

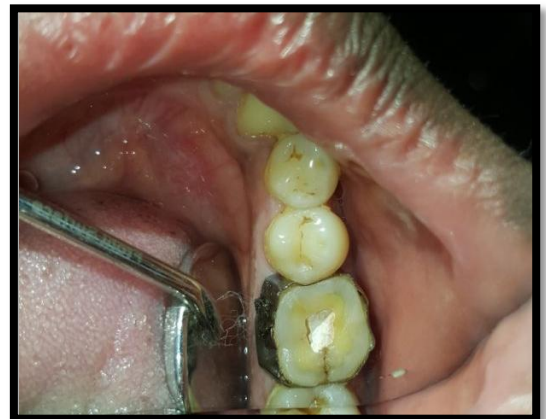

Fig-4: Orthodontic band placement

Orthodontic band was placed to stabilize the tooth and prevent further propagation of crack (Fig 4). This also helps to reinforce tooth during biomechanical preparation. On the second visit, cleaning and shaping was done (Fig 5) and master cone selected (Fig 6).

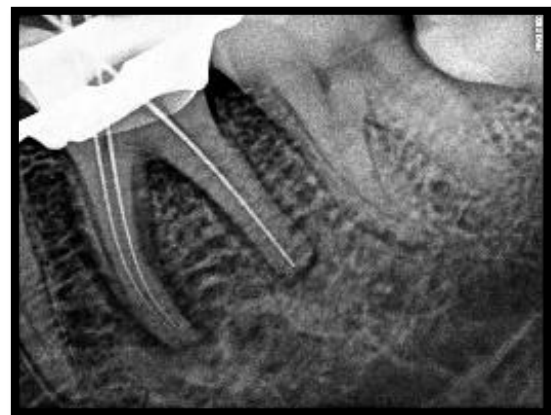
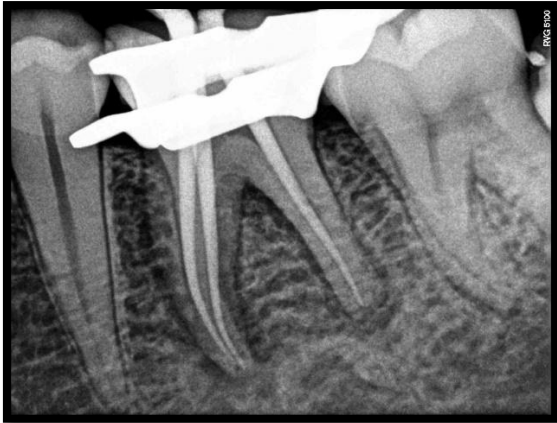

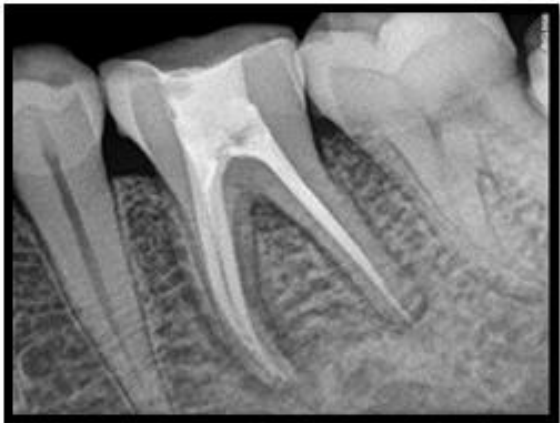Fig-5: Working length determined



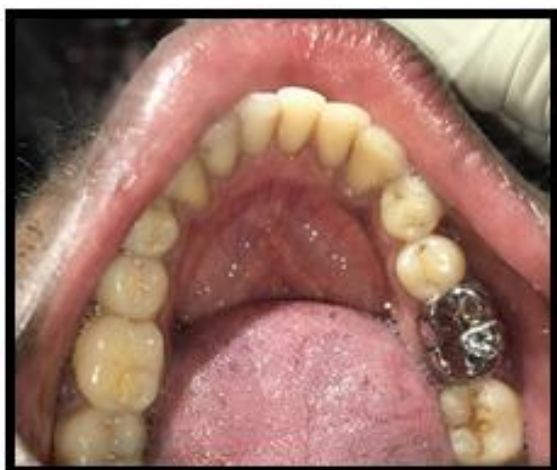

**Fig-6: Master cone selected**

Obturation was completed using gutta percha (Fig 7). Post endodontic restoration was completed using full coverage metal crown (Fig 8). The patient remained asymptomatic during the 3 month follow up visit.



**Fig-7: Post-op radiograph**



**Fig-8: Metal crown cementation**

## DISCUSSION

In a recent clinical investigation of 154 cracked teeth, most of the affected teeth (89.6%) were intact or minimally restored [7]. Therefore the

possibility of an unrestored cracked tooth should be considered regardless of the location of the tooth or the presence and size of a restoration. An unintentional bite on a very hard and small object like a seed is the most common cause for CTS. The crack in an unrestored tooth is frequently hard to see during a common clinical examination. Bite test is the most reliable for reproducing the symptoms of CTS as pain on biting is present in more than 80% of the cases [8]. When a crack is suspected, the steps to confirm the suspicion are:

- i. Dental history
- ii. Subjective examination
- iii. Objective – visual examination
- iv. Tactile examination
- v. Bite tests
- vi. Vitality testing
- vii. Periodontal probing
- viii. Staining
- ix. Transillumination
- x. Wedging forces
- xi. Restoration removal
- xii. Radiographic exam

Immediate treatment of the tooth depends on the size of the involved portion of the tooth. If the tooth portion is relatively small and avoids the pulp (Cameron's "peripherally located crack"), it may be fractured off and the tooth restored in the normal way [9]. If the portion is very large or involves the pulp (Cameron's "centrally located crack"), the tooth should be stabilized immediately with an orthodontic stainless steel band. Stabilization, along with occlusal adjustment, can lead to immediate relief of symptoms [9]. Care should be taken to prevent microleakage along the crack line, as this could result in pulpal necrosis. The tooth should be examined after 2 to 4 weeks and if symptoms of irreversible pulpitis are evident, endodontic treatment should be performed [1]. Ultimately the tooth needs to be restored with protection and permanent stabilization in mind [9]. This can be achieved with an adhesive intracoronal restoration (e.g., bonded amalgam, adhesive composite restorations) or a cast extracoronal restoration (e.g., full-coverage crown, onlay or three-quarter crown with adequate cuspal protection) to bind the remaining tooth components together [10, 11]. As for extracoronal restorations, certain modifications of tooth preparation have been suggested for cracked teeth, such as including additional bracing features in the area of the crack, i.e., extending the preparation in a more apical direction, beveling the cusps of the fractured segment more than usual to minimize damaging forces [12]. Cracks extending subgingivally often require a gingivectomy to expose the margin [13]. Where vertical cracks occur or where the crack extends through the pulpal floor or below the level of the alveolar bone, the prognosis is hopeless and the tooth should be extracted. Multi-rooted teeth can often be successfully treated by resecting the fractured root, either by root amputation or

hemisection. However, the desire to retain part of a root fractured tooth should be carefully considered against extraction and replacement with a denture, bridge or implant. It is worth remembering that it is possible for a crack to progress after placement of an extracoronal metal restoration or crown, when occlusal forces are particularly strong.

In this case, an orthodontic band was cemented to the tooth for stabilization. Root canal therapy was performed and the tooth was bonded with composite restoration. Finally, it was restored with a full coverage crown. However, in cases of cracked teeth, the patient should be fully informed that the prognosis is questionable [14]. A 2006 study evaluated root-filled cracked teeth with a diagnosis of irreversible pulpitis and determined a two year survival rate of 85.5% [15]. It is worth remembering that it is possible for a crack to progress after placement of an extracoronal metal restoration or crown, when occlusal forces are particularly strong. Hence, a cracked tooth is a compromised tooth even with proper treatment. The prevention and early recognition of cracked tooth syndrome is essential for avoiding more injuries and preventing the progression of cracks into the pulp or root.

## CONCLUSION

The possibility of CTS must always be considered when a patient complains of pain or discomfort on chewing or biting. Careful clinical examination and investigation using specialized tests will be conclusive. In the above reported case, the key factors in the management of cracked tooth was its early diagnosis and immediate splinting so as to limit the propagation of the crack. Management of cracked tooth is usually challenging but with the necessary awareness, many teeth with cracks can be saved!

## REFERENCES

1. Ehrmann, E. H., & Tyas, M. J. (1990). Cracked tooth syndrome: diagnosis, treatment and correlation between symptoms and post- extraction findings. *Australian dental journal*, 35(2), 105-112.
2. Kahler, W. (2008). The cracked tooth conundrum: terminology, classification, diagnosis, and management. *American journal of dentistry*, 21(5), 275.
3. Rivera, E. M., & Walton, R. E. (2008). Cracking the cracked tooth code: detection and treatment of various longitudinal tooth fractures. *Am Assoc Endodontists Colleagues for Excellence News Lett*, 2, 1-19.
4. Braly, B. V., & Maxwell, E. H. (1981). Potential for tooth fracture in restorative dentistry. *The Journal of prosthetic dentistry*, 45(4), 411-414.
5. Geurtsen, W. (1992). The cracked-tooth syndrome: clinical features and case reports. *International Journal of Periodontics & Restorative Dentistry*, 12(5).
6. Lynch, C. D., & McConnell, R. J. (2002). The cracked tooth syndrome. *Journal-Canadian Dental Association*, 68(8), 470-475.
7. Roh, B. D., & Lee, Y. E. (2006). Analysis of 154 cases of teeth with cracks. *Dental traumatology*, 22(3), 118-123.
8. Batalha-Silva, S., Gondo, R., Stolf, S. C., & Baratieri, L. N. (2014). Cracked tooth syndrome in an unrestored maxillary premolar: a case report. *Operative dentistry*, 39(5), 460-468.
9. Bales, D.J.(1975). Pain and the cracked tooth. *J Indian Dent Assoc*, 54(5):15-8.
10. Trushkowsky, R. (1991). Restoration of a cracked tooth with a bonded amalgam. *Quintessence International*, 22(5).
11. Bearn, D. R., Sounders, E. M., & Saunders, W. P. (1994). The bonded amalgam restoration--A review of the literature and report of its use in the treatment of four cases of cracked-tooth syndrome. *Quintessence International*, 25(5).
12. CASCIARI, B. J. (1999). Altered preparation design for cracked teeth. *The Journal of the American Dental Association*, 130(4), 571-572.
13. Rosen, H. (1982). Cracked tooth syndrome. *Journal of Prosthetic Dentistry*, 47(1), 36-43.
14. Rivera, E. M., & Walton, R. E. (2008). Cracking the cracked tooth code: detection and treatment of various longitudinal tooth fractures. *Am Assoc Endodontists Colleagues for Excellence News Lett*, 2, 1-19.
15. Tan, L., Chen, N. N., Poon, C. Y., & Wong, H. B. (2006). Survival of root filled cracked teeth in a tertiary institution. *International endodontic journal*, 39(11), 886-889.