

Assessment of Incidence and Risk Factors of Dry Socket Formation after Surgical Removal of Impacted Mandibular Third Molar

Dr. Revati Singh¹, Dr. Rohit Singh², Dr. Supriya Singh^{3*}, Dr. Amit Kumar⁴, Dr. Shahi Kunar⁵, Dr. Jazib Nazeer⁶

¹MDS, Sen Resident, Department of Oral Surgery, Patna Medical College and Hospital, Patna, Bihar, India

²MDS, Lecturer, Department of Prosthodontics, Crown Bridge and Implantology, Patna Dental College And Hospital, Patna, Bihar, India

³MDS, Lecturer, Department of Oral Medicine and Radiology, Consultant, Patna, Bihar, India

⁴MDS, Scturer, Oral and Maillofacial Surgery Patna Dental College and Hospital, Patna, Bihar, India

⁵MDS, Consultant, Department of Orthodontics, Patna, Bihar, India

⁶MDS, Lecturer, Department of Oral Pathology, Patna Dental College and Hospital, Patna, Bihar, India

DOI: [10.36348/SJODR.2019.v04i12.006](https://doi.org/10.36348/SJODR.2019.v04i12.006)

| Received: 11.11.2019 | Accepted: 25.11.2019 | Published: 02.12.2019

*Corresponding author: Dr. Supriya Singh

Abstract

Background: The most frequent complication which follows the removal of impacted mandibular third molars is ‘dry socket’ or Alveolar Osteitis (AO). The present study aimed to evaluate the incidence, risk factors (age, sex, infection) contributing to the development of dry socket and clinical feature following surgical removal of impacted mandibular third. **Material & Methods:** The present study was conducted in 86 adult patients requiring surgical extraction of impacted mandibular third molar. The surgery was performed in a standardized technique. Patients were recalled regularly and symptoms and signs of dry socket was noted if developed. Patients were reviewed at 3rd and 7th day of surgery. **Results:** Out of 86 patients, 46 were males and 40 were females. Out of 46 males, 5 and out of 40 females, 4 developed dry socket. Age group 18-30 had 2 dry socket, 30-50 had 2 and >50 years had 5 cases of dry socket. The difference among both genders was significant in age >50 years (P< 0.05). The incidence of DS was in 7 patients suffering from systemic diseases and 2 medically fit patients developed dry socket. Postoperative symptoms such as pain, empty socket, bare bone and halitosis on 3rd and 7th day. There was significant reduction in symptoms on 7th day. **Conclusion:** Dry socket is multifactorial in nature. Authors found that higher number of dry socket was in age group >50 years, in males and in patients with systemic diseases. **Need of the Study:** Assessment of risk factors may be useful in preventing complications arising from mandibular third molar extraction.

Keywords: Alveolar Osteitis, Dry socket, Systemic disease.

Copyright © 2019: This is an open-access article distributed under the terms of the Creative Commons Attribution license which permits unrestricted use, distribution, and reproduction in any medium for non-commercial use (NonCommercial, or CC-BY-NC) provided the original author and source are credited.

INTRODUCTION

Among impacted teeth, mandibular third molar is most commonly involved tooth. There is different type of impaction such as mesio angular, disto-angular, vertical and horizontal. Disimpaction is the surgical removal of mandibular third molars and is considered frequently performed procedures [1].

‘Dry socket (DS)’ or Alveolar Osteitis (AO) is routinely encountered complication following the removal of impacted mandibular third molars.¹ Studies have revealed that there is 10 times increase prevalence of occurrence of dry socket related to mandibular impacted third molar removal as compared to any other impacted tooth procedure. It has been observed that due to increased risk of bacterial contamination and increased trauma favour dry socket with disimpaction of mandibular third molar [2].

When we look for reasons for Alveolar Osteitis (AO), tobacco use, age, radiographic difficulty of extraction, sex and infection of alveolus etc. considered to be most important. However, etiology of dry socket is multifactorial. It starts appearing 2-3 days following disimpaction. Crawford in 1896 was the first one who first described dry socket [3]. The clinical feature of dry socket presents as necrosis and disintegration of the originally occurred blood clot, alveolus is empty, with completely or partially denuded, very sensitive bone surfaces, covered by a greyish yellow layer of detritus and necrotic tissues and severe throbbing pain from the extraction socket that radiates towards different adjacent parts or organs [4]. This study was conducted to assess occurrence and risk factors of dry socket in adult population.

MATERIAL & METHODS

This study was conducted in the department of Oral & Maxillofacial Surgery. It comprised of 86 patients of both genders who reported with the complaint of mandibular third molar impaction. Inclusion criteria comprised of patients with age >18 years, patients with at least one impacted mandibular 3rd molar and systemic healthy patients were included in the study. Patients with serious systemic illness such as surgery and pregnant or lactating females were excluded from the study.

Patient’s information such as name, age, gender etc. was recorded in case history performa. The surgery was performed in a standardized technique. Local anesthesia lignocaine 2% with 1:200,000 adrenaline was for the block. Full mucoperiosteal flap was reflected and tooth was elevated from its socket the tooth and its roots were examined properly to ensure that the whole tooth was removed. The wound was gently irrigated with sterile saline solution. Wound was closed with 3-0 silk suture. Patients were prescribed capsule 500 mg amoxicillin, 50 mg Diclofenac sodium and 500 mg Paracetamol for 5 days. Patients were advised to maintain proper oral hygiene and mouthwash chlorhexidine 0.2% was administered twice daily. Patients were recalled regularly and symptoms and signs of dry socket was noted if developed. Patients were reviewed at 3rd and 7th day of surgery.

Statistical Analysis

Data was entered in MS excel sheet. SPSS version 21.0 was used for the analysis. Mann Whitney test was applied for the study. P value less than 0.05 was considered significant.

RESULTS

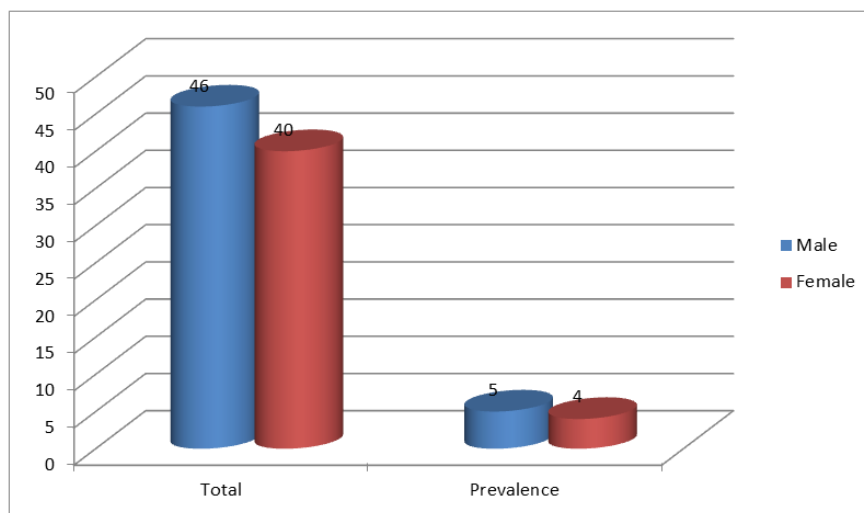
Table-1 shows that out of 86 patients, 46 were males and 40 were females. Table-2, Graph-1 shows that out of 46 males, 5 and out of 40 females, 4 developed dry socket. Table-3, Graph-2 shows that age group 18-30 had 2 dry socket, 30-50 had 2 and >50 years had 5 cases of dry socket. The difference among both genders was significant in age >50 years (P< 0.05). Table-4, Graph-3 shows that incidence of DS was in 7 patients suffering from systemic diseases and 2 medically fit patients developed dry socket. Table-5, Graph-4 shows postoperative symptoms such as pain, empty socket, bare bone and halitosis on 3rd and 7th day. There was significant reduction in symptoms on 7th day.

Table-1: Distribution of patients

| Total- 86 | | |
|-----------|-------|---------|
| Gender | Males | Females |
| Number | 46 | 40 |

Table-2: Prevalence of dry socket

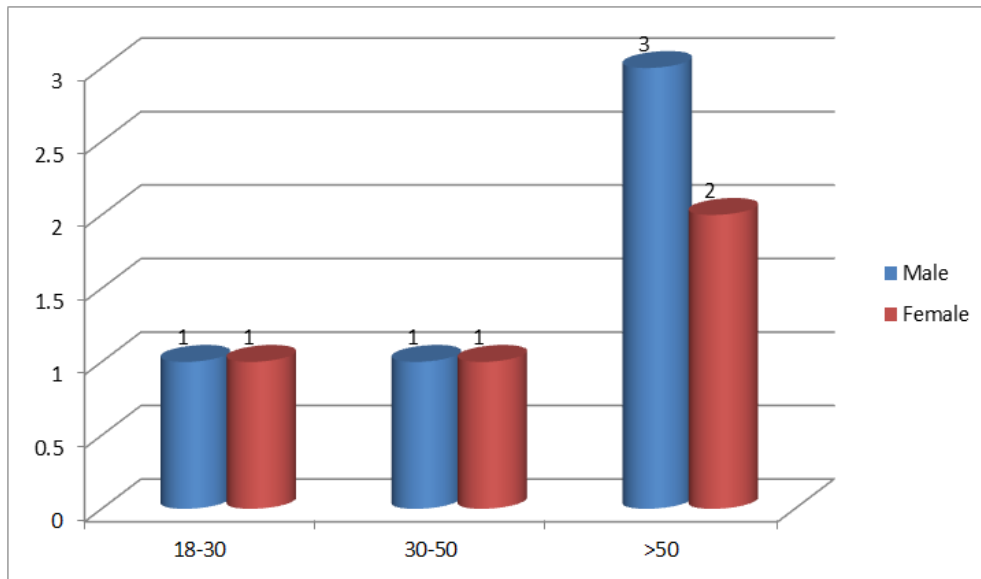
| Parameters | Male | Female |
|------------|------|--------|
| Total | 46 | 40 |
| Prevalence | 5 | 4 |



Graph-1: Prevalence of dry socket

Table-3: Age groups and incidence of dry socket

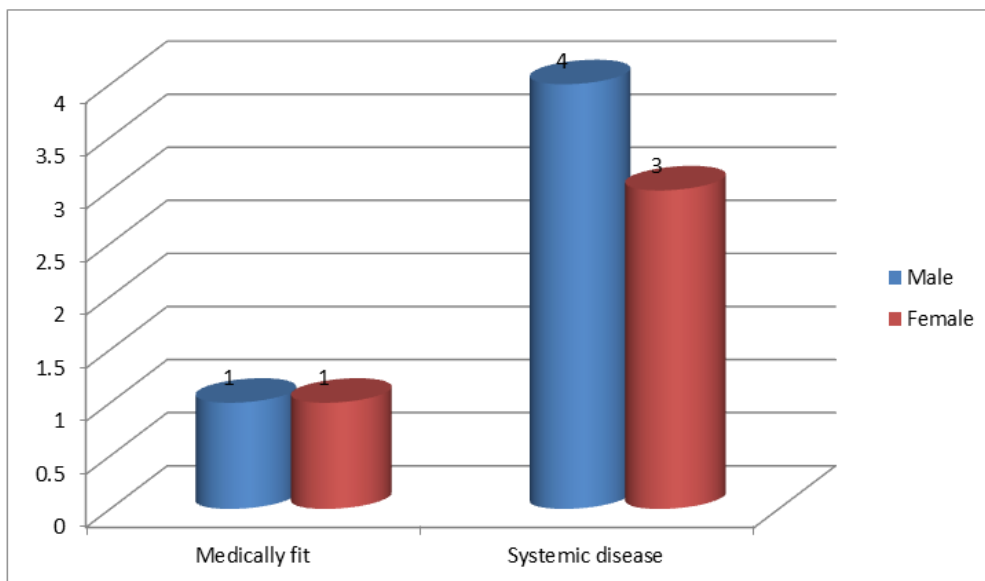
| Age group (Years) | Male | Female | P value |
|-------------------|------|--------|---------|
| 18-30 | 1 | 1 | 1 |
| 30-50 | 1 | 1 | 1 |
| >50 | 3 | 2 | 0.05 |



Graph-2: Age groups and incidence of dry socket

Table-4: Medical status and incidence of DS

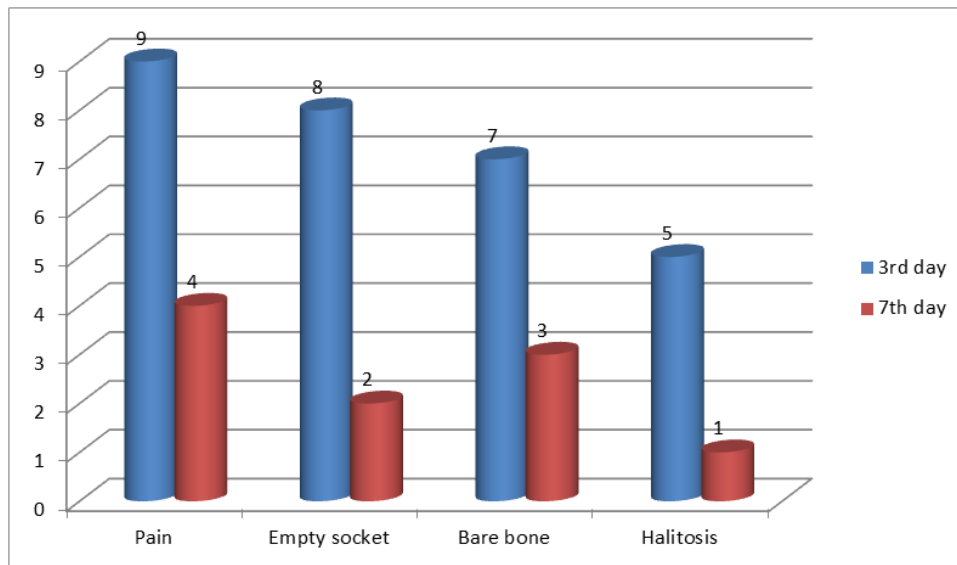
| Systemic status | Male | Female | P value |
|------------------|------|--------|---------|
| Medically fit | 1 | 1 | 0.01 |
| Systemic disease | 4 | 3 | |



Graph-3: Medical status and incidence of DS

Table-5: Post-operative symptoms on 3rd & 7th postoperative day

| Post-operative complications | 3 rd day | 7 th day | P value |
|------------------------------|---------------------|---------------------|---------|
| Pain | 9 | 4 | 0.01 |
| Empty socket | 8 | 2 | 0.001 |
| Bare bone | 7 | 3 | 0.02 |
| Halitosis | 5 | 1 | 0.01 |



Graph-4: Post-operative symptoms on 3rd & 7th postoperative day

DISCUSSION

Dry socket or alveolar osteitis is frequent complication seen following surgical removal of impacted mandibular third molars. It is the leading cause for which patient visit to the oral surgeon. The exact pathogenesis is unknown but it is thought to be due to high fibrinolytic activity in and around the alveolus [5].

Due to excessive trauma or infection or both, there may be bone marrow inflammation in the alveolus. Later on there is liberation of stable tissue activator which convert plasminogen into plasmin [6]. It release kinins by two mechanisms, in first mechanism, plasmin directly gets converted into kinins and in second mechanism they cause clot dissolution that is responsible for release of kinins, which induces violent pain in this disease. Patient experience pain 2-3 days, foul taste and lymphadenitis. In the clinical examination, there exists no blood clot in the extraction socket and the alveolar bone is exposed. It has been found higher fibrinolysis and increased plasmin activity along with higher amount of tissue activators in extraction socket of cases with DS. This study was conducted to assess occurrence and risk factors of dry socket in adult population.

In present study, out of 86 patients, 46 were males and 40 were females. Out of 46 males, 5 and out of 40 females, 4 developed dry socket. Purohit *et al.*, [7] included a total of 293 third molar surgical extractions between age group of 18 to 45 years. Out of 178 extractions of third molar, 12 (4.09%) patients had dry socket. There was higher incidence of dry socket among smokers (08 patients) as compared to non- smokers (04 patients). Maximum cases of dry sockets were seen in mandibular third molar extraction as compared to the maxillary third molar. There was no gender prevalence. The high incidence of dry socket was observed in

patients of smokers after mandibular third molar surgical removal.

We found that age group 18-30 had 2 dry socket, 30-50 had 2 and >50 years had 5 cases of dry socket. Incidence of DS was in 7 patients suffering from systemic diseases and 2 medically fit patients developed dry socket.

Rubio *et al.*, [8] in their study found that 0.2% bioadhesive chlorhexidine gel applied in the alveolus after third molar extraction reduced the incidence of dry socket by 22% compared to placebo with differences that were not statistically significant. There was statistically significant difference in smoking and the use of oral contraceptives. Female patients and the difficulty of the surgery were associated with a higher incidence of AO with 0.2% bioadhesive chlorhexidine gel did not produce any of the side effects related to chlorhexidine rinses.

We found that postoperative symptoms such as pain, empty socket, bare bone and halitosis showed significant reduction on 7th day. It has been found that oral contraceptives increase the circulatory concentration of estrogen. On the other hand, estrogen enhances fibrinolytic activity of human body.

Requena *et al.*, [9] included 40 patients who required extraction of third molars impacted and were divided into experimental group (chlorhexidine gel 0.12%) and control group (placebo gel). Performed the extraction was administered 1 mL of chlorhexidine gel or 1 mL of placebo gel within the socket. The removal of suture was on the fifth postoperative day in which the presence or absence of dry socket was evaluated. There was no relationship between the appearance of dry socket after application of chlorhexidine gel or placebo gel (X² test, $p = 0.311$). However, significant

differences (U Mann-Whitney test, $p = 0.036$) in the pain presented on the fifth postoperative day were evident (VAS).

Pre-existing infection causes inflammation of bone marrow that was responsible for the release of stable tissue activator factor which finally causes alveolar osteitis. The advantage of the present study is that it provided prevalence of dry socket among adult population. It evaluated various risk factors such as age, gender and systemic disease and occurrence of dry socket. The limitation of the study is small sample size. The role of zinc oxide eugenol paste was not evaluated. In present study effect of smoking on occurrence of dry socket was not assessed.

CONCLUSION

Dry socket is multifactorial in nature. Authors found that higher number of dry socket was in age group >50 years, in males and in patients with systemic diseases.

REFERENCES

1. Mamoun, J. (2018). Dry socket etiology, diagnosis, and clinical treatment techniques. *Journal of the Korean Association of Oral and Maxillofacial Surgeons*, 44(2), 52-58.
2. Deliverska, E. G., & Petkova, M. (2016). Complications after extraction of impacted third molars-literature review. *Journal of IMAB—Annual Proceeding Scientific Papers*, 22(3), 1202-1211.
3. Haraji, A., & Rakhshan, V. (2015). Chlorhexidine gel and less difficult surgeries might reduce post-operative pain, controlling for dry socket, infection and analgesic consumption: a split-mouth controlled randomised clinical trial. *Journal of oral rehabilitation*, 42(3), 209-219.
4. Inamdar, M. N., Chauhan, R., Mapare, S. A., Goswami, R. P., Goswami, Y., & Khadri, S. F. (2015). Prevention of dry socket using chlorhexidine gel and ornidazole gel in impacted mandibular third molar: a comparative randomized prospective study on 30 patients. *Journal of International Oral Health*, 7(11), 41.
5. Teshome, A. (2017). The efficacy of chlorhexidine gel in the prevention of alveolar osteitis after mandibular third molar extraction: a systematic review and meta-analysis. *BMC oral health*, 17(1), 82.
6. Freudenthal, N., Sternudd, M., Jansson, L., & Wannfors, K. (2015). A double-blind randomized study evaluating the effect of intra-alveolar chlorhexidine gel on alveolar osteitis after removal of mandibular third molars. *Journal of Oral and Maxillofacial Surgery*, 73(4), 600-605.
7. Purohit, J. N. (2016). Incidence of dry socket after surgical removal of the third molar: a retrospective study. *Sch J Dent Sci*, 3(10), 287-9.
8. Rubio-Palau, J., Garcia-Linares, J., Hueto-Madrid, J. A., González-Lagunas, J., Raspall-Martin, G., & Mareque-Bueno, J. (2015). Effect of intra-alveolar placement of 0.2% chlorhexidine bioadhesive gel on the incidence of alveolar osteitis following the extraction of mandibular third molars. A double-blind randomized clinical trial. *Medicina oral, patología oral y cirugía bucal*, 20(1):117-122.
9. Requena-Calla, S., & Funes-Rumiche, I. (2016). Effectiveness of intra-alveolar chlorhexidine gel in reducing dry socket following surgical extraction of lower third molars. A pilot study. *Journal of clinical and experimental dentistry*, 8(2), e160.