

## Ectopic Pancreatic Tissue Associated with Choledochal Cyst Type IV A in a 21 Years Old Female: Case Report

Dr. Sushil Kumar Shukla<sup>1\*</sup>, Dr. Meena Harsh<sup>2</sup>, Dr. Babar Rehmani<sup>3</sup>, Dr. Manveer Kaur Raina<sup>4</sup>

<sup>1</sup>Senior Resident, Department of Pathology, Himalayan Institute of Medical Sciences, Swami Rama Himalayan University, Dehradun, Uttarakhand, India

<sup>2</sup>Professor, Department of Pathology, Himalayan Institute of Medical Sciences, Swami Rama Himalayan University, Dehradun, Uttarakhand, India

<sup>3</sup>Professor, Department of Surgery, Himalayan Institute of Medical Sciences, Swami Rama Himalayan University, Dehradun, Uttarakhand, India

<sup>4</sup>Resident, Department of Pathology, Himalayan Institute of Medical Sciences, Swami Rama Himalayan University, Dehradun, Uttarakhand, India

\*Corresponding author: Dr. Sushil Kumar Shukla

| Received: 16.01.2019 | Accepted: 26.01.2019 | Published: 30.01.2019

DOI: [10.21276/sjpm.2019.4.1.8](https://doi.org/10.21276/sjpm.2019.4.1.8)

### Abstract

Ectopic pancreas is an abnormal condition of embryological origin. The relationship of ectopic pancreatic tissue associated with choledochal cyst is extremely rare condition. The most commonly reported cases of ectopic pancreatic tissue are located in the upper GI (gastrointestinal) tract with most frequent site is stomach, followed by the duodenum and the jejunum. The clinical implication of the presence of ectopic pancreas in the choledochal cyst is remain unclear but it's predicted risk for developing further complications, especially pancreatic malignancy should always be considered. Ectopic pancreatic tissue can be diagnosed at all ages, males are frequently associated but a higher incidence of ectopic pancreas in the gallbladder is found in females and most incidence lies between the thirty to sixty years of life. The purpose of the present case is to present the clinical, and histopathological features of ectopic pancreatic tissue associated with choledochal cyst of 21 years old female. However, the basic concept of occurrence of ectopic pancreatic tissue is contentious. To conclude, the ectopic pancreatic tissue associated with choledochal cyst may be an evidence of its embryological association and it's greater risk for development of further complications, especially development of pancreatic malignancy. The present case should be considered for long term follow up as only doing cystectomy will not provide full protection against the development of pancreatic malignancy.

**Keywords:** Ectopic Pancreas, Choledochal Cyst.

**Copyright @ 2019:** This is an open-access article distributed under the terms of the Creative Commons Attribution license which permits unrestricted use, distribution, and reproduction in any medium for non-commercial use (NonCommercial, or CC-BY-NC) provided the original author and sources are credited.

### INTRODUCTION

Ectopic pancreas is an abnormal condition of embryological origin. The condition usually defined as the occurrence of ectopic pancreatic tissue outside the usual site of pancreas without any physiological, biochemical, anatomical or neuro-vascular connection with the original gland [1]. The relationship of ectopic pancreatic tissue associated with choledochal cyst is extremely rare condition [2]. Ectopic pancreatic tissue had been described in the previous literature in following organs include: the stomach, duodenum, jejunum, and spleen. Ectopic pancreatic tissue is rarely found in the ileum, liver, gall bladder, mediastinum, lungs, spleen, fallopian tubes, umbilicus, omentum bile ducts, and mesentery [3]. The most commonly reported cases of ectopic pancreatic tissue are located in the upper GI (gastrointestinal) tract with most frequent site is stomach, followed by the duodenum and the jejunum [4]. The incidence of pancreatic heterotopia generally ranges from 0.55% to 13.7% in autopsy series and 0.2% in laparotomies [5]. Few of previously reported cases of

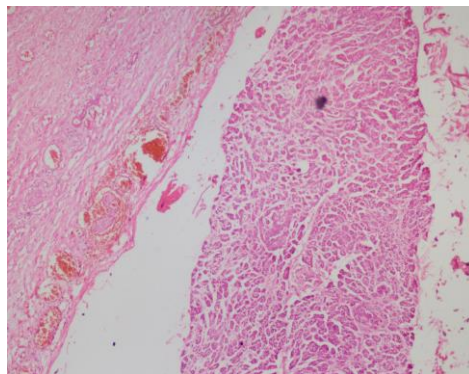
ectopic pancreas associated with choledochal cyst in the literature shows an incidental finding after cystectomy. The clinical implication of the presence of ectopic pancreas in the choledochal cyst is remain unclear but it's predicted risk for developing further complications, especially pancreatic malignancy should always be considered [6]. Ectopic pancreatic tissue can be diagnosed at all ages, males are frequently associated but a higher incidence of ectopic pancreas in the gallbladder is found in females and most of the cases are reported in literature lies between the thirty to sixty years of life [5]. The purpose of the present case is to present the clinical, and histopathological features of ectopic pancreatic tissue associated with choledochal cyst of 21 years old female.

### CASE REPORT

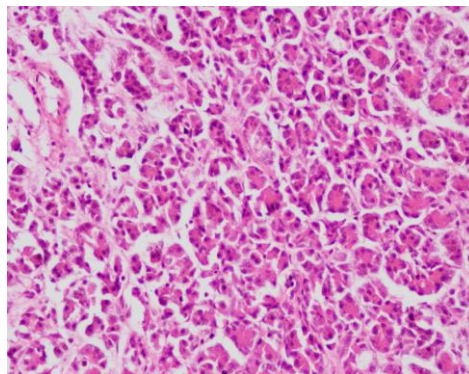
A 21 years old female patient was presented to OPD with complaints of pain in right upper quadrant for last four months. On inspection of abdomen, a visible lump was present over the epigastric region with

no visible peristalsis. On palpation, a prominent lump was felt in right hypochondrium and lumbar region which was firm in consistency and non mobile in nature. On percussion, tympanic note was present over swelling with no fluid thrill and shifting dullness. All the hernia sites appear to be intact with exaggerated bowel sounds. Her hematological investigation, creatinine, potassium, sodium levels was within normal range. Her serology investigation for IgG hydatid cyst or echinococcus and viral marker for HCV, HIV, HBsAg was negative. On radiological investigation, USG whole abdomen and pelvis shows markedly distended gall bladder with thinned out wall of gall bladder? gall bladder hydrops, Bilobar IHBRD, Splenomegaly, mild left pleural effusion, and mild ascites. X-ray chest was normal and MRI MRCP with upper abdomen shows large cystic lesion in right sub-hepatic space with dilatation of cystic duct and common hepatic duct with mild bilobar IHBRD and impression suggestive of choledochal cyst type IVA. Patient was

underwent for open cholecystectomy with choledochotomy. On gross examination of a globular cystic tissue piece labeled as choledochal cyst measuring 145x110x25 mm. Outer surface is unremarkable. Cut surface shows focally bile stained cystic surface with focal areas of hemorrhage. Wall thickness of cyst varies from 6-8 mm. Gall bladder specimen measures 80x40x20mm. Outer surface unremarkable. Cut surface shows bile stained, velvety mucosal surface. Wall thickness of gall bladder varies from 6-8mm. On microscopic examination of choledochal cyst shows cyst wall which is thickened and lined in focal areas by flattened or columnar cells, rest of the areas was ulcerated and shows biliary sludge. The wall of cyst shows fibro-collagenous tissue with non-specific inflammation and dilated congested blood vessels with presence of ectopic pancreatic tissue. Gall bladder shows chronic cholecystitis with adenomatous hyperplasia.



**Fig-1: HE stain showing fibrosed wall of Choledochal cyst with presence of Ectopic Pancreatic tissue (100x)**



**Fig-2: HE stain of Ectopic pancreatic tissue showing acinar glands with presence of ductal epithelium (200x)**

## DISCUSSION

The basic concept of occurrence of ectopic pancreatic tissue is contentious [7]. However, lots of theories had been earlier proposed for occurrence of ectopic tissue, including sequestration or transplantation or differentiation or delineation of totipotent endodermal cells of the gut into pancreatic tissue at the ectopic sites during different development stages of fetus [7]. Most of the cases of ectopic pancreas are clinically silent. On histo-pathological examination, acinar glandular tissue and ductal epithelial tissue is

always present at the ectopic site, whereas only one third of the cases shows presence of islet tissue [8]. The present case also represents an example of ectopic pancreatic tissue representing histo-pathological features including acinar glandular tissue with speckled endocrine cells within acinar epithelium. The most important clinical complication of ectopic pancreas which required long term follow up is malignant transformation, usually occurring in 0.7%–1.8% of cases [9].

The choledochal cyst is relatively rare congenital condition, in which there is dilatations of the extrahepatic biliary duct, typically detected before the first decade of life but it's occurrence also reported during adulthood. The proposed etiological factor for the development of choledochal cysts are due to anomalous arrangement of the pancreatico-biliary junction [10]. The clinical presentation of choledochal cysts are in the form of classical triad of abdominal pain, jaundice, and palpable mass, which is usually connected with symptoms and signs of biliary tract obstruction [10]. On investigation, Ultrasonographic (USG) evaluation is the best initial investigation. Also, USG can help in detection of complications associated with choledochal cysts such as acute or chronic pancreatitis, choledocholithiasis, portal vein thrombosis, intrahepatic biliary tract dilatation, gall bladder or biliary malignancies, and liver abscess. Most of the patients required CT and MRI (magnetic resonance imaging) scanning which usually give detailed information about the associated pathology between the lower end of the biliary duct and the pancreatic duct. Cholangiographic evaluation (ERCP or PTC) is essential part of investigation as it demarcate the biliary anatomy accurately, also to describe the level of the disease involvement [11]. The histo-pathological examination of choledochal cysts are usually nonspecific with most important pathological findings include the presence of inflammation with some degree of cyst wall fibrosis followed by presence of simple columnar lining epithelium of the cystic cavity, with or without epithelial proliferation, and goblet cell metaplasia. So, the diagnosis of choledochal cyst is exclusively based on radiological findings and histo-pathological examination of cystectomy specimen. Total excision of cyst with Roux-en-Y hepatico-jejunostomy, as done in the present case, is the mostly suggested [10]. The complications of choledochal cyst include formation of hepatic abscess, recurrent cholangitis and pancreatitis, and calculus formation. If choledochal cyst is untreated than it produces hepatic damage, which finally progresses to liver cirrhosis and portal hypertension [12].

The present case has rare distinctive features of choledochal cyst which is associated with presence of ectopic pancreatic tissue, had been reported in previous literature [7, 13]. The incidence of these two clinical conditions might support their embryological relationship and also have greater risk for development of complications, especially occurrence of malignant neoplasm. The excision of cyst alone will not provide full protection against malignant transformation, so all the cases of ectopic pancreas should require longer period of follow up.

## CONCLUSION

To conclude, the ectopic pancreatic tissue associated with choledochal cyst may be an evidence of its embryological association and it's greater risk for

development of further complications, especially development of pancreatic malignancy. The present case should be considered for long term follow up as only doing cystectomy will not provide full protection against the development of pancreatic malignancy.

## REFERENCES

1. Kondi-Paphiti, A., Antoniou, A. G., Kotsis, T., & Polimeneas, G. (1997). Aberrant pancreas in the gallbladder wall. *European radiology*, 7(7), 1064-1066.
2. González, C. C., González, C. F., Zurita, S. M., Cabrera, A. M., & García, M. J. (2013). Ectopic pancreas in the gallbladder. *Cirugia española*, 91(2), 130-131.
3. Shiwani, M. H., & Gosling, J. (2008). Heterotopic pancreas of the gallbladder associated with chronic cholecystitis. *JOP. J Pancreas (Online)*, 9(1), 30-32.
4. Bahadir, B., Ozdamar, S. O., Gun, B. D., Bektas, S., Numanoglu, K. V., & Kuzey, G. M. (2006). Ectopic pancreas associated with choledochal cyst and multiseptate gallbladder. *Pediatric and Developmental Pathology*, 9(4), 312-315.
5. Zarand, A., Bajtai, A., Baranyai, Z., Dede, K., & Jakab, F. (2011). Inflammation of ectopic pancreatic tissue in a Meckel's diverticulum causing acute abdominal symptoms: a case report and review of the literature. *International journal of surgical pathology*, 19(3), 359-363.
6. Sato, A., Hashimoto, M., Sasaki, K., Matsuda, M., & Watanabe, G. (2012). Elevation of pancreatic enzymes in gallbladder bile associated with heterotopic pancreas. A case report and review of the literature. *JOP. Journal of the Pancreas*, 13(2), 235-238.
7. Prasad, T. S., Gupta, S. D., & Bhatnagar, V. (2001). Ectopic pancreas associated with a choledochal cyst and extrahepatic biliary atresia. *Pediatric surgery international*, 17(7), 552-554.
8. Hara, M., & Tsutsumi, Y. (1986). Immunohistochemical studies of endocrine cells in heterotopic pancreas. *Virchows Archiv A*, 408(4), 385-394.
9. Jovanovic, I., Knezevic, S., Micev, M., & Krstic, M. (2004). EUS mini probes in diagnosis of cystic dystrophy of duodenal wall in heterotopic pancreas: a case report. *World Journal of Gastroenterology: WJG*, 10(17), 2609.
10. Levy, A. D., & Rohrmann Jr, C. A. (2003). Biliary cystic disease. *Current problems in diagnostic radiology*, 32(6), 233-263.
11. Vander, P. D., & Lane, B. W. (1988). Choledochal cysts. *Surgery Gynecology Obstetrics*; 167: 447.
12. Metcalfe, M. S., Wemyss-Holden, S. A., & Maddern, G. J. (2003). Management dilemmas with choledochal cysts. *Archives of Surgery*, 138(3), 333-339.

13. Suzuki, K., Uchida, T., Nakayama, H., Ugajin, W., Inaniwa, Y., Sugitani, M., & Mori, Y. (1999). Heterotopic pancreatic tissue associated with intra-and extrahepatic choledochal cysts. *Pathology international*, 49(8), 759-762.