

A Consolidated Review on Sinus Lift Procedures

Dr. V Sandeep Kumar¹, Dr. M Sai Swetha MDS², Dr. K Sridhar Reddy MDS³

¹Post-Graduate, Department of Oral & Maxillofacial surgery, Narayana Dental College and Hospital, Nellore, Andhra Pradesh, India

²Senior Lecturer, Department of Prosthodontics, Narayana Dental College and Hospital, Nellore, Andhra Pradesh, India

³Associate Professor, Department of Oral & Maxillofacial surgery, Narayana Dental College, and Hospital, Nellore, Andhra Pradesh, India

*Corresponding author: V. Sandeep Kumar

| Received: 15.03.2019 | Accepted: 22.03.2019 | Published: 31.03.2019

DOI: [10.21276/sjodr.2019.4.3.15](https://doi.org/10.21276/sjodr.2019.4.3.15)

Abstract

The posterior maxillary segment is frequently devoid of bone volume to support dental implants because of the resorption of the alveolar ridge and pneumatization of maxillary sinus. Such cases mandate the sinus lifting techniques prior to implant placement. Two main surgical approaches available and considered predictable so far are the lateral window technique and the crestal approach. Availability of various techniques, concepts and armamentarium, made the sinus lifting procedure versatile with high success rate. This article is aimed to describe the evolution of sinus lift techniques and to review the literature related to the technique considering the outcome of existing studies. An effort has been made to bring most of the available procedures under one classification for ease of understanding of the reader.

Keywords: Sinus lift, Sinus floor augmentation, Dental implants, Sinus graft, Osteotomes.

Copyright © 2019: This is an open-access article distributed under the terms of the Creative Commons Attribution license which permits unrestricted use, distribution, and reproduction in any medium for non-commercial use (NonCommercial, or CC-BY-NC) provided the original author and source are credited.

INTRODUCTION

The presence of maxillary sinus in the posterior maxilla creates a unique problem for implant placement after tooth extraction. The cause of this issue is increased pneumatization of maxillary sinus. Increased osteoclastic activity within the periosteum of the schneiderian membrane results in expansion of the maxillary sinuses. Also increased positive pressure is thought to contribute to alveolar bone atrophy [1]. The soft, type IV bone in the posterior maxilla has low resistance to these processes. The result is a decrease in vertical bone height (VBH) of the alveolus in the edentulous areas.

Davanpanah and colleagues [2] classified posterior maxillary bone loss into several categories:

- Vertical bone loss from within the sinus: reduced distance from the floor of the sinus to the alveolar ridge crest. However, no loss of interocclusal distance.
- Vertical bone loss of the alveolar ridge: loss of alveolar ridge below the sinus. There is an increase in interocclusal distance.
- Horizontal bone loss of alveolar ridge: a loss in buccopalatal width of alveolar bone.
- Combination subsinus loss: both vertical and horizontal bone loss.

Other grafting techniques suggest bone grafting or guided bone regeneration are required to treat the different atrophy patterns. This article focuses

on sinus augmentation techniques those using crestal and lateral approach, graft versus non grafted and various aids in sinus lifting other than conventional osteotomies to increase the VBH available for implant placement.

CLASSIFICATION OF THE AVAILABLE SINUS LIFTING PROCEDURES:

Based on approach to the maxillary sinus or technique involved:

- Buccal approach / lateral window technique
- Trans crestal approach

Based on the surgical technique [3]:

- Subantral option one(SA-1): conventional implant placement
- Subantral option two(SA-2): sinus lift and simultaneous implant placement
- Subantral option three(SA-3): sinus graft with immediate or delayed endosteal implant placement
- Subantral option four(SA-4): sinus graft healing and extended delay of implant insertion

Based on the use of bone graft:

- Graft techniques
- Non graft techniques

Based on the operating method for sinus lift:

With use of osteotome:

- Modified Summer's technique

- Fugazzotto's technique

Without the use of osteotome:

- Hydraulic sinus condensation
- Antral membrane balloon
- Piezoelectric bony window osteotomy

Based on approach to the maxillary sinus [4]

There are two main approaches to the sinus augmentation: transalveolar or crestal approach and lateral antrostomy (LA). The decision on which to use

is largely based on the residual alveolar bone. Rosen and colleagues found that implant survival decreases with the transalveolar approach when less than 4 mm of the bone is present. The LA approach was recommended when less residual bone or if more bone height is needed. This LA approach can opt the immediate implant placement or delay in implant placement after graft maturation. It is recommended that a minimum of 4 to 5mm of residual bone height to be present for immediate implant for attaining primary stability when using LA approach [4].

Table-1:

Transalveolar versus lateral antrostomy [5]	
4mm of residual bone height or less	Lateral antrostomy with delayed implant placement.
4-5mm of residual bone height	Lateral antrostomy, immediate implant placement if adequate stability can be achieved.
6mm of residual bone height or greater	Transalveolar technique.

Transalveolar Technique [6]

This is more conservative technique than LA approach. The sinus membrane is not directly instrumented. Also, the sinus cavity is not directly visualized and membrane perforations are more difficult to determine. Mid crestal incision along with vertical release incisions made along the lateral aspect of the maxillary alveolar ridge can be used to gain more access. A round bur is used to mark the surgical site along the alveolar ridge. A pilot drill with a diameter of 1 to 1.5 mm less than the final implant diameter is then used. The pilot hole is made to a depth approximately 2mm from the sinus floor. Creation of pilot hole is not necessary if 5mm or less of VBH is remaining. Next a mallet is used to drive successively larger osteotomes gradually to the final implant depth. Gradually increasing the depth decreases the potential for membrane tears. The smallest (first) osteotome fractures the sinus floor. The area of fracture increases as larger osteotomes are used. Single-site preparation is more prone to sinus perforation compared with multiple adjacent sites. The final osteotome should have a diameter approximately 0.5 mm less than the planned implant diameter. Before implant placement, some investigators have proposed the introduction of bone graft into the osteotomy site. The rationale is to increase the amount of bone between the apex of the implant and the sinus floor. Si and colleagues found similar implant survival rates and no advantage in grafted sites versus nongrafted sites.

Advantages:

1. Minimally invasive
2. Less surgical time

Disadvantages:

1. A minimum thickness of alveolar bone is must to attain primary stability
2. Benign paroxysmal positional vertigo due to tapping by the osteotome is reported in many.

3. No control over the force generated by mallet.

Lateral antrostomy technique [4]

A midcrestal or palatally positioned incision is made in a mesiodistal direction, and vertically releasing incisions are made. A full-thickness mucoperiosteal flap is elevated exposing the lateral wall of the maxillary sinus. The superoinferior and anteroposterior borders of the lateral window are determined by evaluating the CT radiograph. The inferior border of the window should be 2 to 5 mm superior to the sinus floor to prevent difficulty during infracturing. The anterior border is determined by the mesial extent of the sinus, whereas the distal border is in the area of the first molar. The window is created with a low-speed drill with a diamond bur or a piezoelectric instrument. The window is prepared until a bluish or reddish hue is visible along the outline of the preparation. This indicates proximity to the schneiderian membrane. The corners should be rounded to prevent sharp edges, which can potentially perforate the membrane. The bone window is then infractured into the sinus cavity and elevated in a superior direction along with the sinus membrane, which creates space inferior to the bone window for graft material. An alternative is to detach the bone window from the sinus membrane for use as an autologous graft. With either technique, the sinus membrane is gently elevated superiorly with blunt dissection. Graft material is introduced into the space created inferior to the sinus membrane. Graft should fill the cavity loosely. Overpacking the site can compromise angiogenesis into the graft or obstruct the primary ostium. As stated previously, sufficient VBH should be present if the decision is made to place implants at the time of sinus augmentation. The decision to place a membrane over the antrostomy site is based on provider preference. If a larger window is created, it is recommended that a barrier membrane be placed before closure. However, Torres Garcí a-Denche and colleagues found no significant difference if a

membrane was used versus not used. The mucoperiosteal flap is then sutured tension free.

Disadvantages

1. Perforation of sinus membrane (chance of 35%)
2. Long surgical time
3. Severe post op complications.
4. Sloping sinus complicates the buccal window approach especially when sinus access windows must be decorticated further superior and posterior to reach the cavity and the membrane (Figure-1).
5. In the buccal window approach, two access windows (A) are required to avoid septa. (Figure-2).

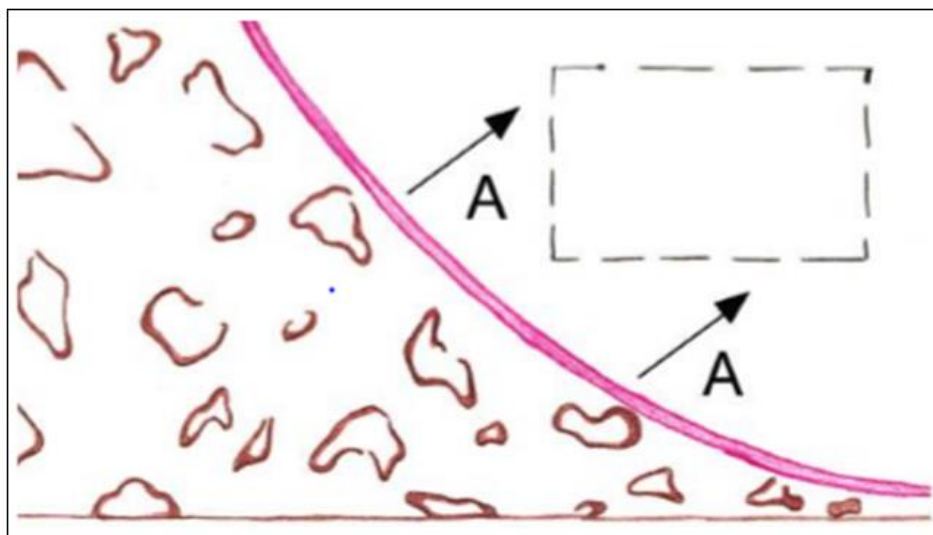


Fig-1:

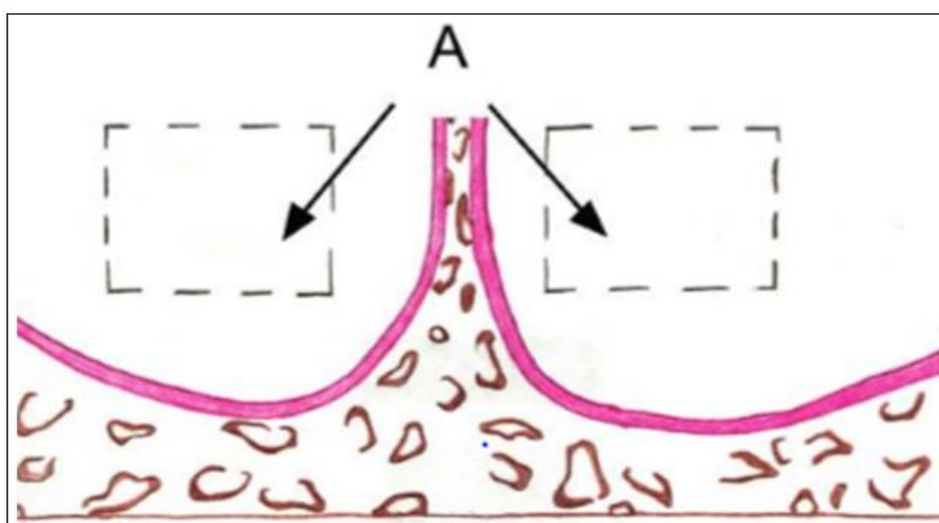


Fig-2:

Based on the use of bone graft: Graft Vs Non – graft [7-10]

Traditionally, the success of the maxillary sinus lift procedure is determined by the amount of vital bone formation after maturation of the graft and the long-term survival rate of the implants placed in that region. Various grafting materials have been used in maxillary sinus lift surgery, including autologous bone, xenogeneic bone, demineralized or mineralized allogeneic bone, and alloplasts. These grafts may have potential for osteogenesis, osteoconduction, or osteoinduction.

The non grafted techniques advocate the use of a resorbable space making device, a hollow hydroxyapatite space maintaining device, use of patients own blood, retained blood clot around the implant. According to Chen *et al.*, bone formation in the maxillary sinus does not require the presence of biomaterial. The maintenance of space for blood clot formation accompanied by the resorption and deposition of bone cells derived from the sinus periosteum or cancellous bone of the maxilla would be responsible for bone formation in this region.

According to the study by Altintas *et al.*, the density of newly formed bone in the group in which no graft was used was significantly higher than in the group in which graft material was used at 6 months of follow-up. However, this result became statistically insignificant at periods of longer than 6 months. Johansson *et al.*, and Chen *et al.*, suggested that a reduction in bone formation rate may occur, because any graft material has to be resorbed and replaced. One very important point may be that the grafted autogenous bone had to be replaced before new bone formation could occur in comparison with direct formation of bone from the blood clot. This event perhaps gives rise to “blocking” of the bone formation by the inflammation and removal that needs to take place in replacing old bone with new. This fact could explain the difference in bone density at 6 months seen in the study by Altintas *et al.*, and also a difference in pattern of bone formation with more marginal bone around implants resembling the human anatomy of sinus floor with protruding roots of the teeth, in non grafted technique.

Based on the operating method for sinus lift With use of osteotome

- Modified Summer's technique
- Fugazzotto's technique

With out the use of osteotome

- Chen's hydraulic sinus condensation
- Antral membrane balloon elevation.
- Piezoelectric bony window osteotomy

With use of osteotome [11]

One of the pioneers of sinus augmentation surgery, Dr. Hilt Tatum, experimented with access to the sinus floor through the ridge crest before abandoning this approach in the early 1980s in favor of the lateral window. Tatum's original crestal technique required a variety of instruments, including burs, channel formers, curets, and socket formers of his design, to remove the bone between the ridge crest and sinus floor. Once the bony floor of the sinus was

exposed, a small osteotome or socket former was used to crack the sinus floor and elevate the schneiderian membrane. The membrane was manipulated directly with antral curets to create a space into which the graft material could be packed. In some cases, a non-root form implant of Dr. Tatum's design was inserted immediately. The crestal approach as envisioned by Tatum proved too limiting, and the Caldwell-Luc operation became the norm for sinus grafting. More recently, modifications of the crestal approach to sinus surgery have been described.

Modified Summer's technique [11]

Drilling in the posterior maxilla can be a frustrating experience, as bone texture becomes softer and control of the handpiece more difficult. Tactile sense diminishes in this type of bone, and over preparation is common place. The use of osteotomes with concave tips and matched sizing allows osteotomy preparation in soft bone without drilling. The osteotome technique attempts to retain all of the bone that is present and to relocate this bone in an advantageous manner. As the instruments are inserted beneath the sinus, bone is displaced laterally and moved toward the antral floor because of the concave osteotome tips. Bone at the sinus floor is not cortical in nature. It is readily flexed upward with repeated pressure from the instrument tip as the bone particles and trapped fluid are pushed inward by the osteotomes. It is possible to elevate the antral floor by simply intruding the existing bone in the site (osteotome sinus floor elevation [OSFE]). However, adding graft bone into the osteotomy (bone-added osteotome sinus floor elevation [BAOSFE]) makes inadvertent perforation of the schneiderian membrane less likely. The graft bone added during BAOSFE plus the trapped fluids act like a hydraulic plug to push up the membrane. The BAOSFE procedure allows the surgeon to accurately and consistently control the ultimate height of the grafted space with less chance of perforation of the sinus membrane (Figure-3).

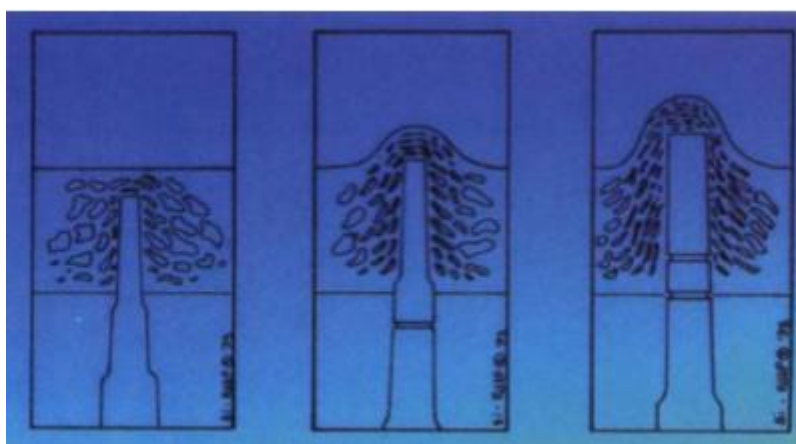


Fig-3: Bone-added osteotome sinus floor elevation technique

Advantages:

1. Trauma and invasiveness are reduced with instrumentation through the ridge crest.
2. The need for a distant donor site is eliminated in most cases.

Disadvantages:

1. Benign paroxysmal positional vertigo due to tapping by the osteotome is reported
2. Lack of tactile discrimination.

Fugazzotto's Technique [12]

With 4 mm or less of pre existing bone, delayed insertion of implants is recommended. A two-stage protocol is suggested, with the initial procedure designed to generate additional bone. This surgery is termed future site development (FSD). Autogenous bone is repositioned along with the membrane, providing a continuing source of live cells and bone morphogenic proteins. This relocated bone is still attached to its blood supply in the schneiderian membrane, and so it should remain. With conservative displacement, the repositioned bone and the cut sidewalls have potential for more rapid healing than ground bone that has been removed from its blood supply. Implants can be inserted 7 to 8 months after FSD.

Fugazzotto has described a similar technique which uses trephines of various external diameters followed by an osteotome to implode a core of

maxillary posterior alveolar bone before placement of regenerative materials, in anticipation of subsequent implant placement.

Technique: (Figure 4, 5 & 6)

After incision and mucoperiosteal flap reflection, a calibrated trephine bur (Ace Surgical Supply, Brockton, MA) of the largest external diameter possible, without compromising the buccal and palatal line angles of the residual alveolar ridge, was placed at the site of anticipated augmentation and subsequent implant placement. Using preoperative radiographs and a residual ridge morphology as a guide, the trephine was employed to prepare the site to within 1–2 mm of the sinus membrane at a maximum cutting speed of 500 rpm. A calibrated offset osteotome was selected to correspond to the diameter of trephine preparation. The osteotome was used under gentle malleting forces, to implode the trephine bone core to a depth approximately 1 mm less than that of the prepared site. Such measurements were possible due to the calibration of both the trephine and the osteotome. The osteotomy site was gently packed with Bio-Oss (Geistlich, Inc., Bern, Switzerland) and covered with a BioGuide membrane (Osteohealth Company, Shirley, NY), which was secured with fixation tacks. The mucoperiosteal flaps were replaced and sutured. Sites were re-entered approximately 4 to 5 months postoperatively and implants were placed.

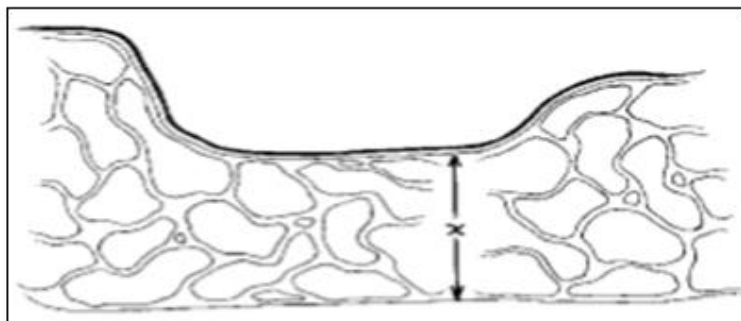


Fig-4: Showing the process of trephination

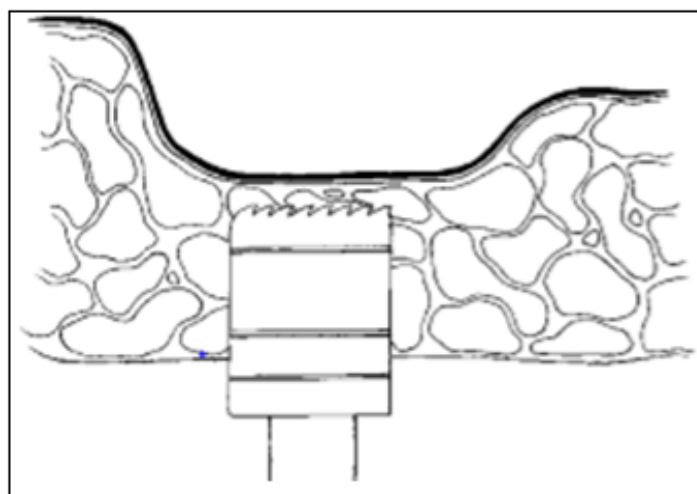


Fig-5: Showing the process of trephination

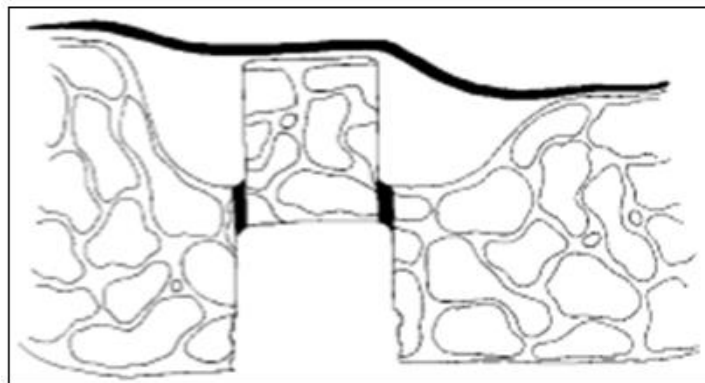


Fig-6: Showing the process of trephination

Advantages:

1. Less traumatic and disconcerting to the patient than repeated malleting in an attempt to compact 4 to 5 mm of bone and lift the floor of the sinus with the initial osteotome
2. Minimize the chances of sinus perforation and unpredictable core displacement
3. If a longer implant is desired, the trephine technique is again used to implode the floor of sinus for attaining apico-occlusal dimension.

Without the use of osteotome

The techniques presented under this section, uses specialised equipments recommended by the corresponding authors.

Hydraulic sinus condensation [13]

Leon chen in 2005, advocated a new internal crestal approach by use of minimally invasive hydraulic sinus condensation.

Armamentarium

A sinus condensing kit was developed especially for this procedure. It consists of round diamond sinus burs with 1, 2, and 3 mm diameters. Titanium-coated sinus graft condensers are supplied in 2, 3, 5, and 6mm diameters. The sinus condensers are marked at depths of 3, 5, 8, and 10 mm. Using these tools in combination with hydraulic pressure supplied by a surgical hand piece, clinicians can safely separate the Schneiderian membrane from the sinus floor and prepare the area for immediate implant placement in a fashion that takes advantage of anatomical features normally viewed as restrictive.

Technique

When planning for a 5 mm or similarly wide implant, an osteotomy is initiated with a 3 mm round diamond sinus bur. Drilling ceases about 1 mm short of the sinus floor. The surgeon then downsizes to a 2 mm sinus bur for the purpose of forming a narrower conical shape at the end of the osteotomy. This step in the drilling process is crucial to the formation of the pinhole through which graft material will be pushed to initially loosen the Schneiderian membrane. Constant pressure is applied to the foot pedal of the high-speed handpiece to apply hydraulic pressure to the osteotomy while drilling. This hydraulic pressure provides enough force to atraumatically dissect the membrane from the sinus floor. Once the membrane is loosened the pressure is ceased and the preferred graft material i.e; a mixture of demineralised freeze dried bone matrix combined with a smaller amount of spherical shaped peptide coated powder is packed and condensed against the soft tissue using 3mm sinus condenser. The applied pressure will begin to loosen the membrane, while the conical 2 mm shape at the end of the osteotomy blocks the 3 mm condenser from entering the sinus cavity. Following this step, additional drilling and condensing occurs, using wider bits and condensers in diameters that are appropriate for the size of implant to be used. The author recommends the use of 1cc of mixture for 5mm increment of sinus augmentation. To facilitate stabilization, tapered implant models with closely spaced threads and wide cover screw were recommended (Figure 7-14).

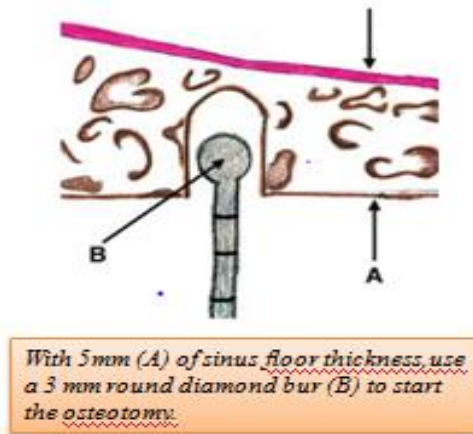


Fig-7:

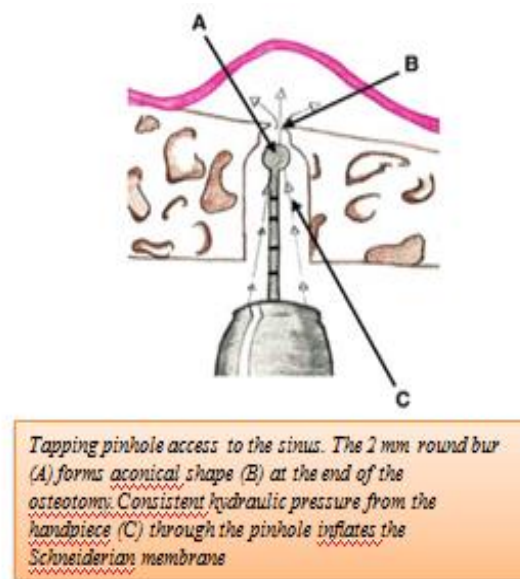


Fig-8:

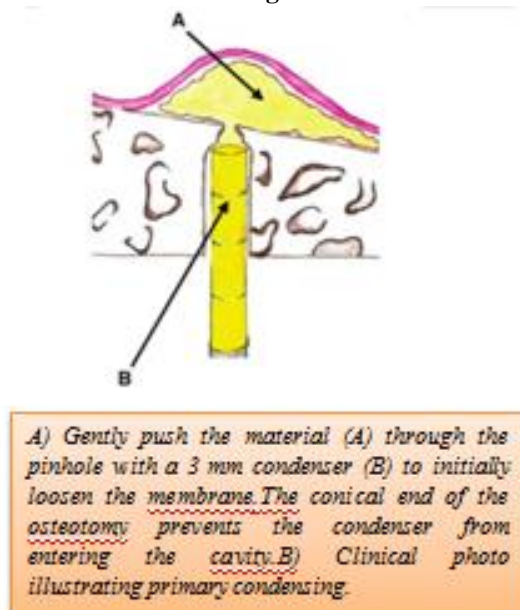
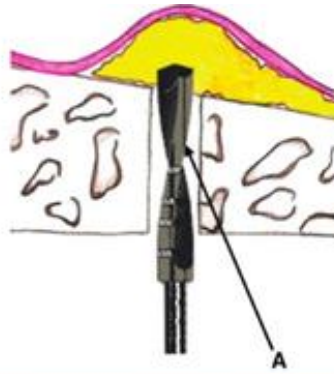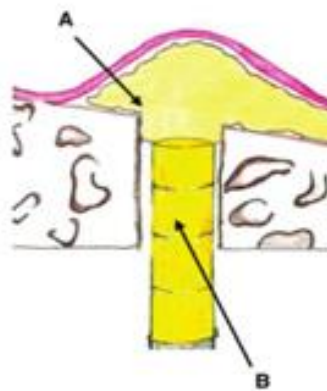


Fig-9:



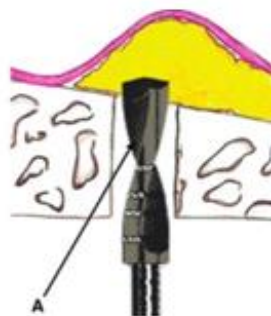Widen the osteotomy with a 3 mm implant drill (A). The bone graft mixture will insulate the drill bit from the membrane.

Fig-10:



A) Use a combination of mineralized bone with at least 50% peptide-coated particulate (A) for the secondary graft. Pack the material in with a wider condenser (B). B) Clinical photo illustrating secondary condensing with the wider sinus condenser

Fig-11:



A) Use an appropriately sized drill (A) to widen the osteotomy for implant placement. B) Clinical photo illustrating the final drill

Fig-12:

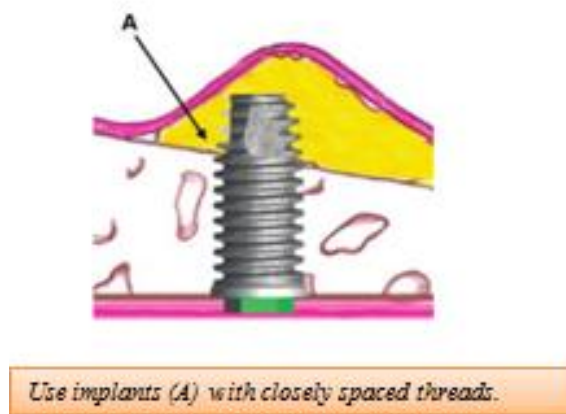


Fig-13:

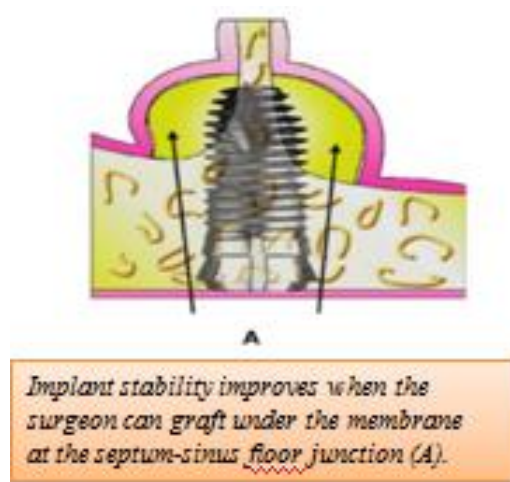


Fig-14:

Advantages:

1. Risk of Trauma to sinus membrane is less with use of hydraulic condensation.
2. Provides a greater margin of tactile control
3. Atraumatic because cortical bone is perforated rather than fractured
4. Permits implant placement in the presence of complex nasal cavity.
5. Used safely with sloped sinuses or sinus with multiple septae.

Disadvantages:

1. Risk of air embolism is a matter of controversy with this technique.

Antral membrane balloon elevation (AMBE) [14]

Sinus lift surgery is predictable and is usually not technically demanding. However, it is a more difficult surgical technique when teeth are adjacent to the edentulous area. The AMBE advocated by Muna Soltan in 2005, is a modification and combination of surgical techniques that adds sufficient bone height to allow placement of longer implants of up to 16 mm.

The balloon operation and graft procedure described herein can be used to augment a severely atrophic ridge and does not depend on the accessible ridge height, as does the crestal approach, which uses trephines and osteotomes. The requirement here is for a beginning bone height of at least 4 to 6 mm.

Armamentarium

1. A 5-mm trephine or a #8 round diamond
2. A large spoon curette or modified sharp Freer elevator (G. Hartzell & Son Inc, Concord, Calif)
3. A balloon made of latex material (Osseous Technologies of America, Huntington Beach, Calif)
4. A resorbable collagen membrane (Reguarde Membrane, Clinician's Preference, Golden, Colo) is soaked with platelet-rich plasma (PRP) (Harvest Technologies Corp, Conyers, Ga)
5. OrthoBlast II (Reguarde Membrane) or C-Graft (Reguarde Membrane)

Technique: (Figure-15)

A routine surgical procedure of incision and full thickness mucoperiosteal flap reflection carried out as in lateral window approach. Osteotomy of buccal bone is performed using a 5mm trephine or #8 round diamond. Once the bluish hue is attained, the resulting bony fenestration is gently pressed inward, carrying the underlying membrane along with it. A large spoon curette or modified sharp Freer elevator is necessary to elevate the membrane from the antral floor. This dissection should progress all the way to the medial wall of the sinus. Before inserting the balloon, it should be inflated with 3 to 4 mL of sterile saline to check for leaks. It is then emptied and placed against the sinus floor. At the juncture of medial and lateral walls, a balloon made of latex material is placed and inflated with 2 to 4 ml of sterile saline and as it expands, the

membrane is elevated. This technique offers optimal assurance that the fragile epithelium will be subjected to minimal trauma. After the resultant antral space is obtained, the balloon is then deflated and removed. A resorbable collagen membrane soaked in platelet rich plasma (PRP) is placed under the elevated sinus membrane. The space created by the expanded balloon is grafted with an appropriate xenograft or allograft combination such as OrthoBlast II or C-graft mixed with PRP. The graft is deposited into the antral void and loosely condensed. Loose compaction is continued until the lateral wall of the sinus is rebuilt. A second bone regenerative membrane is trimmed, moistened with PRP or aqueous antibiotic and placed over the lateral wall window. The mucoperiosteal flap is repositioned and sutured. After AMBE, implants were placed simultaneously with the graft.

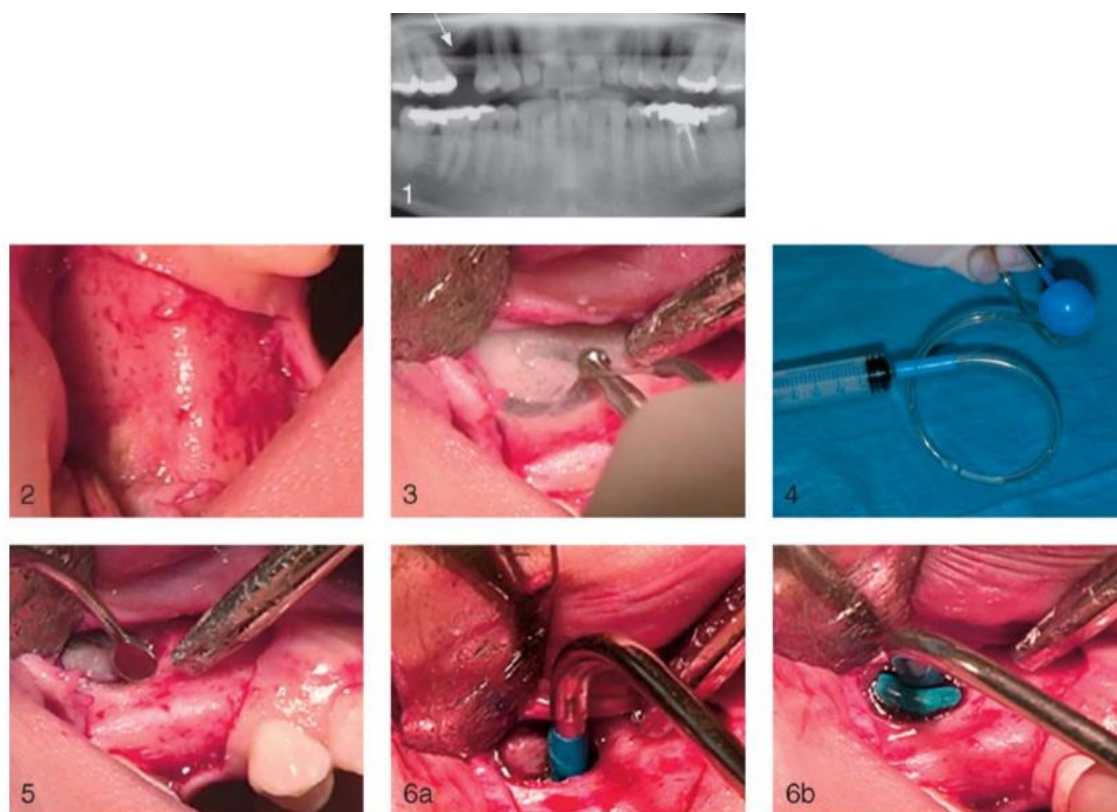


Fig-15: Antral membrane balloon elevation technique

Advantages:

1. Beneficial when access is difficult and when adjacent teeth are present next to the edentulous area.
2. Less chair side time (30 seconds) is required.
3. Reduced postoperative pain, bleeding, possibilities of infection.
4. A conservative, tissue-sparing surgical approach

Disadvantages:

1. Unlike some of the currently used techniques, which are performed from a crestal approach,

AMBE requires a buccal fenestration and a larger incision than do other alternative operations.

The Piezoelectric Bony Window Osteotomy and Sinus Membrane Elevation [15]

The technique advocated by Tomaso Vercellotti in 2001, employs piezoelectric osteotomy for preparing bony window with simplicity and precision. This is due to the cessation of the surgical action when the scalpel comes into contact with non mineralized tissue. The separation of the endosteum

from the flat bone is achieved by the ultrasonic vibrations of the piezoelectric elevator working on the internal part of the sinus bone walls and by hydropneumatic pressure of a physiologic solution subjected to piezoelectric cavitation.

Armamentarium

1. Specifically engineered device (Mectron Piezosurgery System)
2. Bioabsorbable membrane (Gore OsseoQuest Regenerative Membrane, 3i/WL Gore)

The Mectron Piezosurgery System consists of a platform with a very powerful piezoelectric handpiece with a functional frequency of 25 to 29 kHz and the possibility of a digital modulation of 30 Hz. There are four sinus lift surgical inserts: diamond scalpel, conical compressor, and two differently shaped elevators. The inserts move with a linear vibration of between 60 and 210 μm , providing the handpiece with power exceeding 5 W and a high-powered pump that emits the physiologic solution.

Technique

After ascertaining the lack of any sinus pathology, the average thickness of the lateral wall of sinus is determined on CT. After incision an deflection of the mucoperiosteal flap, With the No. 1 scalpel from the Sinus Lift system by Mectron Piezosurgery, an outline was drawn. It began with the most coronal horizontal incision, with a length of approximately 14 mm positioned approximately 3 mm apical to the residual crestal bone. Two vertical incisions of 6 to 7 mm were made and united at the top by another horizontal incision. This produced a bony window in which the frame is represented by the schneiderian membrane (sometimes red in color, sometimes blue). At this point, the osteotomy was completed by rounding the angles of the window.

The No. 2 insert, a compressor in the shape of an overturned cone, was inserted into the edge of the frame of the membrane exposed by the osteotomy. At this point, the No. 3 insert (an angled periosteal elevator with rounded edges) or the No. 4 (a straight periosteal elevator), depending on the anatomic situation, was used in the following order. The first stage of the membrane elevation begins in the apical position. The insert is directed towards the mesial surface until it meets the anterior wall and then directed towards the distal walls, separating the membrane to obtain the

volume required for the graft to build the future implant site. This maneuver is carried out last in a way that allows the separation of the membrane floor without tension, having already separated the membrane from the other sides of the window. The membrane was elevated using a combination of the mechanical action of the piezosurgical elevators and the high-pressure physiologic solution that is pumped out of the elevator itself. The sinus augmentation procedure was performed using autogenous bone graft mixed with autogenous platelet-rich plasma gel. The platelet concentration was obtained by a 50-mL venous blood extraction for each sinus procedure, taken 0.5 hour before surgery. After the bone graft was performed and the bioabsorbable membrane (Gore OsseoQuest Regenerative Membrane, 3i/WL Gore) was positioned to cover the bony window and fixed to the bone with screws, horizontal mattress sutures with Gore-Tex CV5 and separate point stitches with Gore-Tex CV6 (3i/WL Gore) were placed. Healing period of 6 months was recommended followed by delayed implant placement.

Advantages

- Good tactile sense
- Limited bone cutting
- Decrease in soft tissue injury

Juanjuan *et al.*, [16] in 2013 has modified this technique to expose the floor of maxillary sinus through intra crestal pathway using Satelec piezosurgery kit and simultaneous implant placement in residual bone height of 2 to 5 mm. Some potential advantages of the method are reduced trauma and reduced rate of sinus membrane perforation during surgery, no malleting and shorter surgery time.

CONCLUSION

Sinus augmentation is a procedure that plays a large role in maxillary implant placement in the posterior maxilla. Arriving at a diagnosis and treatment plan for the augmentation is paramount to the success of the graft and future implant placement. A variety of surgical maneuvers are used. The direct techniques offer the best visualization and control. The indirect techniques are good options when 3mm or less augmentation is required. The decision to place implants at the time of augmentation should be based on the availability of approximately 5mm of native bone to produce primary stability. When considering grafting material, autogenous bone has the best chance of success; however in areas of small grafting demands or if it is not possible to obtain sufficient autogenous bone, other materials heal well with good success. The use of non - autogenous materials in the office setting will continue to be the main choice for the practioners. Inspite of various techniques discussed in this article, the choice of specific technique depends on the case selection, posterior maxillary bone height, and measurements of maxillary sinus & associated pathologies.

REFERENCES

1. Hansson, S., & Halldin, A. (2012). Alveolar ridge resorption after tooth extraction: A consequence of a fundamental principle of bone physiology. *Journal of dental biomechanics*, 3.
2. Davarpanah, M., Martinez, H., Kebir, M., Etienne, D., & Tecucianu, J. F. (2001). Wide-diameter implants: new concepts. *International Journal of Periodontics & Restorative Dentistry*, 21(2), 149-159.
3. Misch, C. E. (1999). Contemporary implant dentistry. *Implant Dentistry*, 8(1), 90.
4. Harry, D. (2015). Implant procedures for general dentist. DCNA.
5. Balaji, S. M. (2013). Direct v/s Indirect sinus lift in maxillary dental implants. *Annals of maxillofacial surgery*, 3(2), 148.
6. Pjetursson, B. E., & Lang, N. P. (2014). Sinus floor elevation utilizing the transalveolar approach. *Periodontology 2000*, 66(1), 59-71.
7. Parra, M., Olate, S., & Cantín, M. (2017). Clinical and biological analysis in graftless maxillary sinus lift. *Journal of the Korean Association of Oral and Maxillofacial Surgeons*, 43(4), 214-220.
8. Brizuela, A., Martín, N., Fernández-Gonzalez, F. J., Larrazábal, C., & Anta, A. (2014). Osteotome sinus floor elevation without grafting material: Results of a 2-year prospective study. *Journal of clinical and experimental dentistry*, 6(5), e479.
9. Riben, C., & Thor, A. (2012). The maxillary sinus membrane elevation procedure: augmentation of bone around dental implants without grafts—a review of a surgical technique. *International journal of dentistry*, 2012.
10. Carrao, V., & DeMatteis, I. (2015). Maxillary sinus bone augmentation techniques. *Oral and Maxillofacial Surgery Clinics*, 27(2), 245-253.
11. Summers, R. B. (1998). Sinus floor elevation with osteotomes. *Journal of Esthetic and Restorative Dentistry*, 10(3), 164-171.
12. Fugazzotto, P. A. (2001). The modified trephine/osteotome sinus augmentation technique: technical considerations and discussion of indications. *Implant dentistry*, 10(4), 259-264.
13. Chen, L., & Cha, J. (2005). An 8-year retrospective study: 1,100 patients receiving 1,557 implants using the minimally invasive hydraulic sinus condensing technique. *Journal of Periodontology*, 76(3), 482-491.
14. Soltan, M., & Smiler, D. G. (2005). Antral membrane balloon elevation. *Journal of Oral Implantology*, 31(2), 85-90.
15. Vercellotti, T., De Paoli, S., & Nevins, M. (2001). The piezoelectric bony window osteotomy and sinus membrane elevation: introduction of a new technique for simplification of the sinus augmentation procedure. *International Journal of Periodontics & Restorative Dentistry*, 21(6).
16. www. Internet source.com