

# 5 Year Retrospective Study of Odontogenic Tumours and Cysts Seen In Paediatric Patients at a Nigerian Tertiary Center

Adeola Ladeji, BDS, FMCDS<sup>1</sup>, Mofoluwaso Olajide, BDS, FMCDS<sup>1</sup>, Kehinde Adebiyi, BDS, FWACS<sup>1</sup>, Olufemi Adesina, BDS, FMCDS<sup>2\*</sup>, Titus Oyedele, BDS, FWACS<sup>3</sup>, Aderonke Abah BDS, FMCDS<sup>1</sup>, Ismail Abayomi, BDS<sup>1</sup>

<sup>1</sup>Department of Oral Pathology and Oral Medicine, Lagos State University College of Medicine, Ikeja, Lagos, Nigeria

<sup>2</sup>Department of Oral Maxillofacial Surgery, Lagos State University College of Medicine, Ikeja, Lagos, Nigeria

<sup>3</sup>Department of Surgery, Babcock University, Ilisan-Remo, Ogun State, Nigeria

\*Corresponding author: Dr. Adesina Oluwafemi Adewale | Received: 05.04.2019 | Accepted: 13.04.2019 | Published: 22.04.2019  
DOI: [10.21276/sjpm.2019.4.4.1](https://doi.org/10.21276/sjpm.2019.4.4.1)

## Abstract

**Background:** Odontogenic lesions are tumours and cysts originating from the odontogenic epithelium and or ectomesenchyme and its vestiges. They are a wide array of cystic and neoplastic lesions which have been seen in all age groups. There is robust knowledge on the epidemiology of odontogenic tumours in all age groups, however paediatric odontogenic tumours due to their relative rarity have not been well researched and this has led to a conspicuous paucity of literature and knowledge gap on the specific demographics of these lesions in the paediatric age group. **Objectives:** To assess the prevalence, age, gender and site distribution of odontogenic tumours and cysts seen at the Lagos State University Teaching Hospital within the paediatric group between January 2013 and December 2017. **Materials and methods:** Records from the archives of the Department of Oral Pathology and Medicine, Faculty of Dentistry over a period of 5 years (January 2013 to December 2017) were reviewed. Information relating to the type of paediatric odontogenic lesion, age, gender and site of lesion was extracted and recorded on data forms. Lesions were grouped into primary dentition (0 to 5 years), mixed dentition (6 to 12 years) and permanent (13 to 17 years) dentition periods. Data was analyzed using SPSS (version 20). **Result:** Paediatric odontogenic lesions comprised 40 cases (29.63%) of the total odontogenic lesions, 30.53% of all paediatric lesions and 6.64% of all paediatric orofacial lesions seen within the 5 year study period (January 2013 to December 2018). Odontogenic cysts accounted for 10 cases (25%), while odontogenic tumours accounted for 30 cases (75%) of all the childhood odontogenic lesions. All tumors encountered were benign. Solid ameloblastoma was the most frequently encountered lesion accounting for 11 cases (27.5%) followed by unicystic ameloblastoma with 9 cases (22.5%). Dentigerous cyst was the commonest cyst observed accounting for 6 cases (15%). 95% of lesions were observed within the mixed and permanent dentition periods, majority (86.7%) of tumours occurred in the permanent dentition period. A male predilection was observed at a ratio 1.4:1. Mandible was the commonest site, accounting for 22 cases (55%), with the maxilla accounting for 17 cases (42.5%). **Conclusion:** Odontogenic lesions are not just rare in the paediatric age group but extremely rare in the deciduous dentition period. Contrary to previous reports, benign odontogenic tumours are more frequently seen than the cysts in this study. Odontogenic tumours occurred more in the permanent dentition period while odontogenic cysts were observed in the mixed dentition stage. The mandible was the preferred site and lesions were observed more in the male gender.

**Keywords:** Paediatric, odontogenic, lesions, cysts, tumours.

**Copyright @ 2019:** This is an open-access article distributed under the terms of the Creative Commons Attribution license which permits unrestricted use, distribution, and reproduction in any medium for non-commercial use (NonCommercial, or CC-BY-NC) provided the original author and sources are credited.

## INTRODUCTION

Odontogenesis begins when the primitive oral epithelium, under the inductive influence of the neural crest cells begins to thicken, forming a bud into the underlying connective tissue. This epithelium goes through a series of changes and forms the enamel organ. The enamel organ from oral epithelium with dental papilla and follicle from ectomesenchyme go through a series of morphogenetic and histogenetic

changes before forming the dental hard and soft tissues [1].

After completion of tooth formation, these tooth forming structures undergo regressive changes and remain as reduced enamel epithelium, rests of malassez, rests of serres and others [1, 2]. The rests of odontogenic epithelium, ectomesenchyme and their vestiges under the right inductive influences begin to proliferate leading to neoplastic and cystic pathologic conditions [3]. Classification of odontogenic tumours

and cysts has evolved over the years. The World Health Organisation recently classified the tumours and cysts using their tissues of origin [3].

Most of the processes of odontogenesis, tooth eruption and exfoliation take place in the paediatric age [1]. There is no universally accepted cut off for the paediatric age group, as different researchers have employed variable cut offs between 15 and 18 years [4-6]. An individual goes through 3 stages of dentition in childhood; primary (0- 5 years), mixed (6-12 years) and permanent (13- 18 years) dentitions stages [7]. The activities of the odontogenic epithelium and ectomesenchyme are at the peak during these periods of active tooth formation and exfoliation. Studies have however shown that odontogenic tumours and odontogenic cysts are rare in childhood [6, 8, 9]. This study aims to assess the prevalence, age, gender and site distribution of these odontogenic lesions in the paediatric age group.

## MATERIALS AND METHODOLOGY

This was a retrospective analysis of records from the archives of the Oral pathology laboratory of the department of Oral Pathology and Medicine, Faculty of Dentistry, Lagos State University College of Medicine, Lagos Nigeria, over a period of 5 years (January 2013 to December 2017). This laboratory provides histopathological services to the Lagos State University Teaching Hospital. Patients within 0 to 17 years paediatric age range were further grouped into primary dentition (0 to 5 years), mixed dentition (6 to 12 years) and permanent dentition (12 to 17 years) periods (6) Information relating to the type of paediatric odontogenic lesion, age, gender and orofacial site of lesion was extracted and recorded on data forms.

Tumours were analysed according to age, site, gender, type of paediatric odontogenic lesion (POL). Data was analysed using Statistical Package for Social Sciences version 20 (SPSSv.20.0; SPSS, Chicago, IL, USA). Descriptive statistics were carried out for socio-demographic variables such as age, sex, site and type of lesion. Quantitative variables (age) were expressed

using parameters such as mean, median, minimum, maximum and measures of variability. Qualitative descriptive variables such as sex, site of lesion, type of lesion were expressed as frequencies and percentages.

The institutional review board of the Lagos State University approved this study.

## RESULT

Paediatric odontogenic lesions seen were; Solid multicystic ameloblastoma(SMA), unicystic ameloblastoma(UA), keratocystic odontogenic tumour (KCOT), adenomatoid odontogenic tumour(AOT), odontoma, dentigerous cyst, odontogenic keratocyst(OKC) and radicular cyst.

A total of 602 head and neck lesions and 131 paediatric head and neck lesions were recorded over the 5 year study period (January 2013 to December 2018) out of which 135 cases (22.43%) of all lesions were odontogenic tumours and cysts.

Paediatric odontogenic lesions (POL) comprised 40 cases (29.63%) of the total odontogenic lesions observed, 30.53% of all paediatric lesions and 6.64% of all lesions.

Paediatric Odontogenic Cysts (POC) accounted for 10 cases (25%), while Paediatric Odontogenic Tumours (POT) accounted for 30 cases (75%) of all the childhood odontogenic lesions (Figure-1).

Solid ameloblastoma was the most frequently encountered lesion accounting for 11 cases (27.5%) followed by unicystic ameloblastoma with 9 cases (22.5%). Dentigerous cyst was the commonest cyst observed accounting for 6 cases (15%) (Figure-1).

Mandible was the commonest site, accounting for 22 cases (55%), with the maxilla accounting for 17 cases (42.5%). Relationship between site and type of lesion was significant at  $p= 0.002$  (Table-2).

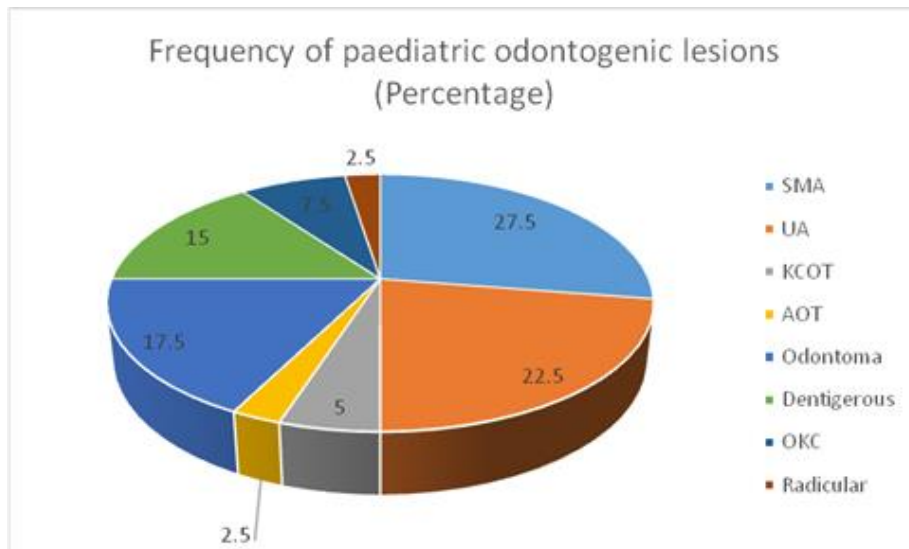


Fig-1:

Lesions were observed between the 5 and 17 years age range, with a mean age of  $13.30 \pm 2.64$  years. Twenty six (65%) of lesions were observed in the permanent dentition period with a single lesion

observed in the deciduous dentition stage. Cases of Solid multicystic ameloblastoma, AOT and OKC seen were exclusively in the permanent dentition (Table-1).

Table-1: Distribution of Paediatric Odontogenic lesions within Age groups

Age groups (Years)	SMA	UA	KCOT	AOT	ODONTOMA	DENTIGEROUS CYST	OKC	RADICULAR CYST	Total/n (%)	Percentage (%)
0 – 5	0(0.0)	0(0.0)	0(0.0)	0(0.0)	0(0.0)	1(16.7)	0(0.0)	0(0.0)	1(2.5)	2.5
6 – 12	0(0.0)	3(33.3)	0(0.0)	0(0.0)	1(14.3)	5(83.3)	3(100.0)	1(100.0)	13(32.5)	32.5
13 – 17	11(100.0)	6(66.7)	2(100.0)	1(100.0)	6(85.7)	0(0.0)	0(0.0)	0(0.0)	26(65.0)	65.0
Total	11(100.0)	9(100.0)	2(100.0)	1(100.0)	7(100.0)	6(100.0)	3(100.0)	1(100.0)	40(100.0)	100.0

Mean $\pm$ SD=13.30 $\pm$ 2.638 p=0.157 df=9

Lesions were commoner in males than females at a ratio of 1.4 to 1 (Figure 2).

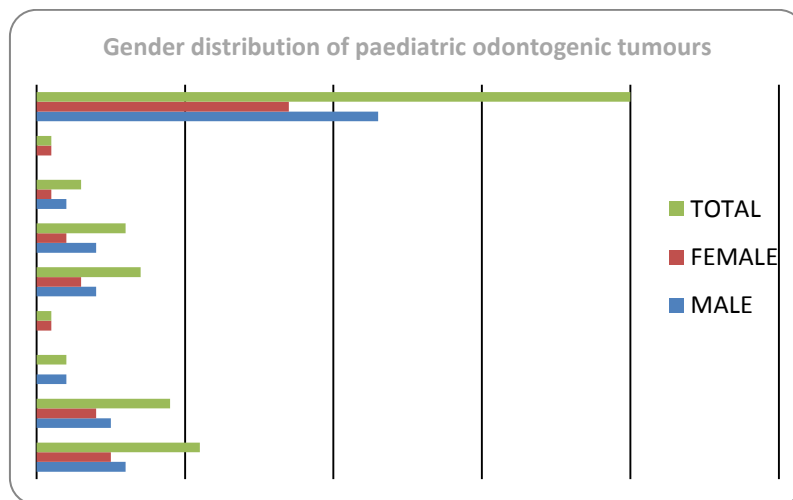


Fig-2:

Mandible was the commonest site, accounting for 22 cases (55%), with the maxilla accounting for 17

cases (42.5%). Relationship between site and type of lesion was significant at  $p=0.002$  (Table-2).

**Table-2: Site Distribution of Paediatric Odontogenic lesions**

Site	SMA N (%)	UA N (%)	KCOT N (%)	AOT N (%)	Odontoma N (%)	Dentigerous cyst N (%)	OKC N (%)	Radicular cyst N (%)	Missing N (%)	Total N (%)
Mandible	11 (100.0)	3 (33.3)	2 (100.0)	1 (100.0)	2 (28.6)	0 (0.0)	3 (100.0)	0 (0.0)		22 (55)
Maxilla	0 (0.0)	6 (66.7)	0 (0.0)	0 (0.0)	5 (71.4)	5 (100.0)	0 (0.0)	1 (100.0)		17 (42.5)
Total	11 (100.0)	9 (100.0)	2 (100.0)	1 (100.0)	7 (100.0)	5 (100.0)	3 (100.0)	1 (100.0)	1 (100.0)	40 (100.0)

Df=5 p=0.002

## DISCUSSION

Over the 5- year study period, 21.7 % of all diagnosed lesions were seen in the paediatric age group comparable with reports by Zuniga *et al.*, [10] in Chile and Lei *et al.*, [11] in Taiwan who reported 20.6% and 19.16% respectively, although a much lower frequency of 2.38% was reported by Skiavounou *et al.*, [12] in Greece. This wide variation can be attributed to genetic, racial and environmental factors. Odontogenic lesions in childhood accounted for 29.63% of all odontogenic lesions seen in all ages, they are therefore less frequently seen in childhood when compared with adults as previously reported [4-6]. Close comparison may however be difficult due to the variability in the acceptable age range for paediatric population employed by different researchers [4, 6, 8, 9].

Within the paediatric age, in this study odontogenic tumours accounted for 22.9% of all orofacial paediatric lesions, this is comparable to reports from Nigeria by Arotiba *et al.*, [13] and Adebayo *et al.*, [14] who reported 18.4% and 25.9% respectively, while Ulmansky *et al.*, [15] in Israel reported much lower prevalence of 9.5%. POCs constituted 7.7% of the paediatric lesions, a value lower than 13.9% reported by da Silva *et al.*, in Brazil [8]. POTs made up 75% of the POLs in this study while POCs accounted for the remaining 25%, this is comparable to reports of Soyele *et al.*, in Nigeria [4], who reported higher prevalence of odontogenic tumours but at variance with many studies which reported higher occurrence of odontogenic cysts [6, 8, 16, 17]. These variations may be attributed to geographic variations in the study populations.

Eight types of POLs were encountered in this study comprising 5 POTs (SMA, UA, KCOT, AOT and Odontoma) and 3 POCs (Dentigerous cyst, OKC and Radicular cyst). Conventional ameloblastoma was the commonest lesion observed accounting for 8.4% of all paediatric lesions, 27.5% of POLs and 36.7% of paediatric tumours, this is comparable to reports of Lawal *et al.*, [9] and Arotiba *et al.*, [13], but at variance with reports by Fang *et al.*, [6], Soluk *et al.*, [16] and Johnson *et al.*, who reported odontoma, dentigerous cyst and radicular cyst respectively as most common POLs. Unicystic ameloblastoma was next in frequency constituting 22.5% of the POLs. Dentigerous cyst was the commonest odontogenic cyst observed accounting for 50% of all odontogenic cysts. This contrasts with findings by da Silva *et al.*, [8], Soluk *et al.*, [16] and Johnson *et al.*, [17] who reported higher prevalence of

radicular cyst but agrees with reports by Fang *et al.*, [6] and Nannan *et al.*, [18] with higher prevalence of dentigerous cyst,

As high as 95% of tumours were observed within the mixed and permanent dentition periods with a lone case of dentigerous cyst found in the primary dentition period, a finding corroborated by Soyele *et al.*, [4], Fang *et al.*, [6] and Soluk *et al.*, [16]. This study also agrees with findings of Fang *et al.*, and Soluk *et al.* who recorded highest percentage of tumours in the permanent dentition period. All cases of Solid multicystic ameloblastoma, Keracystic odontogenic tumour and Adenomatoid odontogenic tumour were observed in the permanent dentition period. This is pointing to the probable role played by time, which allows for accumulation of genetic mutations and environmental factors in the predisposition to these lesions.

This study revealed a predilection for the male gender with a male to female ratio of 1.4:1 which is similar to findings of previous studies [4, 6, 16].

Mandible was the site of predilection for POLs with a statistically significant relationship at  $p = 0.002$ . It is worthy of note that all cases of SMA occurred in the mandible while all reported cases of dentigerous cyst were observed in the maxilla. This is comparable to findings in previous studies from Nigeria, Brazil and China by Soyele *et al.*, [4], Lawal *et al.*, [9], da Silva *et al.*, [8] and Fang *et al.*, [6].

## CONCLUSION

The major findings in this study are broadly similar to results of previous studies, however variation in the frequency of paediatric odontogenic cysts and paediatric odontogenic tumours observed may be attributed to environmental, lifestyle and genetic differences.

### Conflict of Interests

Authors declare that there is no conflict of interest regarding the publication.

## REFERENCES

1. Avery, J. K., & Chiego, D. J. (2006). Essentials of Oral histology and embryology: A clinical approach. 6<sup>th</sup> edition. Missouri: Mosby Elsevier.
2. Berkovitz, B. K. B., Holland, G. R., & Moxham, B. J. (2009). Oral Anatomy, Histology and

- Embryology: 4<sup>th</sup> edition. Edinburgh: Mosby Elsevier, 299-339.
3. Odontogenic tumours and cysts. (2017). In: El-Naggar, A. K., Chan, J. K. C., Grandis, J. R., Takata, T., Slootweg, P. J., editors. WHO classification of tumours of the head and neck, 4<sup>th</sup> ed. Lyon: IARC Press, 261-273.
  4. Soyele, O. O., Aborisade, A. O., Olatunji, A. S., & Adeola, H. A. (2017). Evaluation of pediatric oral and maxillofacial biopsies from a Tertiary Hospital in Sub-Saharan Africa. *Journal of Pediatric Dentistry*, 5(2), 43-49.
  5. Lima, G. D. S., Fontes, S. T., Araújo, L. M. A. D., Etges, A., Tarquinio, S. B. C., & Gomes, A. P. N. (2008). A survey of oral and maxillofacial biopsies in children: a single-center retrospective study of 20 years in Pelotas-Brazil. *Journal of Applied Oral Science*, 16(6), 397-402.
  6. Fang, O. G., Shi, S., & Sun, S. F. (2014). Odontogenic lesions in paediatric patients. *Journal Craniofac Surg*, 25(3): 248-251.
  7. Nikhil, M. Textbook of Paediatric dentistry 2<sup>nd</sup> edition. New Delhi: Jaypee Brothers Medical Publishers, 119-149.
  8. da Silva, L. P., Amanda-Katarinny-Goes Gonzaga, M. L., Severo, B., Caio-César-da Silva Barros, A., de Medeiros, M. C., & de Souza, L. B. (2018). Epidemiologic study of odontogenic and non-odontogenic cysts in children and adolescents of a Brazilian population. *Medicina oral, patologia oral y cirugia bucal*, 23(1), e49-50.
  9. Lawal, A. O., Adisa, A. O., & Popoola, B. O. (2013). Odontogenic tumours in Children and Adolescents: A Review of Forty-Eight Cases. *Annals of Ibadan postgraduate medicine*, 11(1), 7-11.
  10. Zuñiga, M. D., Méndez, C. R., Kauterich, R. R., & Paniagua, D. C. (2013). Paediatric oral pathology in a Chilean population: a 15-year review. *International journal of paediatric dentistry*, 23(5), 346-351.
  11. Lei, F., Chen, J. Y., Lin, L. M., Wang, W. C., Huang, H. C., Chen, C. H., & Chen, Y. K. (2014). Retrospective study of biopsied oral and maxillofacial lesions in pediatric patients from Southern Taiwan. *Journal of Dental Sciences*, 9(4), 351-358.
  12. Skiavounou Dr. Odont, A., Iakovou, M., Kontos-Toutouzas, J., Kanellopoulou, A., & Papanikolaou Dr. Odont, S. (2006). Intra-osseous lesions in Greek children and adolescents. A study based on biopsy material over a 26-year period. *Journal of Clinical Pediatric Dentistry*, 30(2), 153-156.
  13. Arotiba, G. T., Ladeinde, A. L., Arotiba, J. T., Ajike, S. O., Ugboko, V. I., & Ajayi, O. F. (2005). Ameloblastoma in Nigerian children and adolescents: a review of 79 cases. *Journal of oral and maxillofacial surgery*, 63(6), 747-751.
  14. Adebayo, E. T., Ajike, S. O., & Adekeye, E. O. (2005). A review of 318 odontogenic tumors in Kaduna, Nigeria. *Journal of oral and maxillofacial surgery*, 63(6), 811-819.
  15. Ulmanky, M., Lustmann, J., & Balkin, N. (1999). Tumors and tumor-like lesions of the oral cavity and related structures in Israeli children. *International journal of oral and maxillofacial surgery*, 28(4), 291-294.
  16. Tekkesin, M. S., Tuna, E. B., Olgac, V., Aksakalli, N., & Alatlı, C. (2016). Odontogenic lesions in a pediatric population: Review of the literature and presentation of 745 cases. *International journal of pediatric otorhinolaryngology*, 86, 196-199.
  17. Johnson, N. R., Gannon, O. M., Savage, N. W., & Batstone, M. D. (2014). Frequency of odontogenic cysts and tumors: a systematic review. *Journal of investigative and clinical dentistry*, 5(1), 9-14.
  18. Li, N., Gao, X., Xu, Z., Chen, Z., Zhu, L., Wang, J., & Liu, W. (2014). Prevalence of developmental odontogenic cysts in children and adolescents with emphasis on dentigerous cyst and odontogenic keratocyst (keratocystic odontogenic tumor). *Acta Odontologica Scandinavica*, 72(8), 795-800.