

# Intraoperative Frozen Section versus Permanent Section in Various Histopathological Specimens

Dr. Gurvi Chauhan<sup>1</sup>, Dr. Anita Harsh<sup>2\*</sup>, Dr. Deepika Hemrajani<sup>3</sup>, Dr. Ajay Yadav<sup>4</sup>

<sup>1</sup>Resident Doctor, Department of Pathology, SMS Medical College, Jaipur, Rajasthan, India

<sup>2</sup>Associate Professor, Department of Pathology, SMS Medical College, Jaipur, Rajasthan, India

<sup>3</sup>Associate Professor, Department of Pathology, SMS Medical College, Jaipur, Rajasthan, India

<sup>4</sup>Sr. Professor, Department of Pathology, SMS Medical College, Jaipur, Rajasthan, India

\*Corresponding author: Dr. Anita Harsh

| Received: 08.04.2019 | Accepted: 16.04.2019 | Published: 30.04.2019

DOI: [10.21276/sjpm.2019.4.4.4](https://doi.org/10.21276/sjpm.2019.4.4.4)

## Abstract

Frozen section provides a rapid diagnosis intra or perioperatively that guides the surgeon to make a therapeutic decision for the patient's health benefit. The comparison between the frozen section diagnosis and permanent section diagnosis is an integral part of quality assurance in surgical pathology. This study was performed to assess the diagnostic accuracy of frozen section at different anatomic sites assuming histopathology as a gold standard. This prospective cross sectional study was performed in the Pathology laboratory adjoining the operation theatre and Department of Pathology S.M.S Medical College and Hospital, Jaipur, during a period of 2 years from January 2017 to December 2018. The results of 170 cases of frozen section were compared with their permanent section diagnosis and analysed. A total of 224 frozen section specimens from 170 cases were studied. The diagnoses were deferred in 4 (1.79%) specimens. Out of remaining 220 specimens, the concordant and discordant diagnostic frequencies were 215 (95.98%) and 5 (2.23%) respectively. Discrepancies were mainly related to misinterpretation, sampling and technical errors. The overall diagnostic accuracy was 97.73%. The sensitivity, specificity, positive predictive value and negative predictive value were 92.68%, 98.88%, 95% and 98.33% respectively. The average turn-around time calculated was 20 minutes. Our study concurred that the frozen section is a rapid, reliable and an accurate technique to guide the surgeons in deciding the best therapeutic approach for the patients. The accuracy rate can be further improved by regular monitoring of frozen section performance.

**Keywords:** Frozen section diagnosis, Permanent section, Turn-around time, Accuracy.

**Copyright © 2019:** This is an open-access article distributed under the terms of the Creative Commons Attribution license which permits unrestricted use, distribution, and reproduction in any medium for non-commercial use (NonCommercial, or CC-BY-NC) provided the original author and sources are credited.

## INTRODUCTION

The frozen section is a technique of rapid microscopic analysis of tissue in a pathological laboratory, most often performed in oncological surgery.

The frozen section procedure was introduced by William H. Welch in 1891 from John Hopkins Hospital. This technique has been achieved a high level of accuracy after the development of cryostat in 1959 [1, 2].

The main indication of intraoperative consultation is to differentiate between benign and malignant nature of surgical specimens in order to make an immediate decision during a surgical procedure. It also provides necessary information regarding nature of tissue, clearance of margin and distant metastasis in various tissues sent for the examination [3, 4].

The diagnostic accuracy is assessed by comparison of frozen section with the permanent section diagnosis. It varies according to the anatomic sites and technique used in frozen section. The efficiency of frozen section can be improved by identifying deficiencies, evaluating discrepancies and resolving the underlying problems.

This study was carried out with the aim to assess the diagnostic accuracy of frozen section examination at various anatomical sites assuming histopathology as gold standard.

## MATERIAL AND METHODS

The present study was carried out in the Pathology laboratory adjoining the operation theatre and Department of Pathology S.M.S Medical College and Hospital, Jaipur. It is a descriptive, observational study started after approval by ethical committee of institution. During the period of 2 years, from January

2017 to December 2018, a total of 224 specimens from 170 cases were received from surgical department. Tissue specimens from different anatomic sites were taken for frozen section examination. The necrotic, haemorrhagic, bony and hard tissues were excluded from the study.

The fresh tissue specimens along with patient's requisition were verified. The representative sections were frozen in the cryostat (Thermoscientific Microm HM 525) using a gel like medium the OCT compound and adjusting the temperature depending on the nature of tissues. The blocks were cut into sections of 5-7 $\mu$ m thickness, mounted on glass slides, fixed immediately in absolute alcohol for 5 minutes and rapidly stained with Haematoxylin and Eosin. The slides were examined microscopically and the frozen section diagnoses were immediately informed to the operating surgeon via intercom.

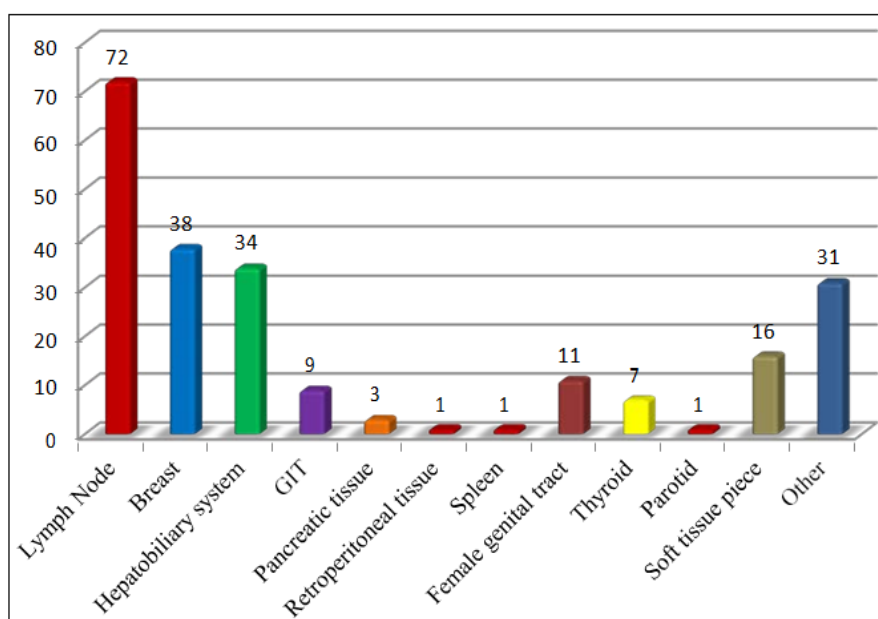
The remaining tissue specimens were fixed in 10% buffered formalin and processed for permanent section in automated tissue processor. The sections were stained by routine Haematoxylin and Eosin. The results of frozen section were compared with the

permanent section diagnoses to assess the diagnostic accuracy. The sensitivity, specificity, positive predictive value, negative predictive value and the turn-around time of the frozen section were determined and compared with the permanent section.

## RESULTS

In the present study, majority of patients were females 96 (56%) with male to female ratio (M: F) of 1:1.29. The age ranged from 7 years to 82 years. The most of patients 45 (26.47%) were between the age group of 41-50 years.

A total of 224 specimens were received from 170 cases for intra-operative consultation. The majority of 72 (32.14%) specimens were obtained from lymph nodes followed by 38 (16.96%) specimens from breast, 34 (15.18%) from hepatobiliary system (Gall bladder, liver and CBD), 31 (13.84%) from others (margins, bone marrow, skin nodule, perineural tissue, perinephric fat and deep tissue from ulcer). One (0.45%) specimen each from retroperitoneal tissue, spleen and parotid was given for frozen section examination.



**Fig-1: Distribution of specimens according to anatomical sites/tissue types**

The commonest indication of frozen section was metastasis in 96 (42.86%) specimens followed by diagnosis in 71 (31.69%) specimens, evaluation of margins in 56 (25%) specimens and to see nerve involvement in 1 (0.45%) specimen.

Out of 224 specimens, 4 specimens one each from breast, ovary, soft tissue and lymph node showed inconclusive results on frozen section. They were deferred for permanent section diagnosis with a deferred rate of 1.79%. These 4 specimens were not included for the statistical analysis.

After deferral of one specimen, lymph nodes comprised of 71 specimens in which 70 specimens showed concordant results and have diagnostic accuracy of 99.55%. In one specimen the diagnosis of normal lymphoid tissue on frozen section turned out to be positive for malignancy on permanent section. This case constituted a false negative result on frozen section.

Out of 34 specimens of hepatobiliary system, 32 specimens had concordant diagnoses with the

diagnostic accuracy of 99.09%. In 2 specimens from a single case of gall bladder, the diagnosis of micro-invasive adenocarcinoma (malignant) on frozen section turned to be inflammation related atypia (benign) on final diagnosis. This case comprised a false positive result on frozen section.

Three specimens from pancreatic tissue showed the diagnostic accuracy of 99.55%. In one specimen, the diagnosis was negative for malignancy on frozen section while well differentiated adenocarcinoma was diagnosed on permanent section comprised a false negative result.

Out of 31 specimens of other category, 1 specimen from bone marrow had a discordant diagnosis, it was negative for malignancy on frozen section and positive for metastasis on permanent section. This gave a false negative result. The accuracy rate of frozen section for other category was found to be 99.55%.

37 specimens of breast, 15 specimens from soft tissues, 10 from female genital tract, 9 from gastrointestinal tract, 7 from thyroid region and one

specimen each from retroperitoneal tissue, spleen and parotid showed 100% diagnostic accuracy.

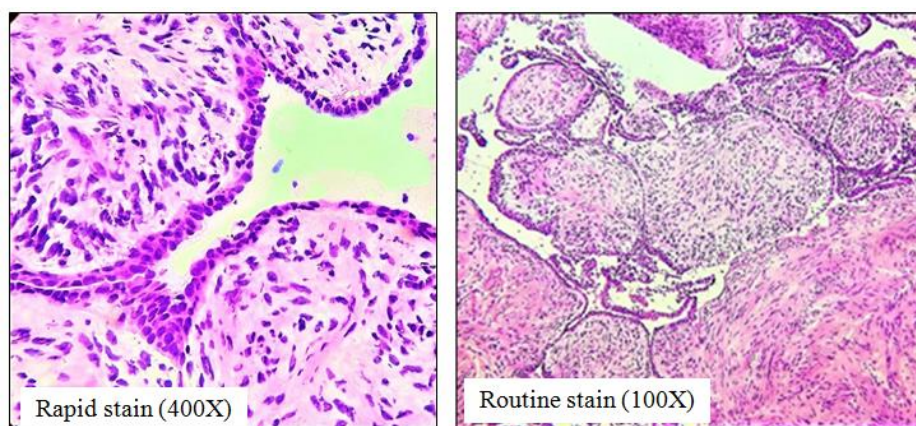
The concordant diagnoses were found in 215 (95.98%) specimens and the discordant diagnoses were seen in 5 (2.23%) specimens. Discrepancies were comprised of 3 false negative and 2 false positive errors and these were mainly due to misinterpretation, sampling and technical errors. The overall diagnostic accuracy of frozen section in comparison with permanent section was 97.73%. The sensitivity, specificity, positive predictive value and negative predictive value were 92.68%, 98.88%, 95.00% and 98.33% respectively.

We evaluated the accuracy of frozen section in various tissues as shown in the table given below. The organ wise accuracy of frozen section ranged from 99.09% in hepatobiliary system to 100% in breast, gastrointestinal tract, retroperitoneal tissue, spleen, female genital tract, thyroid, parotid and soft tissues.

The average turn-around time calculated was 20 minutes.

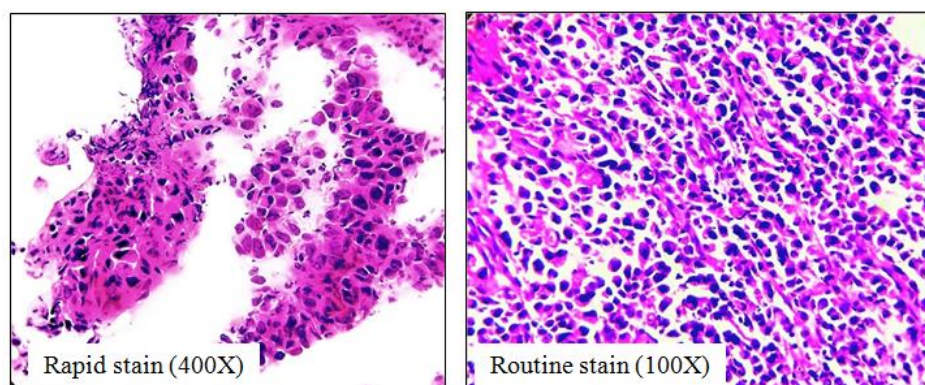
**Table-1: Diagnostic accuracy of frozen sections in various tissues**

Anatomical Site	Number of specimens	Sensitivity	Specificity	Positive Predictive Value	Negative Predictive Value	Accuracy
Lymph Node	71	98.59	100	100	99.33	99.55
Breast	37	100	100	100	100	100
Hepatobiliary system	34	100	98.94	94.12	100	99.09
Gastrointestinal tract	9	100	100	100	100	100
Pancreatic tissue	3	66.67	100	100	99.54	99.55
Retroperitoneal tissue	1	100	100	100	100	100
Spleen	1	100	100	100	100	100
Female genital tract	10	100	100	100	100	100
Thyroid	7	100	100	100	100	100
Parotid	1	100	100	100	100	100
Soft tissues	15	100	100	100	100	100
Others	31	96.77	100	100	99.47	99.55

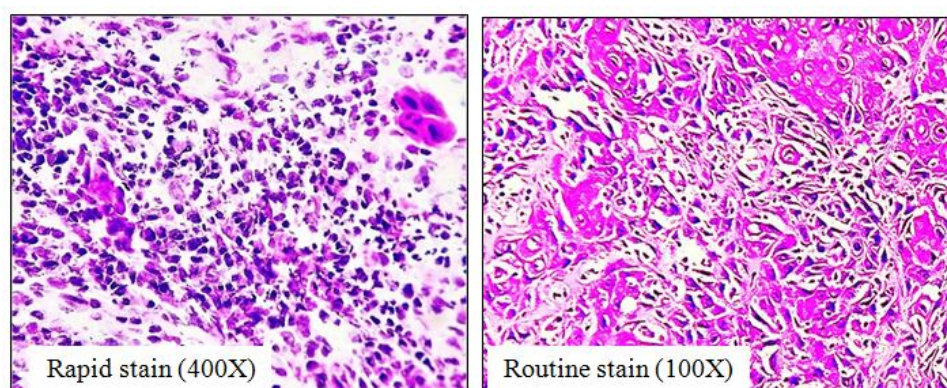


**Fig-2: Haematoxylin & Eosin stain- Breast tissue showing stromal hyperplasia with leaf like pattern- Benign Phyllodes tumor**

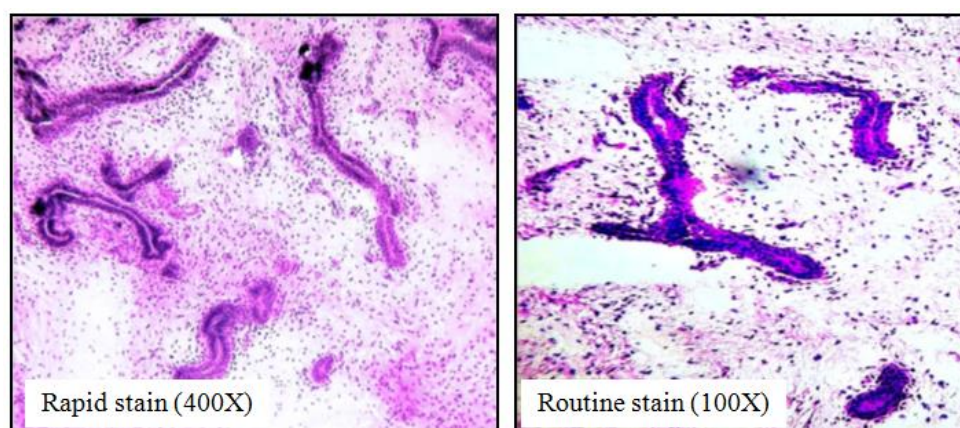




**Fig-3: Haematoxylin & Eosin stain- Gall bladder showing sheets of pleomorphic cells with eosinophilic cytoplasm & eccentric nuclei- Signet ring cell carcinoma**



**Fig-4: Haematoxylin & Eosin stain- Lymph node showing pleomorphic squamous cells and lymphoid cells- Metastatic squamous cell carcinoma**



**Fig-5: Haematoxylin & Eosin stain- Breast tissue showing benign looking tubules and glands in a fibromyxoid stroma – Fibroadenoma**

## DISCUSSION

Frozen section is very useful, highly accurate, reliable and rapid procedure necessary for optimum patient care. Although the frozen section technique is costly, but is a cost effective way of avoiding an unnecessary surgical procedure in many cases [5]. Technical skills and diagnostic expertise are essential for frozen section. Frozen section is more difficult to interpret than examination of paraffin embedded permanent section. Certain indications and limitations are need to be taken into consideration.

The pathologist should defer the diagnosis when the situation warrants it and in the deferral cases the surgeon should proceed as though the frozen section had never been performed. The deferral rate ranges from 1 to 6.6% in various published studies. In our study deferral rate of 1.79% found which was within the range of other studies [6-8].

Out of 224 specimens, 4 specimens were deferred for the permanent section diagnosis. One

specimen from breast showed inconclusive result on frozen section was diagnosed as benign phyllodes tumor on permanent section. As phyllodes tumor has spectrum of neoplastic behaviour that ranges from benign, borderline to malignant. Frozen section tends to alter the morphology of cell and stromal architecture, so the pathologist found difficulty in diagnosis.

A case of ovary was deferred for final diagnosis, reported as adenocarcinoma on permanent section. The reason is extensive sampling is required in cases of ovarian tumors to make a diagnosis [6, 9].

One specimen each from soft tissue and lymph node was inconclusive on frozen section, diagnosed as negative for malignancy on paraffin embedded permanent section. This is because sometimes, in frozen section diagnosis freezing artefacts and blotted cell morphology may alter the cellular and nuclear details that may cause either misinterpretation or deferred diagnosis [10, 11].

The discordant frequency rate was 2.23% in our study, mainly due to misinterpretation followed by sampling and technical errors. 5 specimens showed discordant results.

One specimen from lymph node was reported as normal lymphoid tissue on frozen section found to be positive for malignancy on permanent section. This false negative result was due to sampling error in which diagnostic tissue was not seen in the frozen block but was present in the deeper section of the permanent block.

Two specimens from a single case of gall bladder diagnosed as microinvasive adenocarcinoma on frozen section were reported as inflammation related

atypia on permanent section constituted false positive result. The reason is sometimes, inflammation related atypia may mimic malignancy, so can be misdiagnosed.

One specimen of pancreatic tissue was negative for malignancy on frozen section turned out to be well differentiated adenocarcinoma on final diagnosis. This gave a false negative error. A well differentiated adenocarcinoma may appear as normal pancreatic morphology at times.

A specimen from others category (bone marrow) was misinterpreted as negative for malignancy on frozen section and had given false negative outcome. This misinterpretation was mainly due to technical error that comprised of poor staining quality and areas of haemorrhage that obscured the morphology of squamous cells and led to misdiagnosis.

The outcome of the false negative and false positive frozen diagnosis would have been affected the further patient management, but did not occur in our study because the diagnoses were immediately discussed with experienced pathologists and operating surgeons and the revised diagnoses were given during the procedures.

The overall accuracy of frozen section diagnosis reported in the literature varies from 94.6% to 97.96% [12-14]. Our study showed an accuracy rate of 97.73% which was found within the range reported.

The sensitivity of frozen section reported in the study was 92.68% which was comparable with the other studies [12-14]. The specificity of frozen section in literature ranges from 94.55% to 99.55% [6, 12, 14]. We observed specificity of 98.88% which was within the range.

Sensitivity (%)	Specificity (%)	PPV (%)	NPV (%)	Accuracy (%)
92.68	98.88	95.00	98.33	97.73

The average turn-around time calculated in the present study was 20 minutes, which was comparable with the other studies [6, 15]. The turn-around time was measured from the specimen received in the laboratory to giving the final report of pathologist through communication to the surgeon during the procedure.

## CONCLUSION

The study proved that the diagnostic accuracy of frozen section procedure in our institution is comparable with the national and international published data. Hence, the frozen section can be used to evaluate a variety of pathological entities at different anatomic sites. It is a rapid, reliable and an accurate technique. Avoiding technical errors, better communication between pathologists and surgeons, combination of knowledge and experience in

interpretation of morphological details can help to further reduce the discordant and deferral rates and help the surgeons to plan the best management for the patients. Regular monitoring of the performance of the frozen section diagnosis is required to improve the accuracy.

## REFERENCES

1. Hwang, T. S., Ham, E. K., Kim, C. W., Chi, J. G., & Park, S. H. (1987). An evaluation of frozen section biopsy in 4434 cases. *Journal of Korean Medical Science*, 2(4), 239-245.
2. Folkerth, R. D. (1994). Smears and frozen sections in the intraoperative diagnosis of central nervous system lesions. *Neurosurgery Clinics of North America*, 5(1), 1-18.

3. Byers, R. M., Bland, K. I., Borlase, B., & Luna, M. (1978). The prognostic and therapeutic value of frozen section determinations in the surgical treatment of squamous carcinoma of the head and neck. *The American Journal of Surgery*, 136(4), 525-528.
4. Kraemer, B. B., & Silva, G. (1988). The examination of margins of resection by frozen section. *Part I. Surg Pathol*, 1, 437-66.
5. Wen, M. C., Chen, J. T., & Ho, W. L. (1997). Frozen-section diagnosis in surgical pathology: a quality assurance study. *The Kaohsiung journal of medical sciences*, 13(9), 534-539.
6. Patil, P., Shukla, S., Bhake, A., & Hiwale, K. (2015). Accuracy of frozen section analysis in correlation with surgical pathology diagnosis. *Int J Res Med Sci*, 3(2), 399-404.
7. Mohammed, A. B. F., Ahuja, V. K., & Farghaly, H. (2015). Role of frozen section in the intraoperative management of ovarian masses. *Middle East Fertility Society Journal*, 20(2), 97-101.
8. Kaira, V., Gupta, A. K., Agarwal, A., Kala, S., & Kaira, P. (2018). Frozen Section versus Paraffin Section in Diagnosis of Breast Lesions: A Comparative Study. *Clinical Cancer Investigation Journal*, 7(2), 70.
9. Subbian, A., Devi, U. K., & Bafna, U. D. (2013). Accuracy rate of frozen section studies in ovarian cancers: A regional cancer institute experience. *Indian journal of cancer*, 50(4), 302.
10. Laucirica, R. (2005). Intraoperative assessment of the breast: guidelines and potential pitfalls. *Archives of pathology & laboratory medicine*, 129(12), 1565-1574.
11. Jaafar, H. (2006). Intra-operative frozen section consultation: concepts, applications and limitations. *The Malaysian journal of medical sciences: MJMS*, 13(1), 4-12.
12. Shrestha, S., Basyal, R., Pathak, T. S. S., Lee, M. C., Dhakal, H., Pun, C. B., & Pradhan, M. (2009). Comparative study of frozen section diagnoses with histopathology. *Post-Graduate Medical Journal of NAMS*, 9(2), 1-5.
13. Abbasi, F., Yekta, Z., & Aryan, A. (2012). Accuracy of Frozen Sections. *Iranian Journal of Pathology*, 7(1), 3-8.
14. Hatami, H., Mohsenifar, Z., & Alavi, S. N. (2015). The diagnostic accuracy of frozen section compared to permanent section: a single center study in Iran. *Iranian journal of pathology*, 10(4), 295-299.
15. Mishra, S., Gupta, M., Bharat, P., & Bansal, R. (2016). Qualitative Comparative Study of Frozen Section with Routine Histological Technique. *National Journal of Laboratory Medicine*, 1-7.