

Original Research Article

Effect of Reperfusion on the Clinical Course, Left Ventricular Remodeling and Stunning At Transmural Acute Myocardial Infarction

Kenjaev S.R. MD, Alyavi A.L. MD, Alimov D.A. MD, Abdijalilova S.I. MD

Republican Research Center of Emergency Medicine, Tashkent, Uzbekistan

*Corresponding Author:

Babur Shakirov

Email: baburshakirov@yahoo.com

Abstract: The research included 120 patients with acute myocardial infarction with ST-segment elevation, who underwent reperfusion. It has been revealed, that in AMI + ST ischemic myocardial damage are not the same, and there are areas of reversible left ventricular dysfunction, along with the irreversible necrosis. An effective reperfusion during AMI + ST always accompanies by reperfusion injury and the development of "stunned" myocardium. Restoring asynergic contractility of myocardium under stress echocardiography with small doses of dobutamine, determines the improvement of global systolic function and left ventricular remodeling. Reperfusion resulted in a decrease the frequency of signs of heart failure and cardiac arrhythmias in patients with transmural myocardial infarction.

Keywords: acute myocardial infarction, reperfusion, "stunned" myocardium, remodeling.

INTRODUCTION

Restoration of blood flow in the infarct-related coronary artery (IRCA) should help to reduce mortality and the incidence of complications of AMI. At the present, it has been proven the importance of coronary artery occlusion in the pathogenesis of acute myocardial infarction (AMI). Restoration of coronary blood flow should help: 1) To limit the size of myocardial infarction; 2) To reduce the incidence of life-threatening arrhythmias; 3) To prevent dilatation of the damaged myocardial areas and formation of aneurysms; 4) To prevent enlargement of the heart chambers due to the intact parts of the myocardium (pathological remodeling of the LV myocardium), 5) To reduce mortality of acute myocardial infarction [1, 2, 3].

Numerous studies have shown the high efficiency of transluminal balloon angioplasty (TBA) in restoring the blood flow in IRCA and improvement in prognosis during acute myocardial infarction. The mechanism of improvement in the clinical outcome after treatment with TBA appears multifactorial. The main reason for the favorable clinical course and improvement of the prognosis of the disease is the early (in the first hours of the disease) restoration of antegrade blood flow TIMI 2-3 in IRCA, making possible to significantly improve the blood supply to the surrounded area of infarction and to limit the zone of necrosis [4, 5, 6, 7, 8, 9, 10].

The purpose of the study was to define the clinical course, remodeling, stunned myocardium and dynamics of the recovery of left ventricular dysfunction

after adequate reperfusion therapy in patients with acute myocardial infarction with ST segment elevation.

MATERIAL AND METHODS

The study included 120 patients with acute myocardial infarction with ST-segment elevation. The average age was $44,2 \pm 1,3$ years. Patients admitted to the CCU Republican research center of emergency medicine (RRCEM) in the first 8 hours after the development of the disease. All patients underwent standard treatment (anticoagulants, antiplatelet agents, statins, β -blockers, nitrates, ACE inhibitors). Thrombolytic therapy (TLT) was conducted in 44%, and primary PCI – in 56% of patients.

Urgent reperfusion therapy performed in 120 patients, with 96 (80%) effectiveness. In 24 (20%) patients reperfusion did not give the effect. It should be noted that in half of cases IRCA's permeability was verified with emergent coronary angiography (TIMI 2, 3). Time of IRCA's reperfusion - $5,5 \pm 3,2$ h. The patients were divided into two groups: 1st - 96 (80%) patients with successful reperfusion (SR) and the 2nd - 24 (20%) patients without successful myocardial reperfusion (without SR).

All 120 patients underwent echocardiography (after reperfusion and after 3 months) and stress echocardiography with low doses of dobutamine (SDE) on the 4-6-th day after the stabilization of the patient. Two-dimensional echocardiography was performed on the machines "Siemens Omnia" (Germany) and ClearVue 550 (Philips), were determined in end-diastolic and end-systolic volume (EDV and ESV), stroke and

minute volume (SV and MV) and ejection fraction (EF) of LV.

Protocols of the stress echocardiography include certain growth of LV systolic wall thickening in areas dyssynergia on small doses of the drug [12].

Dobutamine was administered by automatic infusomats by the conventional scheme. Simultaneously echocardiography by monitoring of global and regional left ventricular myocardial contractility, ECG and blood pressure and the heart rate monitor using a Nihon (Japan) was performed.

Table 1: The clinical characteristics of examined patients with AMI

	Total (n=120)	1 st group (n=96)	2 nd group (n=24)
Age	44,2 ± 1,3	43,2 ± 1,6	44,8 ± 1,3
Men	92 (76,7%)	71	21
the time "symptom - reperfusion"	5,5 ± 3,2 h	2,2 ± 1,3	6,4 ± 3,2*
Thrombolytic therapy	53 (44%)	37	16
Primary PCI	67 (56%)	59	8
Rescue PCI	5	3	2
Delayed PCI	42	28	14
ST segment lowering from baseline over 50%	96 (80%)	96	-
the absence of ST segment lowering from baseline over 50%	24 (20%)	-	24
TIMI 0	18 (15%)	-	18
TIMI 1	6 (5%)	-	6
TIMI 2	45(37,5%)	45	-
TIMI 3	51 (42,5%)	51	-

*P<0,05.

Regional contractile function of the LV was evaluated according to the classification of LV segmental division, proposed by the American Society of Echocardiography. Analysis of violation of local contractility of the left ventricular myocardium in 16 segments before and during tests conducted by 4-point scale: normokinesis - 1 point, hypokinesis - 2 points, akinesia - 3 points and dyskinesia - 4 points [5, 8]. Further, the index is calculated wall motion score index (WMSI) as the ratio of the total points of the analyzed segments to their total number. The criterion of viability (reversible dysfunction) according myocardial stress echocardiography was the appearance of a zone of myocardial scar formed as increase its contractility by one point or more and increase in systolic thickening >3 mm at small doses of dobutamine (5-10 mg / kg / min).

Statistical analysis was carried out using Statistica-5,0. In the analysis of the material were calculated average values, their average standard errors and confidence intervals of 95%. The hypothesis of equality of means was evaluated by t criteria of Student. The statistical differences between samples were set at <0.05.

RESULTS

When analyzing the results of the clinical studies on patients a reperfusion therapy had a positive impact of on the clinical course of AMI. Patients expressed significantly positive impact on the incidence of revascularization of cardiac arrhythmias, as well as morphological and functional status of the left ventricle and the development of heart failure.

ALVF class III and IV of Killip occurred mainly among patients without successful reperfusion (10 and 18% vs. 6, and 8%).

The complications such as life-threatening heart rhythm and conduction also often detected in patients without successful reperfusion (Fig.1). In these patients often developed left ventricular aneurysm. One patient died on the 5th day of AMI as a result of recurrent MI and the outer myocardial rupture, which belongs to the category of patients without successful reperfusion. It should be emphasized that the rate of observed complications generally corresponds to their occurrence in the general population of patients with acute myocardial infarction [11,12].

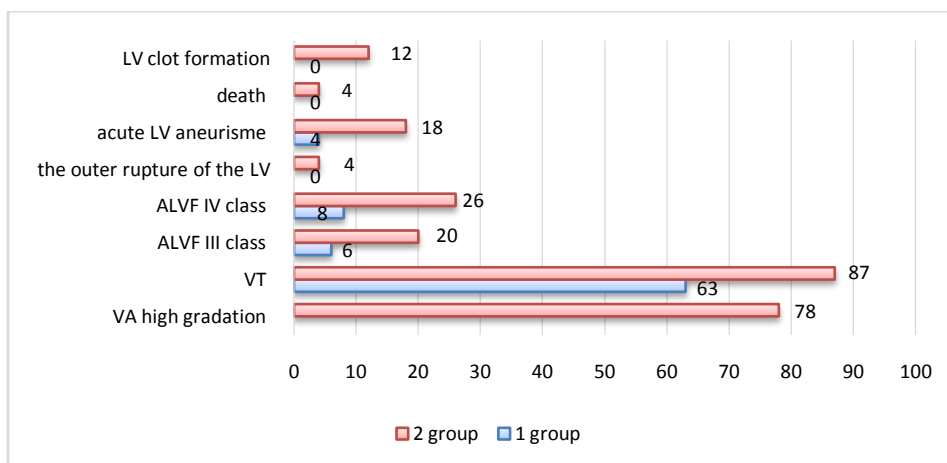


Fig. 1: The clinical course of acute transmural myocardial infarction in patients with successful and unsuccessful reperfusion

During the two-dimensional echocardiography at rest in the first days after myocardial reperfusion in patients of both groups had moderate dilatation of the LV cavity and reduction in global left ventricular systolic function. LV end-diastolic volume in the 1 and 2-group was $163,3 \pm 1,3$ and $164,8 \pm 1,1$ ml ($p > 0,05$). The index of global systolic function, left ventricular ejection fraction was reduced in both groups up to $46,5 \pm 0,5$ and $47,3 \pm 0,3\%$.

For qualitative analysis of segmental LV contractility was studied in 1920 segments. Area asynergia infarction was detected in 40% of segments of the left ventricle in patients with SR (of which 28% and 12%, hypokinesia/akinesia). WMSI amounted to $1,6 \pm 0,05$. Asynergia infarction was detected in 52% of segments in the group of patients without SR (of which 34% hypokinesia, akinesia 10% and dyskinesia 8%). WMSI of patients without SR was $2,0 \pm 0,04$. Indicators of general and regional systolic function in the Table 2.

During the correlation analysis revealed reverse correlation between the degree of growth and EDV LV sphericity index in the 1st and 12th day of MI ($r = -0,4$, and $r = -0,44$; $p < 0,01$). In other words, it was found that patients with anterior localization of AMI who received reperfusion therapy effective expansion of LV associated with the growth of its sphericity.

In the 4-6 th day of the disease on echocardiographic indices of central hemodynamics and regional systolic function did not differ. When conducting stress echocardiography with small doses of dobutamine in patients with SR revealed an increase in the number of segments with normokinesis to 92% reduction in area up to 5% of hypokinesia, akinesia areas also disappeared to 3%. WMSI significantly decreased to $1,1 \pm 0,04$ ($p < 0,001$). Accordingly noted improvement in the global LV systolic function with the introduction of low-dose dobutamine, although end-diastolic indices did not change significantly ($p > 0,05$). Total EF increased from $46,5 \pm 0,5$ to $55,4 \pm 0,6\%$ ($p < 0,001$).

Table 2: The data of echocardiography and stress echocardiography with low dose dobutamine

Rate	After reperfusion		Lowdoses of dobutamine		3 months after MI	
	1 gr, n=96	2 gr, n=24	1 gr, n=96	2 gr, n=24	1 gr, n=96	2 gr, n=23
EDV LV, ml	$163,3 \pm 1,3$	$164,8 \pm 1,3$	$163,5 \pm 1,5$	$166,4 \pm 1,5$	$164 \pm 1,6$	$168 \pm 1,6$
ESV LV, ml	$87,4 \pm 1,3$	$86,5 \pm 1,2$	$73 \pm 1,16^*$	$85,5 \pm 1,16^*$	$76,7 \pm 1,12$	$87,7 \pm 1,2^{\wedge}$
EF LV, %	$46,5 \pm 0,5$	$43,5 \pm 0,5$	$55,4 \pm 0,6$	$45 \pm 0,6$	$53,2 \pm 0,5$	$44 \pm 0,6$
WMSI	$1,6 \pm 0,05$	$1,77 \pm 0,04$	$1,1 \pm 0,04^*$	$1,63 \pm 0,04^*$	$1,1 \pm 0,04^*$	$1,7 \pm 0,06^{\wedge}$
Normokinesis	461-60%	92-48%	707-92%	149-77%	698-91%	138-72%
Hypokinesia	215-28%	66-34%	38-5%	20-10%	40-5%	23-12%
Akinesia	92-12%	19-10%	23-3%	8-5%	30-3%	16-8%
Dyskinesia	-	15-8%	-	15-8%	-	15-8%

Note: * - $p < 0,05$ compared with initial data; \wedge - $p < 0,05$ between groups

When conducting a stress echocardiography with dobutamine in low doses in patients without SR

increasing the number of identified segments normokinesis to 77% decrease in area to 10%

hypokinesia, akinesia zone to 5%. In this group dyskinetic segments when administered at baseline and low dose dobutamine was 8%. WMSI is not changed significantly by administered of low doses of dobutamine. It was also nonsignificant improvement in global left ventricular systolic function with the introduction of low-dose dobutamine, although end-diastolic indices did not change significantly ($p > 0.05$).

Conducting stress echocardiography with low doses of dobutamine revealed that left ventricular myocardial dysfunction in 8% of the segment was irreversible (necrosis), and 32% - reversible (stunned myocardium) in patients undergoing successful revascularization.

In patients without a successful reperfusion reversible myocardial dysfunction was detected in 29% of segments irreversible - 23%.

After 3 months performed repeated echocardiography at rest. In the group of patients with successful reperfusion of the myocardium revealed a significant decrease of hypokinesia zones in comparison with the baseline data from 28 to 5.2%, the number of normokinetic segment increased from 60 to 90.8%.

Improved contractility zones hypokinesia noted in areas which had been diagnosed reversible myocardial dysfunction (stunned myocardium) during stress echocardiography with low doses of dobutamine in the 4-6 th day of the disease. WMSI amounted to $1,12 \pm 0,04$ ($p < 0.01$). It was also noted improvement in the global LV systolic function. LVEF increased significantly from $46,5 \pm 0,5$ to $53,2 \pm 0,5\%$ ($p < 0.05$).

In the group of patients without successful myocardial reperfusion on the 3 months revealed hypokinesia reduction in areas from 34 to 12%, the number of normokinetic segment grew from 48 to 72%. WMSI amounted to $1,52 \pm 0,06$ ($p < 0.05$). LVEF not increased significantly ($p > 0.05$).

Direct correlation was found between the number of segments of dobutamine response and the value of their functional improvement at peak dobutamine and changes in ejection fraction ($r = 0.72$, $p < 0.01$). Also, found a direct correlation between WMSI at low dose dobutamine EchoCG at 4-6 days and echocardiography after 3 month ($r = 0,91$, $p < 0.01$). Noted the positive dynamics of the functional state of left ventricular myocardium in all patients Q myocardial infarction with reversible myocardial dysfunction.

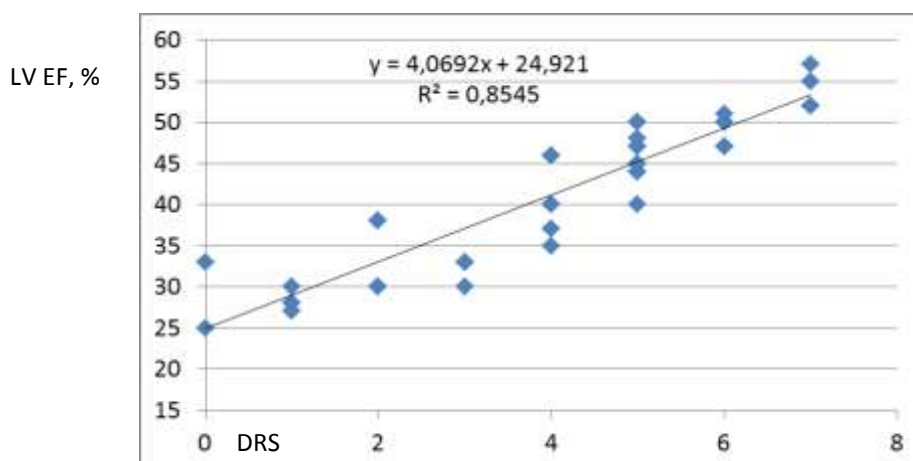


Fig.2: Direct positive correlation between dobutamine responds segments (DRS) and LVEF ($p < 0,05$)

The absence of myocardial stanning in the area of myocardial infarction was accompanied by more severe of restorative postinfarction period. In the presence of myocardial stanning after stenting of IRCA remodeling processes were less pronounced.

Until recently, the violation of the contractile function of the myocardium in acute myocardial infarction is uniquely associated with a local necrosis of cardiomyocytes. However, violations of local myocardial contractility are not always the result of myocardial necrosis. Numerous functional and morphological studies have shown that ischemic damage to the myocardium is not uniform.

Many studies have demonstrated that early reperfusion in acute myocardial infarction + ST elevation has a positive effect on systolic LV function by limiting the further loss of cardiomyocytes, even though after reperfusion and reoxygenation a condition of stunned myocardium is developing in ischemic areas, and therefore the LV systolic function is reduced [5, 6, 7,9]. To restore the contractility of these stunned myocardium areas a certain time is needed. L. A. Reduto et al. [9] found that in patients after intracoronary administration of streptokinase, LVEF does not increased significantly immediately after reperfusion, but only in time of hospital discharge. W. G. Schmidt et al. [11] surveyed 264 patients with acute myocardial infarction, have detected a slight improvement in LV

systolic function in reperfused region in the first 3 days and significant increase in its pro-intervals of between 3 days and 6th months. B.I. Zaret et al. [13] in a large group of patients with acute myocardial infarction found marked improvement of LVEF in the 9-day and the next 6 weeks after thrombolytic therapy. In our studies of myocardial functional recovery and a significant increase in ejection fraction from $46,5 \pm 0,5$ to $53,2 \pm 1,3\%$ ($p < 0.01$) occurred on the 12th day of the disease, (although the 4-6th day did not differ from baseline EF) that can be associated with improvements in left ventricular systolic function by restoring contractility in stunning areas of the myocardium on the background of the therapy for 12 days. Functional recovery of LV myocardium coincides with clinical improvement.

CONCLUSIONS

In acute transmural MI ischemic myocardial damage are not homogeneous, there are areas of reversible left ventricular dysfunction, along with the irreversible necrosis, which largely determine a violation of the functional state of the myocardium. An effective early myocardial reperfusion in patients with STEMI always accompanies by reperfusion injury and the development of "stunned" myocardium.

Functional recovery of left ventricular myocardium in patients with STEMI, who underwent an early revascularization does not occur immediately, but happens after a certain period of time (in this study within 3 months). Restoring of contractility in asynergic myocardium under stress echocardiography with small doses of dobutamine determines the improvement of global LV systolic function in patients with STEMI.

Reperfusion therapy has a positive effect on the clinical course of the disease by reducing the frequency of signs of heart failure and heart rhythm disturbances in patients with transmural myocardial infarction.

REFERENCES

1. Litvitskii, P. F., Sandrikov, V. A., & Demurov, E. A. (1994). Adaptive and Pathogenic Effects of Reperfusion and Reoxygenation of the Myocardium. *Meditsina, Moscow*.
2. Ferrari, R. (1997). Left ventricular dysfunction after myocardial infarction: a stunning, hibernation and reconstruction. *Medicography*, 53-57.
3. Chen, C., Ma, L., Linfert, D. R., Lai, T., Fallon, J. T., Gillam, L. D., ... & Tsongalis, G. J. (1997). Myocardial cell death and apoptosis in hibernating myocardium. *Journal of the American College of Cardiology*, 30(5), 1407-1412.
4. Franzosi, M. G., Santoro, E., De Vita, C., Geraci, E., Lotto, A., Maggioni, A. P., ... & Tognoni, G. (1998). Ten-Year Follow-Up of the First Megatrial Testing Thrombolytic Therapy in Patients With Acute Myocardial Infarction Results of the Gruppo Italiano per lo Studio della Sopravvivenza nell'Infarto-1 Study. *Circulation*, 98(24), 2659-2665.
5. LaCanna, G., Rahimtoola, S. H., Visioli, O., Giubbini, R., Alfieri, O., Zognio, M., ... & Ferrari, R. (2000). Sensitivity, specificity, and predictive accuracies of non-invasive tests, singly and in combination, for diagnosis of hibernating myocardium. *European heart journal*, 21(16), 1358-1367.
6. Marchese, A., Galiuto, L. E. O. N. A. R. D. A., Cavallari, D., Illiceto, S., & Rizzon, P. (1994). The protective effect of coronary collateral circulation on myocardial viability: a case of acute coronary occlusion. *Cardiologia (Rome, Italy)*, 39(5), 359.
7. Morgan, J. P., Erny, R. E., Allen, P. D., Grossman, W., & Gwathmey, J. K. (1990). Abnormal intracellular calcium handling, a major cause of systolic and diastolic dysfunction in ventricular myocardium from patients with heart failure. *Circulation*, 81(2 Suppl), III21-32.
8. Palojoki, E., Saraste, A., Eriksson, A., Pulkki, K., Kallajoki, M., Voipio-Pulkki, L. M., & Tikkanen, I. (2001). Cardiomyocyte apoptosis and ventricular remodeling after myocardial infarction in rats. *American Journal of Physiology-Heart and Circulatory Physiology*, 280(6), H2726-H2731.
9. Reduto, L. A., Smalling, R. W., Freund, G. C., & Gould, K. L. (1981). Intracoronary infusion of streptokinase in patients with acute myocardial infarction: effects of reperfusion on left ventricular performance. *The American journal of cardiology*, 48(3), 403-409.
10. Smart, S. C., Knickelbine, T., Stoiber, T. R., Carlos, M., Wynsen, J. C., & Sagar, K. B. (1997). Safety and accuracy of dobutamine-atropine stress echocardiography for the detection of residual stenosis of the infarct-related artery and multivessel disease during the first week after acute myocardial infarction. *Circulation*, 95(6), 1394-1401.
11. Schmidt, W. G., Sheehan, F. H., von Essen, R., Uebis, R., & Effert, S. (1989). Evolution of left ventricular function after intracoronary thrombolysis for acute myocardial infarction. *The American journal of cardiology*, 63(9), 497-502.
12. Smart, S. C., Sawada, S., Ryan, T., Segar, D., Atherton, L., Berkovitz, K., ... & Feigenbaum, H. (1993). Low-dose dobutamine echocardiography detects reversible dysfunction after thrombolytic therapy of acute myocardial infarction. *Circulation*, 88(2), 405-415.
13. Zaret, B. L., Terrin, M. L., Ross, R., Weiss, M., Slater, J., Morrison, J., ... & TIMI Investigators. (1992). Assessment of global and regional left ventricular performance at rest and during exercise after thrombolytic therapy for acute myocardial infarction: results of the Thrombolysis in Myocardial Infarction (TIMI) II Study. *The American journal of cardiology*, 69(1), 1-9.