

Original Research Article

Isolation and Identification of *Corynebacterium pseudotuberculosis* in Reproductive Organs and Pituitary Gland of Goats Vaccinated with Prototype Vaccine against Caseous Lymphadenitis

Muhammad Umer^{1,2}, Yusuf Abba³, Faez Firdaus Jesse Abdullah^{1*}, Wessam Monther Mohammed Saleh^{1,4}, Abdul Wahid Haron¹, Abd Aziz Saharee¹, Arbakaria Bin Ariff⁵

¹Department of Clinical Studies, Faculty of Veterinary Medicine, Universiti Putra Malaysia, 43400 UPM, Serdang, Selangor, Malaysia

²Department of Animal Reproduction, Lasbela University of Agriculture, Water and Marine Sciences, Uthal, Pakistan

³Department of Pathology and Microbiology, Faculty of Veterinary Medicine, Universiti Putra Malaysia, 43400 UPM, Serdang, Selangor, Malaysia

⁴Department of Internal and Preventive Medicine, Faculty of Veterinary Medicine, University of Basra, Basra State, Iraq

⁵Department of Bioprocess Technology, Faculty of Biotechnology and Biomolecular Sciences, Universiti Putra Malaysia, 43400 UPM, Serdang, Selangor, Malaysia

*Corresponding Author:

Faez Firdaus Jesse Abdullah

Email: jesseariasamy@gmail.com

Abstract: *Corynebacterium pseudotuberculosis* is the causative agent of caseous lymphadenitis (CLA) in small ruminants. This study was designed to evaluate the efficacy of 0.5% and 1% formalin killed prototype vaccine of *C. pseudotuberculosis* in bucks and does. A total of 24 healthy bucks and does were equally divided into four groups of 6 animals. Groups A and B were vaccinated with 0.5% and 1% formalin killed prototype vaccine and groups C and D were kept as positive (+) and negative (-) control groups, inoculated with plain vaccine adjuvant. After booster vaccination at the 6th week, groups A, B and C were experimentally inoculated with 2mL of 10⁶ cfu of live *C. pseudotuberculosis* subcutaneously. On the 12th week, all animals were euthanized and samples of reproductive organs and pituitary glands of both bucks and does were collected. Bacterial isolation and identification was done on the basis of morphological characteristics and PCR detection. Based on the bacterial culture results, 3 samples each were Positive for *C. pseudotuberculosis* colonies from bucks in groups A and B, while 4 samples were positive from does in group A and only 1 from does in group B. All bucks and does from groups A and B showed negative PCR amplifications in all samples. This study showed that 1% formalin killed prototype vaccine of *C. pseudotuberculosis* is effective in preventing the spread of the bacteria to the reproductive organs and pituitary glands of both bucks and does. Thus, it will be a suitable preventive measure against CLA in small ruminants.

Keywords: Bacterial identification, Reproductive organs, Pituitary, Prototype Vaccine, *C. pseudotuberculosis*.

INTRODUCTION

Caseous lymphadenitis is a chronic disease of small ruminants worldwide caused by *C. pseudotuberculosis* [1, 2]. *C. pseudotuberculosis* is an intracellular, non-spore forming, gram positive, and facultative and small curved rod bacterium. It comprises of mycolic acid, which is related to the development of abscesses in various mammals [3-5]. It is a chronic disease of ovine and caprine husbandries, characterized by formation of abscesses in the superficial and internal lymph nodes [6, 7]. The transmission of this disease occurs through release of large number of bacteria from ruptured abscess, which spreads over the skin and fleece of infected animals and also the environment. Other animals may be exposed either via direct physical contact with the infected animal or indirectly

through contaminated fomites [8]. Once the disease has been established in a herd, it becomes puzzling for veterinarians to eradicate due to its ineffectiveness to antibiotic treatments [7, 9, 10]. Vaccination to livestock herds is the most reliable strategy for controlling and eradicating this disease [11, 12]. However, the limitations of this procedure hinders on the accuracy of appropriate diagnostic procedures [5, 7, 13]. Several serological tests for CLA diagnosis have been proposed; including a synergistic haemolysis inhibition test [14], complement-fixation test [15] micro-agglutination assay [16] and *C. pseudotuberculosis* phospholipase D (PLD) antigen-based ELISA [17]. Such type of tests may have great value in detecting animals sub-clinically infected with CLA. The limitations of these tests are low sensitivity, specificity

and an inability to differentiate between the previously infected herd and those that still harbour the pathogen. Thus, this raises the question on the relevance of these techniques and if they can be used in culling programs to eliminate infected and suspected animals [7, 18]. Culture identification of *C. pseudotuberculosis* is more often than not proficient through biochemical tests but repeatedly challenging due to the general unpredictability of the bacteria in biochemical appearances [18, 19]. Recently, 16S rRNA gene has been utilized in PCR detection for the identification of *C. pseudotuberculosis* from cultured isolates [18]. While PCR was very sensitive in assessing the prevalence of CLA in infected animals, it had some limitations: (a) it was reliant on bacterial culture (b) it was incapable in differentiating *C. pseudotuberculosis* from *C. ulcerans* [18]. Therefore, the aim of this present study was to determine the efficacy of a formalin killed prototype whole cell vaccine of *C. pseudotuberculosis* against spread of the bacteria in the reproductive organs and pituitary glands of goats.

MATERIALS AND METHODS

Ethical Statement

The experimental procedures was approved by the Institutional Animal Care and Use Committee (IACUC), V (Ref No: UPM/IACUC/AUP-R060/2014), Universiti Putra Malaysia as required in Malaysia by the Animal Welfare Act (2014). All animals were humanely handled and euthanized using stipulated guidelines.

Experimental design and management

Twenty four healthy male and female goats were divided into four groups; A, B, C and D, comprising of 3 bucks and 3 does each. The goats were acclimatized for two weeks prior to the commencement of the experiment and were feed with locally prepared goat pallet (250g/animal/day). In addition, the goats were also fed Napier grass twice daily, while water was provided ad libitum.

Preparation of prototype vaccine of *Corynebacterium pseudotuberculosis*

An identified colony of *C. pseudotuberculosis* was inoculated into flask containing 250 mL of brain heart infusion broth with 1.0% Tween-80 and incubated in a plate shaker plate for 18-24 hours at 37°C. The inoculum was then centrifuged (6000 rpm for 15 minutes, at 4°C) and the supernatant were discarded. The bacterial sediment was washed thrice with 50% and 100% acetone, and 100% diethyl ether. Thereafter, the bacterial sediment was left to air-dry and then divided into two equal parts which were suspended in 0.5% and 1.0% formalin solution mixed with 4% Tween 80 (v/v). The suspensions were kept overnight at room temperature until further use [11].

Vaccine inoculation and challenging

At the 1st week of the experiment, groups A and B were inoculated with 2mL of 0.5% and 1%

formalin killed whole cell vaccine of *C. pseudotuberculosis* intramuscularly at the hind limbs with fraction doses according to Sigma Adjuvant System®. Similarly, group C and D were injected with 2mL of plain adjuvant and kept as positive and negative control groups. Booster dose of the vaccine and adjuvant was injected at the 3rd week of the experiment.

Preparation of inoculum for *Corynebacterium pseudotuberculosis*

C. pseudotuberculosis colony isolated from previously cultured case of an outbreak of clinical CLA among goats at Universiti Putra Malaysia was used for preparation of the inoculum in this study. The isolated pathogen was sub-cultured on blood agar at 37°C for 24-48 hours. The challenge doses with a concentration of 1×10^6 cfu/ml were prepared and determined using the McFarland Standard technique. Groups A, B, and C were challenged with 2mL of live *C. pseudotuberculosis* subcutaneously, while group D served as the negative control and was not inoculated.

Samples collection and Culture

Twelve weeks post inoculation with *C. pseudotuberculosis*, all goats were euthanized for sample collection. Samples of the reproductive organs from male (testes, epididymis, spermatic cord, penis and pituitary glands) and females (ovary, fallopian tube, uterus, vagina, vulva and pituitary gland) animals were collected. Swab samples were taken from all samples and cultured onto labelled petri dishes containing blood agar and incubated at 37°C for 24 to 48 hours. Suspected culture of *C. pseudotuberculosis* having similar colony characteristic like small, white, dry and crumbly colonies were sub-cultured again onto a new blood agar. One colony culture from each organ was subjected to bacterial identification using PCR.

Primer Design and PCR Amplification

Previously published primer sets were used for the amplification of *C. pseudotuberculosis* [18]. The primer for forward was 5'CCGCACTTTAGTGTGTGTG'3 and for reverse primer 5'TCTCTACGCCGATCTTGTAT'3 were used. The primers targeted the specific regions of *C. pseudotuberculosis* and length of the PCR product was 815 base pairs. DNA extraction was done using DNAzol as previously described. The PCR was performed in a touchdown thermocycler (SensoQuest, Biomedical Electronic, Germany) in a total reaction volume of 50µL. The amplification was obtained with 30 cycles following an initial denaturation step at 94°C for 5 min. Each cycle involved denaturation at 94°C for 1 min, annealing at 56°C for 1 min, and synthesis at 72°C for 2 min. The PCR product was loaded onto a 1% agarose gel and ran at 100 V for 45 min. Positive bands were observed using a UV transluminator.

RESULTS

Identification of Suspected Bacterial cultures with *Corynebacterium pseudotuberculosis* Male reproductive organs and pituitary gland

A total of 144 samples were collected from different reproductive organs of all experimental groups. However, only 4 samples from group A were positive for bacterial culture; right head of epididymis (1/3), Left testis (1/3), left head of epididymis (1/3) and

pituitary gland (1/3). . Similarly, 3 bacterial cultures from group B indicated the same colony morphological characteristics of *C. pseudotuberculosis*; right head of epididymis (1/3), left testis (1/3) and tail of epididymis (1/3). From group C, the least number of positive culture identification was seen in the left tail of the epididymis where only one animal had a positive growth. (Table 1).

Table-1: Culture results from reproductive organs and pituitary gland of bucks vaccinated with prototype vaccine of *Corynebacterium pseudotuberculosis*

Organ/Tissue	Treatment groups											
	A			B			C			D		
	A1	A2	A3	A1	A2	A3	A1	A2	A3	A1	A2	A3
Right testis	-	-	-	-	-	-	+	+	+	-	-	-
Right head of epididymis	-	-	-	-	-	+	+	+	+	-	-	-
Right body of epididymis	-	+	-	-	-	-	-	+	+	-	-	-
Right tail of epididymis	-	-	-	-	-	-	+	+	+	-	-	-
Right spermatic cord	-	-	-	-	-	-	+	+	+	-	-	-
Left testis	-	-	+	+	-	-	+	+	+	-	-	-
Left head of epididymis	+	-	-	-	-	-	+	+	+	-	-	-
Left body of epididymis	-	-	-	-	-	-	+	-	+	-	-	-
Left tail of epididymis	-	-	-	-	-	+	-	-	+	-	-	-
Left Spermatic cord	-	-	-	-	-	-	+	-	+	-	-	-
Penis	-	-	-	-	-	-	+	+	-	-	-	-
Pituitary gland	-	-	+	-	-	-	+	+	+	-	-	-

Treatment groups: A: vaccinated with 0.5% formalin killed vaccine; B: vaccinated with 1.0% formalin killed vaccine; C: control (+); D: control (-)

A: Animal numbers, - : negative culture samples of *C. pseudotuberculosis*, +: positive culture samples of *C. pseudotuberculosis*

Female reproductive organs and pituitary gland

156 samples were collected from the does and cultured on 10% blood agar. Culture samples were thoroughly checked after 24 and 48 hours of incubation. Group A had four positive samples from right ovary

(1/3), right horn (2/3) and left mammary gland (1/3). However, only one sample from the cervix showed positive culture in group B. (Table 2). All cultured samples of group C were positive, with the vulva having the least (1/3) number of positive culture.

Table-2: Culture results from reproductive organs and pituitary gland of does vaccinated with prototype vaccine of *Corynebacterium pseudotuberculosis*

Organ/Tissue	Treatment groups											
	A			B			C			D		
	A1	A2	A3	A1	A2	A3	A1	A2	A3	A1	A2	A3
Right ovary	+	-	-	-	-	-	+	+	+	-	-	-
Right fallopian tube	-	-	-	-	-	-	+	+	+	-	-	-
Right horn	+	-	+	-	-	-	+	-	+	-	-	-
Left ovary	-	-	-	-	-	-	+	+	+	-	-	-
Left fallopian tube	-	-	-	-	-	-	+	+	-	-	-	-
Left horn	-	-	-	-	-	-	+	+	+	-	-	-
Uterus	-	-	-	-	-	-	+	+	+	-	-	-
Cervix	-	-	-	-	+	-	-	+	+	-	-	-
Vagina	-	-	-	-	-	-	+	+	+	-	-	-
Vulva	-	-	-	-	-	-	-	-	+	-	-	-
Left mammary gland	-	+	-	-	-	-	+	+	+	-	-	-
Right mammary gland	-	-	-	-	-	-	-	+	-	-	-	-
Pituitary gland	-	-	-	-	-	-	+	+	-	-	-	-

Treatment groups: A: vaccinated with 0.5% formalin killed vaccine; B: vaccinated with 1.0% formalin killed vaccine; C: control (+); D: control (-), A: Animal numbers, - : negative culture samples of *C. pseudotuberculosis*, + : positive culture samples of *C. pseudotuberculosis*

Identification of suspected cultures with *Corynebacterium pseudotuberculosis* applying PCR Male reproductive organs and pituitary gland

Based on the PCR amplification, both groups A and B were negative for *C. pseudotuberculosis* from

all organs/tissues examined. However, group C showed positive amplification in all tissues except the left epididymal tail (Table 3; Figure 1).

Table-3: Molecular detection of *Corynebacterium pseudotuberculosis* in the reproductive organ and pituitary gland of bucks vaccinated with prototype vaccine of *Corynebacterium pseudotuberculosis*

Organ/Tissue	Treatment groups											
	A			B			C			D		
	A1	A2	A3	A1	A2	A3	A1	A2	A3	A1	A2	A3
Right testis	-	-	-	-	-	-	+	+	+	-	-	-
Right head of epididymis	-	-	-	-	-	-	+	+	+	-	-	-
Right body of epididymis	-	-	-	-	-	-	-	-	+	-	-	-
Right tail of epididymis	-	-	-	-	-	-	+	+	+	-	-	-
Right spermatic cord	-	-	-	-	-	-	+	-	+	-	-	-
Left testis	-	-	-	-	-	-	+	+	+	-	-	-
Left head of epididymis	-	-	-	-	-	-	+	+	+	-	-	-
Left body of epididymis	-	-	-	-	-	-	-	-	+	-	-	-
Left tail of epididymis	-	-	-	-	-	-	-	-	-	-	-	-
Left Spermatic cord	-	-	-	-	-	-	+	-	+	-	-	-
Penis	-	-	-	-	-	-	+	+	-	-	-	-
Pituitary gland	-	-	-	-	-	-	+	+	+	-	-	-

Treatment groups: A: vaccinated with 0.5% formalin killed vaccine; B: vaccinated with 1.0% formalin killed vaccine; C: control (+); D: control (-), A: Animal numbers, - : not detected samples for *C. pseudotuberculosis*, +: detected samples for *C. pseudotuberculosis*

Female reproductive organs and pituitary gland

Based on the PCR amplification results, tissues from all does in groups A and B were negative for *C. pseudotuberculosis*. However, positive amplifications

were observed in all tissues of goats in group C, with the least number of positive amplification in the vulva (1/3) (Table 4; Figure 2).

Table-4: Molecular detection of *Corynebacterium pseudotuberculosis* in the reproductive organ and pituitary gland of does vaccinated with prototype vaccine of *Corynebacterium pseudotuberculosis*

Doe's reproductive organs	Treatment groups											
	A			B			C			D		
	A1	A2	A3	A1	A2	A3	A1	A2	A3	A1	A2	A3
Right ovary	-	-	-	-	-	-	+	+	+	-	-	-
Right fallopian tube	-	-	-	-	-	-	+	+	-	-	-	-
Right horn	-	-	-	-	-	-	+	-	+	-	-	-
Left ovary	-	-	-	-	-	-	+	+	+	-	-	-
Left fallopian tube	-	-	-	-	-	-	+	+	-	-	-	-
Left horn	-	-	-	-	-	-	+	+	+	-	-	-
Uterus	-	-	-	-	-	-	+	+	+	-	-	-
Cervix	-	-	-	-	-	-	-	+	+	-	-	-
Vagina	-	-	-	-	-	-	+	+	+	-	-	-
Vulva	-	-	-	-	-	-	+	-	-	-	-	-
Left mammary gland	-	-	-	-	-	-	+	+	+	-	-	-
Right mammary gland	-	-	-	-	-	-	-	+	-	-	-	-
Pituitary gland	-	-	-	-	-	-	+	+	-	-	-	-

Treatment groups: A: vaccinated with 0.5% formalin killed vaccine; B: vaccinated with 1.0% formalin killed vaccine; C: control (+); D: control (-), A: Animal numbers, - : not detected samples for *C. pseudotuberculosis*, +: detected samples for *C. pseudotuberculosis*

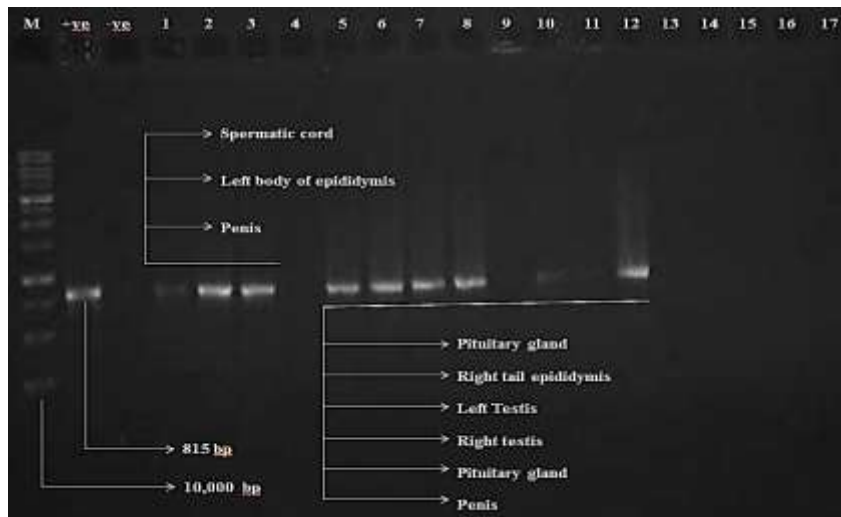


Fig-1: Agarose gel electrophoresis showing amplification of 815 bp bands specific for *Corynebacterium pseudotuberculosis* 16S RNA from reproductive organs and pituitary gland of bucks in in group C (+ve).

M: Molecular marker; Lanes +ve: positive control; Lane -ve: negative control; Lanes 1-4: culture negative, PCR negative samples; Lanes 5-13: culture positive, PCR positive samples; Lane 14-18: culture negative, PCR negative samples.




Fig-2: Agarose gel electrophoresis showing amplification of 815 bp bands specific for *Corynebacterium pseudotuberculosis* 16S RNA from reproductive organs and pituitary gland of does in group C (+ve).

M: Molecular marker; Lane +ve: positive control; Lane -ve: negative control; Lanes 1-4: culture negative, PCR negative samples; Lanes 5-13: culture positive, PCR positive samples; Lane 14-18: culture negative, PCR negative samples

DISCUSSION

Currently, no information is available regarding identification of *C. pseudotuberculosis* in reproductive organs and pituitary gland of goats following vaccination with prototype formalin killed vaccine of *C. pseudotuberculosis*. However, a few studies have reported the presence of *C. pseudotuberculosis* in the reproductive organs and inguinal lymph nodes of does following experimental challenge with *C. pseudotuberculosis* [20, 21]. The results of the presented study suggested that *C. pseudotuberculosis* was present in almost all parts of the male and female reproductive organs and pituitary gland after 90 days of inoculation. These findings

hypothesize that *C. pseudotuberculosis* has the ability to disseminate all over the body, especially the reproductive organs and pituitary. This is in agreement with Dorella, *et al.* [22], who stated that the *C. pseudotuberculosis* circulates freely in the lymphatic system throughout the body. Similarly, Abdullah, *et al.* [23], observed that the pathogenic organism can be identified from the inguinal lymph nodes and reproductive organs of female goats after 60 to 90 days of inoculation.. Latif *et al.* [20], Reported that the presence of *C. pseudotuberculosis* in all reproductive organs as well as associated lymph nodes in does indicated that the causative agent of CLA may predispose to infertility in goats. *C. pseudotuberculosis*

was observed to reach the inguinal lymph nodes after 30 day of inoculation *and* was identified from all reproduction organs after 60 and 90 days of inoculation, which was associated with infertility and non-rhythmic secretion of female reproductive hormones [24, 25]. In contrast, a study conducted by Valli and Perry (1993) reported that reproductive organs were the least often affected organs during CLA infection [26]. Furthermore, Othman *et al.* indicated that *C. pseudotuberculosis* caused hormonal imbalances in does after 30 days of inoculation, where the hormonal concentrations were similar with pseudo-pregnancy like observations [27].

This is the first of *C. pseudotuberculosis* identification from the pituitary gland of experimentally infected unvaccinated goats. This finding helps in hypothesize that *C. pseudotuberculosis* has the ability to spread all over the body, including the brain and associated pituitary gland through the circulatory system. This was confirmed in the ram, where *C. pseudotuberculosis* was isolated by Sligo from pituitary abscesses infected with caseous lymphadenitis [28]. Similarly, the change in pathological lesions induced by CLA in does was reported in the reproductive system. This together with the hormonal changes can predispose to abortion or stillbirth [29, 30]. Caseous lymphadenitis gives poor response against treatment which is expensive. Thus, immunization against the disease is the best strategy for control and prevention [12]. In this study, both bucks and does vaccinated with the prototype vaccine showed remarkable protection against *C. pseudotuberculosis*. Based on the bacterial culture results, 1% formalin killed prototype vaccine was more effective than 0.5% in both bucks and does. However, animals inoculated with both vaccine concentrations showed negative PCR amplification in all tissues. . This proves that the prototype vaccine of *C. pseudotuberculosis* has the ability to neutralize the bacteria and prevent its spread in the body. These findings support the hypothesis that the prototype vaccine prepared against CLA gives protection against transmission of the pathogen to reproductive organs and the pituitary gland. This is in contrast to the commercial—vaccine which only provides partial protection with the possibility of development of external and internal abscesses [7].

CONCLUSION

The causative agent of CLA can reach the reproductive organs and pituitary gland through the lymphatic channels in infected goats. The developed prototype vaccine from this study was able to prevent the spread of the bacteria to the reproductive organs, thus maintaining the reproductive status of the animal.

Funding

This project was funded by the Ministry of Higher Education Malaysia under the Fundamental Research Grant (No: 9419000).

Conflict of Interest

The authors have no competing interest to declare.

Author contribution

All authors contributed equally to this manuscript.

Patent Identification

This work has been filed for patent under the Registrar of Patents Registration Office Kuala Lumpur, Malaysia (PI 2017700282).

REFERENCES

1. de Sá Guimarães, A., do Carmo, F. B., Pauletti, R. B., Seyffert, N., Ribeiro, D., Lage, A. P., ... & Gouveia, A. M. G. (2011). Caseous lymphadenitis: epidemiology, diagnosis, and control. *IIOAB J*, 2, 33-43.
2. Abdullah, F. F. J., Lau, S. S., Saharee, A. A., & Shamsudin, S. (2011). Pathological changes in the organs of mice model inoculated with *Corynebacterium pseudotuberculosis* organism. *Pertanika Journal of Tropical Agricultural Science*, 34(1), 145-149.
3. Songer, J. G., Beckenbach, K., Marshall, M. M., Olson, G. B., & Kelley, L. (1988). Biochemical and genetic characterization of *Corynebacterium pseudotuberculosis*. *American journal of veterinary research*, 49(2), 223-226.
4. Peel, M. M., Palmer, G. G., Stacpoole, A. M., & Kerr, T. G. (1997). Human lymphadenitis due to *Corynebacterium pseudotuberculosis*: report of ten cases from Australia and review. *Clinical Infectious Diseases*, 24(2), 185-191.
5. Dorella, F.A., Fachin, M.S., Billault, A., Dias Neto, E., Soravito, C., Oliveira, S.C., Meyer, R., Miyoshi, A., and Azevedo, V. (2006). Construction and partial characterization of a *Corynebacterium pseudotuberculosis* bacterial artificial chromosome library through genomic survey sequencing. *Genetics and Molecular Research*. 5(4): p. 653-663.
6. Kuria, J.K., Mbuthia, P.G., Kang'ethe, E.K., and Wahome, R.G. (2001). Caseous lymphadenitis in goats: the pathogenesis, incubation period and serological response after experimental infection. *Veterinary Research Communications*. 25(2): p. 89-97.
7. Williamson, L.H. (2001). Caseous lymphadenitis in small ruminants. *Veterinary clinic of North America. Food and Animal Practic*. 17(2): p. 359-371.
8. Fontaine, M.C. and Baird, G.J. (2008). Caseous lymphadenitis. *Small Ruminant Research*. 76(1): p. 42-48.
9. Piontkowski, M.D. and Shivvers, D.W. (1998). Evaluation of a commercially available vaccine against *Corynebacterium pseudotuberculosis* for use in sheep. *Journal of the American Veterinary*

- Medical Association*. 212(11): p. 1765-1768.
10. Stanford, K., Brogden, K.A., McClelland, L.A., Kozub, G.C., and Audibert, F. (1998). The incidence of caseous lymphadenitis in Alberta sheep and assessment of impact by vaccination with commercial and experimental vaccines. *Canadian Journal of Feterinary Research*. 62(1): p. 38-43.
 11. Brown, C.C., Olander, H.J., Biberstein, E.L., and Morse, S.M. (1986). Use of a toxoid vaccine to protect goats against intradermal challenge exposure to *Corynebacterium pseudotuberculosis*. *American Journal of Veterinary Research*. 47(5): p. 1116-1119.
 12. Paton, M.W., Walker, S.B., Rose, I.R., and Watt, G.F. (2003). Prevalence of Caseous lymphadenitis and usage of Caseous lymphadenitis vaccines in sheep flocks. *Australian Veterinary Journal*. 81(1-2): p. 91-95.
 13. Menzies, P.I., Hwang, Y.T., and Prescott, J.F. (2004). Comparison of an interferon-gamma to a phospholipase D enzyme-linked immunosorbent assay for diagnosis of *Corynebacterium pseudotuberculosis* infection in experimentally infected goats. *Veterinary Microbiology*. 100(1-2): p. 129-137.
 14. Brown, C.C., Olander, H.J., and Alves, S.F. (1987). Synergistic hemolysis-inhibition titers associated with caseous lymphadenitis in a slaughterhouse survey of goats and sheep in Northeastern Brazil. *Canadian Journal of Veterinary Research*. 51(1): p. 46-49.
 15. Shigidi, M.T.A. (1979). Comparison of five serological tests for the diagnosis of experimental *Corynebacterium ovis* infection in sheep. *British Veterinary Journal*.
 16. Menzies, P.I. and Muckle, C.A. (1989). The use of a microagglutination assay for the detection of antibodies to *Corynebacterium pseudotuberculosis* in naturally infected sheep and goat flocks. *Canadian Journal of Veterinary Research*. 53(3): p. 313-318.
 17. Dercksen, D.P., Brinkhof, J.M., Dekker-Nooren, T., Maanen, K., Bode, C.F., Baird, G., and Kamp, E.M. (2000). A comparison of four serological tests for the diagnosis of caseous lymphadenitis in sheep and goats. *Veterinary Microbiology*. 75(2): p. 167-175.
 18. Cetinkaya, B., Karahan, M., Atil, E., Kalin, R., De Baere, T., and Vaneechoutte, M. (2002). Identification of *Corynebacterium pseudotuberculosis* isolates from sheep and goats by PCR. *Veterinary Microbiology*. 88(1): p. 75-83.
 19. Al-Gaabary, M.H., Osman, S.A., Ahmed, M.S., and Oreiby, A.F. (2010). Abattoir survey on caseous lymphadenitis in sheep and goats in Tanta, Egypt. *Small Ruminant Research*. 94(1): p. 117-124.
 20. Latif, N.A.A., Abdullah, F.F.J., Othman, A.M., Rina, A., Chung, E.L.T., Zamri-Saad, M., Saharee, A.A., Haron, A.W., and Lila, M.A.M. (2015). Isolation and detection of *Corynebacterium pseudotuberculosis* in the reproductive organs and associated lymph nodes of non-pregnant does experimentally inoculated through intradermal route in chronic form. *Veterinary world*. 8(7): p. 924.
 21. Othman, A.M. (2014). Reproductive Pathophysiology changes in non pregnant boer inoculated with *Corynebacterium pseudotuberculosis* VIA various routes, Universiti Putra Malaysia.
 22. Dorella, F.A., Pacheco, L.G., Oliveira, S.C., Miyoshi, A., and Azevedo, V. (2006). *Corynebacterium pseudotuberculosis*: microbiology, biochemical properties, pathogenesis and molecular studies of virulence. *Veterinary Research*. 37(2): p. 201-218.
 23. Abdullah, F.F.J., Latif, N.A.A., Chung, E.L.T., Sarah, S.A., Saad, M.Z., W., H.A., Lila, M.A.M., Zunita, Z., and Norsidin, M.J. (2015). Changes in the Reproductive Hormones of Non-Pregnant Does Infected Intradermally with *Corynebacterium pseudotuberculosis* in Chronic Form. *International Journal of Livestock Research*. 5(7): p. 33-40.
 24. Jesse, F.F.A., Adamu, L., Hazirah, N., Osman, A.Y., Mansor, R., Haron, A.W., Saad, M.Z., Omar, A.R., and Saharee, A.A. (2013). Clinical and reproductive pathological changes associated with *Brucellamelitensis* and its lipopolysaccharide in female mice via oral inoculation. *American Journal of Animal Veterinary Sciences*. 8(3): p. 104-111.
 25. Khuder, Z., Osman, A.Y., Jesse, F.F., Wahid, A., Saharee, A.A., Jasni, S., Yusoff, R., and Rasedee, A. (2012). Sex hormone profiles and cellular changes of reproductive organs of mice experimentally infected with *Corynebacterium pseudotuberculosis* and its exotoxin phospholipase D. *Journal of Agricultural Veterinary Science* 1(3): p. 24-29.
 26. Valli, V.E.O., Parry, B.W., and Jubb, K.V.F. (1993). "Caseous lymphadenitis". 4 ed. Pathology of Domestic Animals, ed. Kennedy, P.C. and Palmer, N. Vol. 3. Academic Press, San Diego, Calif, USA. 238-240.
 27. Othman, A.M., Jesse, F.F.A., Lawan, A., Abba, A., Adza, R.M.N., Saharee, A.A., Wahid, A.H., and Zamri-Saad, M. (2014). Changes in serum progesterone and estrogen concentrations in non-pregnant boer does following experimental Infection with *Corynebacterium pseudotuberculosis*. *Journal of Veternary Advances*. 4(5): p. 524-528.
 28. <http://www.agriculture.gov.ie/>.
 29. Othman, A. M., Abba, Y., Jesse, F. F. A., Ilyasu, Y. M., Saharee, A. A., Haron, A. W., ... & Lila, M. A. M. (2016). Reproductive pathological changes associated with experimental subchronic corynebacterium pseudotuberculosis infection in nonpregnant boer does. *Journal of pathogens*, 2016.

30. Latif, N. A. A., Abba, Y., Jesse, F. F. A., Chung, E. L. T., Zamri-Saad, M., Saharee, A. A., ... & Mohd-Lila, M. A. (2017). Histopathological assessment of chronic *Corynebacterium pseudotuberculosis* infection in the reproductive tract and iliac lymph node of Katjang does. *Comparative Clinical Pathology*, 26(1), 147-154.