

Recurrent Monoarthritis: A Rare Presentation of Hairy Cell LeukemiaIrushna Antonette Perera^{1*}, Thirunavukarasu Kumanan², Gunanathan Joseph Pratheepan³, Thaneswary Sooriyakumar⁴¹University medical unit, Teaching hospital Jaffna, Sri Lanka²Consultant Physician, University Medical Unit, Teaching hospital Jaffna, Sri Lanka³Consultant Physician, Teaching hospital, Jaffna, Sri Lanka⁴Consultant Haematologist, Teaching Hospital Jaffna, Sri Lanka***Corresponding author**

Irushna Antonette Perera

Article History

Received: 13.12.2017

Accepted: 25.12.2017

Published: 30.12.2017

DOI:

10.21276/sjm.2017.2.8.5



Abstract: Hairy cell leukaemia (HCL) is a rare lymphoproliferative disorder. Common mode of presentation is the sequelae of bone marrow failure and its complications. Here we report a patient with an extremely rare presentation of recurrent mono arthritis with pancytopenia which preceded months before the diagnosis of HCL, which was confirmed on a subsequent bone marrow examination. Inflammatory and degenerative aetiologies for monoarthritis were excluded. His joint related symptoms subsided on specific treatment for HCL.

Keywords: Monoarthritis, Hairy cell leukemia, Pancytopenia, splenomegaly.

INTRODUCTION

Hairy Cell Leukemia is a rare chronic lymphocytic leukemia, initially described in 1920, when it had several descriptive terms such as, leukemic reticuloendotheliosis, malignant reticulosis and lymphoid myelofibrosis. It's a clonal proliferation of abnormal B cells, which characteristically express cytoplasmic projections on their surface, giving it a "hair" like appearance. The abnormal B cells infiltrate the reticulo-endothelial system, interfering with bone marrow function, leading to bone marrow failure and pancytopenia. The common presentations are in the form of cypopenias, including anemia; infections secondary to leucopenia; bleeding secondary to thrombocytopenia; splenomegaly and its consequences.

The rare presentations include lymphadenopathy, bone pain and neurologic sequelae such as meningitis or nerve compressions. A considerable proportion of patients who are asymptomatic are diagnosed incidentally, due to increasing use of routine blood investigations. Intermittent, asymmetrical oligoarthritis have been cited in literature as an extremely rare presentation of Hairy Cell Leukemia (HCL) but not from this part of the world.

CASE PRESENTATION

A 64 year old gentleman presented with recurrent episodes of right knee joint pain and swelling of two years duration. Apart from the joint symptoms, he did not suffer from any significant medical comorbidities. On examination he was found to be pale and was having an isolated non tender splenomegaly which was moderate to firm in consistency. He also had an inflamed right knee joint with moderate effusion. It was tender to touch, but did not reveal classical clinical signs to suggest osteoarthritis, like crepitus or joint line tenderness. The range of movement was not restricted.

Initial blood investigations revealed pancytopenia with WBC $1.9 \times 10^9/L$, Neutrophils $0.32 \times 10^9/L$, Lymphocytes $1.27 \times 10^9/L$ and Monocytes $0.27 \times 10^9/L$, RBC $3.19 \times 10^9/L$, Haemoglobin 9.1g/dl, Platelets $100 \times 10^9/L$ and the blood picture revealed pancytopenia with marked rouleaux formation.

He was also found to have a very high ESR of $150\text{mm}/1^{\text{st}}\text{hour}$ and a normal CRP of 12mg/l. Ultra sound scan confirmed moderate splenomegaly. X ray of the knee joint excluded the possibility of osteoarthritis. Serum Protein Electrophoresis revealed a low level of albumin with elevated alpha 2globulin and a polyclonal gammopathy. Arthrocentesis and the joint fluid analysis done twice revealed no crystals or features of an inflammatory arthritis. His liver and renal profile was normal. The serum uric acid level was 267micromoles/L. screening work up to exclude an autoimmune cause including rheumatoid factor and ANA were negative.

The initial bone marrow aspiration was inconclusive, and a repeat bone marrow aspiration performed after 6 months revealed typical hairy cells

(Fig 1), compatible with bone marrow involvement by a chronic lympho proliferative disorder.

Flowcytometry confirmed Hairy Cell Leukemia with an abnormal B cell population that is positive for CD20, CD22, CD19, CD25, CD103,

CD123, CD23, FMC7 and CD79b and negative for CD5 and CD10.

He was referred to the medical oncology unit and was commenced on treatment with filgrastim initially for the pancytopenia and then with the biological agent Rituximab.

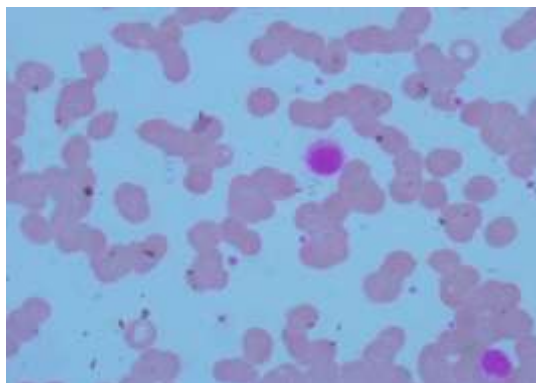


Fig-1: Bone marrow aspirate revealing typical hairy cells

DISCUSSIONS

Hairy cell leukemia is a rare, malignant disorder, characterized by an abnormal proliferation of mature B Lymphocytes, as evidenced by the presence of typical “Hairy cells”, in the peripheral blood, bone marrow and splenic red pulp. The typical “Hairy cells”, are B lymphocytes, with abundant cytoplasm, exhibiting characteristic, “Hairy” cytoplasmic projections.

Its incidence is approximately, 0.3/100 000 people, with a male preponderance, the usual age at presentation being between 50-55yrs. Children are not known to be affected[1]. The etiology is still not clearly understood, though exposure to benzenes, organophosphate insecticides or other solvents is attributed. Exposure to radiation, agro chemicals, wood dust and a previous history of exposure to infectious mononeucleosis have been postulated as associations in some studies [2].

The characteristic symptoms described in the literature are pancytopenia and splenomegaly [3]. The cytopenia results from progressive bone marrow failure, caused by a combination of leukemic infiltration, suppression of haematopoiesis by cytokines such as TNF alpha, reticulin fibrosis and also secondary to splenomegaly.

Other common symptoms that have been reported include, fatigue, weakness, infections secondary to neutropenia and bleeding tendencies secondary to thrombocytopenia. The less common presentations of Hairy cell leukemia are hepatomegaly (20%), lymphadenopathy (<10%), autoimmune phenomena (vasculitis, oligoarthritis), skeletal changes

(osteolysis), meningeal involvement and also B symptoms [4].

Here we report a very rare presentation of recurrent large joint mono arthritis, an association that has not been described before, which preceded the diagnosis of HCL over a period of two years. Traditional attributable causes for arthritis in haematological malignancies are due to hyperuricaemia and gout; immunosuppression leading to septic arthritis; and bleeding into the joints due to thrombocytopenia and coagulopathy etc. [5].

The Right knee joint mono arthritis was evaluated with joint fluid analysis and imaging which did not show characteristics of an inflammatory arthritis or an exacerbation of osteoarthritis. Immunophenotyping helps in establishing the diagnosis of Hairy cell Leukemia, and the distinctive pattern is CD5 (Negative), CD10 (Negative), CD23 (Negative), CD20 (abnormally bright), CD22 (abnormally bright), CD11c (Abnormally bright), CD25 (abnormally bright), CD103 (Positive), CD123 (Positive) [6].

A key point to note from this case report is that an unexplained chronic monoarthritis in an elderly male in the absence of classical aetiology should alert the treating clinician to think about a haematological malignancy in particular with the context of cytopenia and organomegaly. A bone marrow examination and flowcytometry would be very beneficial in such circumstances.

Declaration of conflicting interests

The author(s) declared no potential conflicts of interest with respect to the research, authorship and/ or publication of this article.

Ethical approval

Ethical approval to report this case was obtained from the Jaffna medical Faculty Ethical review committee, Sri Lanka.

Funding

The author(s) received no financial support for the research, authorship and/ or publication of this article.

Informed consent

Informed written consent was obtained from the patient for his anonymized information to be published in this article retrospectively.

REFERENCES

1. Bouroncle, B. A., Wiseman, B. K., & Doan, C. A. (1958). Leukemic reticuloendotheliosis. *Blood*, 13(7), 609-630.
2. Laurent, O. R. S. I., Delabre, L., Monnereau, A., Delval, P., Berthou, C., Fenaux, P., & Leporrier, M. (2008). Occupational exposure to pesticides and lymphoid neoplasms among men: results of a French case-control study. *Occupational and environmental medicine*.
3. Hoffman, M. A. (2006). Clinical presentations and complications of hairy cell leukemia. *Hematology/Oncology Clinics*, 20(5), 1065-1073.
4. Wanko, S. O., & de Castro, C. (2006). Hairy cell leukemia: an elusive but treatable disease. *The oncologist*, 11(7), 780-789.
5. Morais, S. A., du Preez, H. E., Akhtar, M. R., Cross, S., & Isenberg, D. A. (2015). Musculoskeletal complications of haematological disease. *Rheumatology*, 55(6), 968-981.
6. Stetler-Stevenson, M., & Tembhare, P. R. (2011). Diagnosis of hairy cell leukemia by flow cytometry. *Leukemia & lymphoma*, 52(sup2), 11-13.