

## Botriomycoma Revealing Tuberculosis Osteitis of the Tibia: An Unusual Case and Literature Review

Badarou Chaibou<sup>1\*</sup>, Espoir Amour Mokoko<sup>1</sup>, Marou Soumana Boubacar<sup>2</sup>, Zakariyaou Harouna<sup>1</sup>, Abdelhalim ElIbrahimi<sup>1</sup>, Abdelmajid Elmrini<sup>1</sup>

<sup>1</sup>Service of traumatology and orthopedic B of CHU Hassan II, Fes

<sup>2</sup>Service of biologie of CHU Hassan II, Fes

### Case Report

#### \*Corresponding author

Badarou Chaibou

#### Article History

Received: 09.09.2017

Accepted: 25.10.2017

Published: 30.01.2018

#### DOI:

10.21276/sjpm.2018.3.1.1



**Abstract:** Botriomycoma exceptionally reveals an infectious bone site. We report a case of botriomycoma revealing tuberculosis osteitis of the tibia in a 38-year-old man without particular antecedents, who consulted for a cutaneous lesion at the 1/3 proximal of the left leg evolving over 4 months, with bone involvement in imaging, in whom the histological examination of the cutaneous and bone lesions allowed the diagnosis of botriomycoma on an underlying tuberculosis osteitis. Following surgical management associated with anti-tuberculosis treatment, the outcome was favorable. Botriomycoma is a well-known but little reported entity in the literature. It is a benign tumor that often reveals an underlying infectious but rarely bone site. Our case is the first in which this tumor allows us to discover tuberculosis osteitis of the tibia.

**Keywords:** Botriomycoma; Tuberculosis osteitis.

### INTRODUCTION

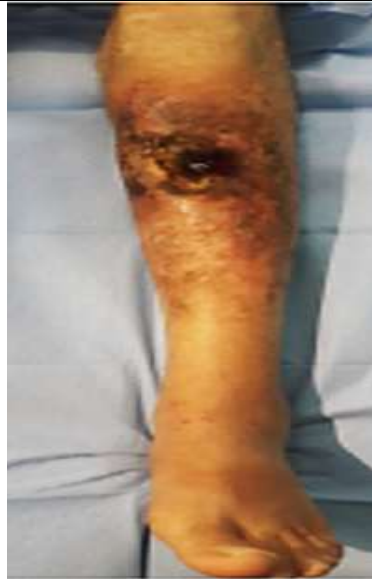Botriomycoma or pyogenic granuloma, is a benign inflammatory vascular tumor usually involving the skin or mucous membranes. It most often affects the fingers, surgical scars or around a deep infectious site [1]. The association with an infectious bone site is rare [2]. We report the case of a botriomycoma in the leg that revealed tuberculosis osteitis in a 38-year-old man.

### CASE PRESENTATION

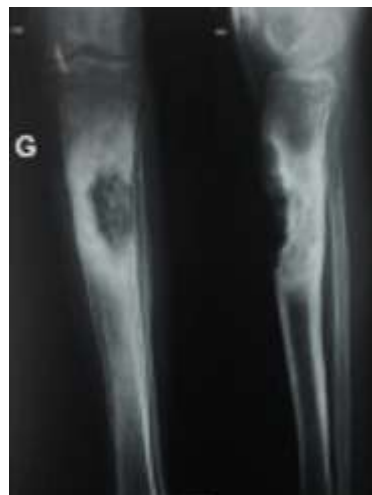
It was a 38 years old man, without particular antecedents, who consulted for a fleshy cutaneous lesion, reddish, bleeding at the slightest touch, sitting on the 1/3 proximal of the left leg, evolving since 4 months (Fig.1).

The x-ray of the leg showed osteolytic lesion at the proximal 1/3 of the tibia, surrounded by diffuse osteocondensation, with rupture of the anterior-external cortical (Fig. 2). Magnetic resonance imaging (MRI) of the leg revealed a cutaneous lesion, ulcerated at its center with a bone lysis facing to this lesion without periosteal apposition with fine and regular contrast in the lesion process of the cutaneous and the bony edges (Fig.3). The biopsy of the cutaneous lesion showed a vascularized granulation tissue, with abundant inflammatory cells, without tuberculoid granuloma or

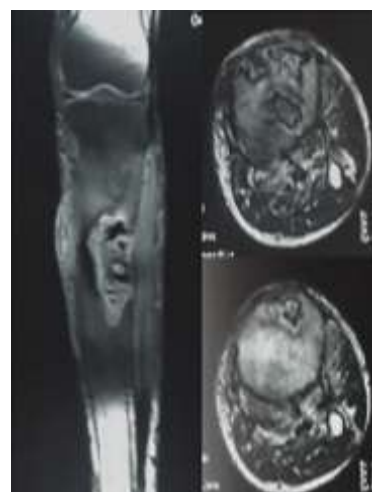
sign of malignancy, in favor of a botriomycoma (Fig. 4). Bone biopsy showed giant granular epithelioid granulomas with ranges of caseous necrosis in favor of tuberculosis osteitis (Fig. 5). We carried botriomycoma excision with drainage of the pus and abundant irrigation. The presence of *Escherichia coli* was objectified in the bacteriological study of pus. The search for other tuberculosis sites was negative. The patient had received anti-tuberculosis treatment with an antibiotic (directed for *Escherichia coli*) and local care.



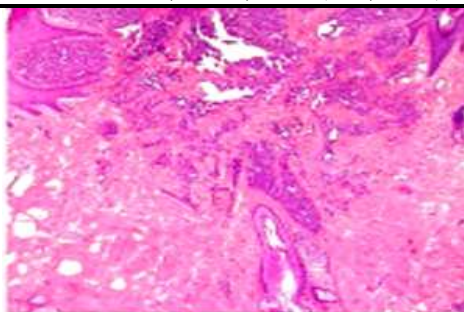
**Fig-1:** Fleshy skin lesion, reddish in appearance, at the proximal 1/3 of the left leg



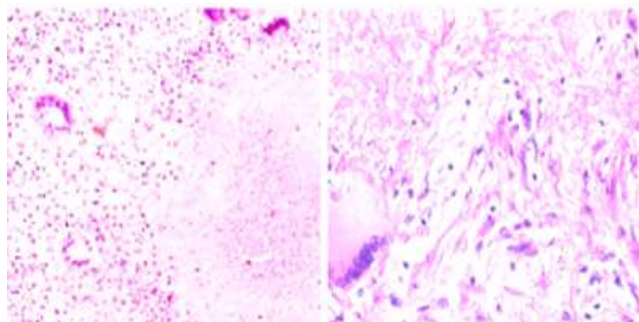
**Fig-2:** X-ray of the left leg (face and profile). There is an osteolytic lesion at the proximal 1/3 of the tibia, encircled by diffuse osteocondensation, with rupture of the anterior-external cortical



**Fig-3:** MRI of the left leg (weighted sequence T1 and T2, then injection of contrast agent): bone lysis facing the cutaneous lesion without periosteal apposition with fine and regular contrasting in the cutaneous lesion process and the bony edges



**Fig-4: (low magnification) vascularized granulation tissue, with abundant inflammatory cells, without granuloma tuberculoid or sign of malignancy, in favor of a botriomycoma**



**Fig-5: (HEX100): giant-cellular epithelial granulomas with ranges of caseous necrosis in favor of tuberculosis osteitis**

## DISCUSSION

Benign, Inflammatory Tumor botriomycoma usually occurs at the level of fingers, surgical scars or revealing a deep infectious site. It is more revealing of the deep infectious site in dental pathology [3]. Cases of botriomycoma have been classically described in the ENT sphere (tongue, gums, face, lips ...). Other topographies have been reported, on the glans after circumcision, after burns, after penetration of a foreign body. Of mucous membranes, in lens wearers, after hair transplantation, or after cryotherapy of benign or malignant cutaneous lesions [4, 5]. Few cases have been reported where it reveals osteitis, including two cases of fracture osteitis by Peyret *et al.* [6], a case of tuberculosis osteitis of the calcaneus by Noama *et al.* [7]. Our case is added to the list. The latter, who describes a botriomycoma as a revealer of a deep infectious site, might assume a priori that the infectious process was hematogenous, then fistulization with budding formation. However, the first biopsy that was specifically cutaneous revealed no signs of tuberculosis. This would cast doubt on the mechanism mentioned above. In addition, botriomycoma should not be confused with botryomycosis of the Anglo-Saxons, corresponding to a chronic fungal infection with cutaneous, bony, visceral forms and which contains grains, containing the infectious agent [8]. There are several therapeutic methods, but the treatment of choice for botriomycosis consists of surgical excision [9], supplemented if necessary by electrocoagulation which should be as complete as possible for prevent Warner and Wilson-Jones' syndrome or recurrent pyogenic granuloma [10]. As for tuberculosis osteitis, its management is not discussed.

## CONCLUSION

Botriomycoma is commonly encountered in daily practice. It is a known entity but little reported in the literature. It is a benign tumor that often reveals an underlying infectious but rarely bone site. Our case is the first in which this tumor allows us to discover tuberculosis osteitis of the tibia.

## ACKNOWLEDGEMENTS

Not applicable.

## Funding

No specific funding is received for this study.

## Conflict of interest

The authors declare that they have no conflicts of interest.

## Consent for publication

Written informed consent was obtained from the patient for publication of this case and report any accompanying images. A copy of written consent is available for review by the editor of this journal.

## REFERENCES

1. Wauters, O., Sabatiello, M., Nikkels-Tassoudji, N., Choffray, A., Richert, B., Piérard, G. E., & Nikkels, A. F. (2010, March). Le botryomycome. In *Annales de Dermatologie et de Vénérologie* (Vol. 137, No. 3, pp. 238-242). Elsevier Masson.
2. Sparsa, A., Bonnetblanc, J. M., Roux, C., Pinet, C., Loustaud-Ratti, V., Boulinguez, S., ... & Bedane,

- C. (2006, October). Botriomycomes révélant une fistule et un foyer infectieux profond: cinq cas. In *Annales de dermatologie et de vénéréologie* (Vol. 133, No. 10, pp. 763-766). Elsevier Masson.
3. Steven Moriconi, E., & Popowich, L. D. (1984). Alveolar pyogenic granuloma: review and report of a case. *The Laryngoscope*, 94(6), 807-809.
  4. Horton, J. C., Mathers, W. D., & Zimmerman, L. E. (1990). Pyogenic granuloma of the palpebral conjunctiva associated with contact lens wear. *Cornea*, 9(4), 359-361.
  5. Greer, K. E., & Bishop, G. F. (1975). Pyogenic granuloma as a complication of cryosurgery. *Archives of Dermatology*, 111(11), 1536-1537.
  6. Sparsa, A., Bonnetblanc, J. M., Roux, C., Pinet, C., Loustaud-Ratti, V., Boulinguez, S., ... & Bedane, C. (2006, October). Botriomycomes révélant une fistule et un foyer infectieux profond: cinq cas. In *Annales de dermatologie et de vénéréologie* (Vol. 133, No. 10, pp. 763-766). Elsevier Masson.
  7. Karbout, N., Hocar, O., Amal, S., Ouilki, I., El Hassani, S., & Akhdari, N. (2013). Pyogenic granuloma satellite of deep infection: Tuberculous osteitis. *Joint Bone Spine*, 5(80), 540.
  8. Winslow, D. J. (1959). Botryomycosis. *The American journal of pathology*, 35(1), 153.
  9. Ghodsi, S. Z., Raziei, M., Taheri, A., Karami, M., Mansoori, P., & Farnaghi, F. (2006). Comparison of cryotherapy and curettage for the treatment of pyogenic granuloma: a randomized trial. *British Journal of Dermatology*, 154(4), 671-675.
  10. Senser, M., Derancourt, C., Blanc, D., Van Landuyt, H., & Laurent, R. (1997). Granulome pyogénique récurrent ou syndrome de Warner et Wilson-Jones. *Archives de pédiatrie*, 4(7), 653-655.