

## Use of Suction Catheter for Retrieval of Displaced Root from the Maxillary

Dr. Mudit Agarwal<sup>1\*</sup>, Dr. R Muthunagai<sup>2</sup>, Dr. Harleen Bali<sup>3</sup>, Dr. N. J. Eswari<sup>4</sup>, Dr. Amit Agarwal<sup>5</sup>

<sup>1</sup>Senior Lecturer, Department of Oral & Maxillofacial Surgery, Seema Dental College & Hospital, Rishikesh, Uttarakhand-249203 India

<sup>2</sup>Senior Lecturer, Department of Oral & Maxillofacial Surgery, Seema Dental College & Hospital, Rishikesh, Uttarakhand-249203 India

<sup>3</sup>Private Consultant, Department of Oral Medicine & Radiology, Jammu & Kashmir, India

<sup>4</sup>Professor, Department of Oral & Maxillofacial Surgery, Mahatma Gandhi Post Graduate Institute of Dental Sciences, Puducherry, India

<sup>5</sup>Professor & HOD, Department of Oral & Maxillofacial Surgery, Seema Dental College & Hospital, Rishikesh, Uttarakhand-249203 India

### Case Report

**\*Corresponding author**

*Dr. Mudit Agarwal*

#### Article History

*Received: 17.03.2018*

*Accepted: 26.03.2018*

*Published: 30.03.2018*

#### DOI:

10.21276/sjodr.2018.3.3.7



**Abstract:** The inadvertent displacement of a tooth or fragment of a tooth into the maxillary sinus during exodontia is not an uncommon experience. Although it is questionable whether such a mishap should be regarded as a dental emergency it is nonetheless a complication which should be treated without undue delay. The purpose of this paper is to discuss a new innovative technique for retrieval of displaced root into the maxillary sinus.

**Keywords:** displaced root, maxillary sinus, suction catheter.

### INTRODUCTION

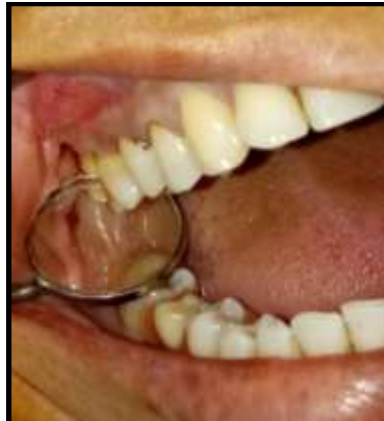Extraction is the commonest minor oral surgical procedure in a dental clinic. Displacement of a fractured root into the maxillary sinus is one of the complications of extraction of maxillary posterior teeth. It occurs accidentally and may cause severe problems with oroantral fistula, sinusitis, cellulitis, and subdural empyema [1].

Diagnosis of the displaced root in the maxillary sinus depends on imaging, evaluating the root size, and its location within the sinus. Surgical retrieval is considered first, even though some studies suggest leaving the root fragment in the sinus if it is 3 mm in size and in the absence of sinusitis or other local disease<sup>2</sup>. Surgical approaches include retrieval via the extraction socket<sup>2</sup> or the Caldwell-Luc approach, which can avoid enlarging the oroantral communication (OAC) and potentially causing an oroantral fistula.

### CASE REPORT

A 36 year old female patient reported to our department with the chief complaint of pain and pus discharge in relation to right upper back tooth region for the past 1 month. Patient gives a history of extraction of upper right maxillary second molar tooth 1 month before following which she had a complaint of pain, nasal regurgitation of fluids and pus discharge. Patient had

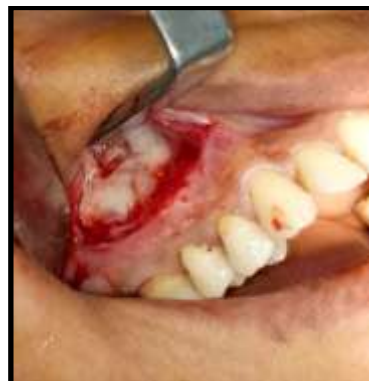consulted ENT surgeon also for the same problem and she has been diagnosed displacement of fractured maxillary molar root into the maxillary sinus leading to the formation of oro-antral communication. Patient was treated with antral triage and referred to oral and maxillofacial surgeon for retrieval of root from the maxillary sinus.



**Fig-1: Extraction socket of 17 completely healed**

On extra oral examination there was tenderness over the right cheek region. Intra orally the extraction site was completely healed (fig. 1).

Radiograph was taken to locate the displaced root into right maxillary sinus. We planned for retrieval of root from right maxillary sinus through Caldwell luc surgery under local anesthesia.

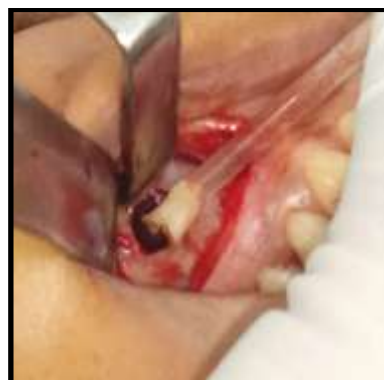

**Fig-2: Creation of bony window in maxillary sinus**

#### **Surgical procedure**

Surgery was performed under local anesthesia using 2% lignocaine with 1:100000 adrenaline. After achieving adequate anesthesia vestibular incision was made from the canine to the first molar region, and a full-thickness mucoperiosteal flap was reflected to expose the canine fossa. A bone window 5-6 mm in diameter was made above the apices of the premolars (fig. 2).

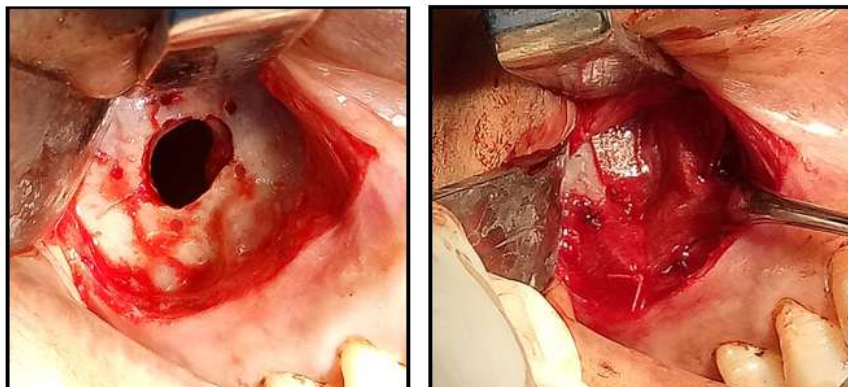
We found there was accumulation of pus into the maxillary sinus. Pus drainage was done through the bony window created through suction tip. Root tip was mobile but we found difficulty in retrieving the root with the metal suction tip because the root was not in a straight line access with the sinus window. Hence we used a new innovative technique of using a suction catheter for retrieving the root (fig. 3). Due to high suction pressure and flexibility of the suction catheter the displaced root was retrieved easily.



**Fig-3: Retrieval of displaced root using suction catheter**

After thorough irrigation of the sinus, closure of the bony window was done using membrane which was stabilized to the bone by creating a hole in the bone

and suturing was done using 4-0 vicryl (fig. 4 & 5). After adaptation of the membrane, mucosal closure was done using 4-0 vicryl.



**Fig-4 & 5: Creation of holes around sinus window using 701 straight fissure burs to secure the collagen membrane over window with resorbable suture**

#### Postoperative care

Patient was started on antral triage and antibiotics. Patient was warned that nasal bleeding for 2-3 days is possible. Patient was instructed to take soft diet, avoid sucking on a straw, sneezing, and nose blowing. Patient reported after 1 week for suture removal with complaint of paraesthesia of right infraorbital nerve. Surgical site healing was satisfactory. Patient was prescribed cap. Neurobion forte once daily along with a short course of steroids for management of nerve paraesthesia. Patient was kept on follow up.

#### DISCUSSION

Extraction is the commonest surgery performed in the dental office. Although most cases are simple, complications can occur. Displacement of a tooth or root fragment into the maxillary sinus is rare: Rothamel *et al.* recorded only 1 patient in a review of 1,596 cases of maxillary third molar extraction in 2006[3]. This complication can progress to severe clinical and legal problems. Dentists should be aware of this complication which occurs by accident and often in teeth that appear to be simple extractions on radiographs [4].

#### Anatomical considerations

The maxillary sinus appears as a lateral evagination of the mucous membrane of the middle meatus at about the 3rd month of intrauterine life, and is present at birth as a shallow cavity about 2 x 1 x 1 cm on the lateral wall of the nose. It expands gradually by pneumatization of the body of the maxilla and reaches its maximum size at about 15 years of age, when all the permanent teeth with the exception of the third molars have normally erupted. The fully developed maxillary sinus is somewhat pyramidal in shape with its base at the nasa-antral wall and apex in the root of the zygoma. Its size varies considerably from individual to individual, depending upon the degree of

pneumatization. In a large sinus, the downward extension of the floor towards the alveolus will result in the intrusion of the root apices of the adjacent teeth into the cavity, leaving these apices covered by paper-thin bone, and in exceptional cases, by only antral mucosa. This is most pronounced in the first molar region, where the antral floor is at its lowest point, and often extends downwards between the buccal and palatal roots of this tooth. Thus the root apices of the first molar lie in closest proximity to the antral floor and are consequently most commonly displaced into the maxillary sinus [5].

#### Diagnosis

The diagnosis of a recently displaced root in the maxillary sinus is obvious as a rule. A history of sudden disappearance of a root fragment from its socket during manipulation together with a breach in the floor of the maxillary sinus is strongly suggestive of such a mishap. In a periapical radiograph, the displaced root fragment is usually seen to be lying near its socket and is devoid of its normal surrounding periodontal membrane and lamina dura. Alteration of its position in a successive radiograph after the patient has vigorously moved his head is confirmatory evidence that the root is inside the antrum. However, such a root often becomes incarcerated by blood clot, and is unlikely to shift in spite of vigorous movements of the patient's head. Instead of being dislodged into the antrum, a root fragment may be displaced into other tissue planes such as the extramucosal site, i.e. outside the antral mucosa, the subperiosteal plane, or intra-buccally, i.e. within the buccal soft tissue. Obviously it is extremely difficult, if not impossible, to differentiate these various positions of the displaced root on radiographic examination [5].

Root condition of the displaced root into the maxillary sinus could be divided into 3 types: Mobile type: root changed location at 2 different image

examination after shaking head position; Fixed type A: root located between sinus membrane and bone; and Fixed type B: root in the sinus cavity and fixed by adherent membrane [4]. Patients with the 3 different root types are treated differently. *The Mobile type.* A straight metal suction tip going from the bone window directly to the posterior sinus, where the root fragment is usually located when the patient is supine. The suction apparatus is set on high, and it is easy to retrieve the root.

The Fixed types. Elevation of the sinus membrane from the bone first if the root lies between the membrane and the bone (fixed type A). It is usually adjacent to the socket of the extracted tooth and is usually removed without difficulty. If this fails—or if the fixed type B is present (with the membrane adjacent to the root) — curette is used to loosen the fragment and let it fall into the posterior sinus, and then the root removal is done as for the mobile type. In using the suction tip or curette, one must be aware of the infraorbital nerve and the anterior superior alveolar artery [4]. Careful evaluation of the radiograph is needed to determine the location of the root, such as the ostium of the sinus [6, 7] or below the orbital floor. Regardless of its position a displaced root should be retrieved promptly either at the time of its displacement or at the earliest opportunity. In the past ten years, endoscopic retrieval of a root (or implant) from the sinus has been reported [8-10]. This has the advantage of a small bony window (4 mm will suffice), and under direct vision the root can be removed accurately with less risk of injury to the infraorbital nerve or vessels [11]. However, endoscopy is performed under general anesthesia and requires the admission of the patient. Huang *et al.* [4] suggest placing the patient in supine position, since the shape of the sinus is pyramidal with the base being the medial wall of the sinus and the apex extending into the zygomatic process of the maxilla, the mobile root fragment tends to fall into the posterior part of the sinus, thus facilitating removal with a straight suction tip. In our experience we found this technique useful and in addition we recommend the use of flexible suction catheter over metal suction tip as it is flexible, atraumatic and does not require a straight line access.

Most common complications may include pain, swelling, bleeding, and discharge. Rarely there have been reports of orbital hematoma, visual disturbances, and infraorbital nerve damage [12].

## CONCLUSION

Displacement of root into maxillary sinus usually occurs due to inadvertent forces applied while attempting removal of fractured root tip of maxillary molars. With the sound knowledge of instrumentation and extraction technique this complication could be easily prevented. Nevertheless, such a mishap should be dealt immediately by referring the patient to a specialist to prevent further complications. The use of suction

catheter as described in this paper could be of great help for the treating surgeon in retrieval of displaced root tip from maxillary sinus.

## REFERENCES

1. Woolley, E. J., & Patel, M. (1997). Subdural empyema resulting from displacement of a root into the maxillary antrum. *British dental journal*, 182(11), 430.
2. Fonseca, M. G., Bastos, F. I., Derrico, M., Andrade, C. L., Travassos, C., & Szwarcwald, C. L. (2000). AIDS e grau de escolaridade no Brasil: evolução temporal de 1986 a 1996. *Cadernos de Saúde Pública*, 16, S77-S87.
3. Rothamel, D., Wahl, G., d'Hoedt, B., Nentwig, G. H., Schwarz, F., & Becker, J. (2007). Incidence and predictive factors for perforation of the maxillary antrum in operations to remove upper wisdom teeth: prospective multicentre study. *British Journal of oral and maxillofacial surgery*, 45(5), 387-391.
4. Huang, I. Y., Chen, C. M., & Chuang, F. H. (2011). Caldwell-Luc procedure for retrieval of displaced root in the maxillary sinus. *Oral Surgery, Oral Medicine, Oral Pathology, Oral Radiology and Endodontics*, 112(6), e59-e63.
5. Lee, F. M. S. (1978). Management of the displaced root in the maxillary sinus. *International journal of oral surgery*, 7(4), 374-379.
6. Sethi, A., Cariappa, K. M., & Chitra, A. (2009). Root fragment in the ostium of the maxillary sinus. *British Journal of Oral and Maxillofacial Surgery*, 47(7), 572-573.
7. Sims, A. P. T. (1985). A dental root in the ostium of the maxillary antrum. *British Journal of Oral and Maxillofacial Surgery*, 23(1), 67-73.
8. Friedlich, J., & Rittenberg, B. N. (2005). Endoscopically assisted Caldwell-Luc procedure for removal of a foreign body from the maxillary sinus. *Journal (Canadian Dental Association)*, 71(3), 200-201.
9. Costa, F., Emanuelli, E., Robiony, M., Zerman, N., Polini, F., & Politi, M. (2007). Endoscopic surgical treatment of chronic maxillary sinusitis of dental origin. *Journal of Oral and Maxillofacial Surgery*, 65(2), 223-228.
10. Chandrasena, F., Singh, A., & Visavadia, B. G. (2010). Removal of a root from the maxillary sinus using functional endoscopic sinus surgery. *British Journal of Oral and Maxillofacial Surgery*, 48(7), 558-559.
11. Ikeda, K., Hirano, K., Oshima, T., Shimomura, A., Suzuki, H., Sunose, H., & Takasaka, T. (1996). Comparison of complications between endoscopic sinus surgery and Caldwell-Luc operation. *The Tohoku journal of experimental medicine*, 180(1), 27-31.
12. Dover, M. S. (1993). Principles of oral and maxillofacial surgery. *British Journal of Oral and Maxillofacial Surgery*, 31(3), 199.