

## Xanthogranulomatous Gastritis Mimicking Malignancy: A Case Report with Review of Literature

Dr. Akanksha Pandey<sup>1\*</sup>, Dr. Sudhamani S<sup>2</sup>, Dr. Prakash Roplekar<sup>3</sup>

<sup>1</sup>Resident, Department of Pathology, Dr. D.Y. Patil Medical College, Nerul, Navi Mumbai, Maharashtra, India

<sup>2</sup>Professor, Department of Pathology, Dr. D.Y. Patil Medical College, Nerul, Navi Mumbai, Maharashtra, India

<sup>3</sup>Professor & Head, Department of Pathology, Dr. D.Y. Patil Medical College, Nerul, Navi Mumbai, Maharashtra, India

### Case Report

\*Corresponding author

Dr. Akanksha Pandey

### Article History

Received: 16.04.2018

Accepted: 26.04.2018

Published: 30.04.2018

### DOI:

10.21276/sjpm.2018.3.4.8



**Abstract:** Xanthogranulomatous gastritis is an extremely rare condition and only few cases have been reported in literature. It is an inflammatory tumor like lesion usually misdiagnosed preoperatively as an advanced gastric cancer. We report one such rare case in a 68 year old female who came with complaint of epigastric pain and vomiting for 15 days. Endoscopy revealed solitary elevated nodule in the gastric lesser curvature. Clinical diagnosis was suspicious of gastric carcinoma. Histopathologically foamy histiocytes with dense chronic inflammatory infiltrate were seen in gastric wall suggestive of xanthogranulomatous gastritis.

**Keywords:** Xanthogranulomatous gastritis, stomach tumour, inflammatory tumour.

### INTRODUCTION

Xanthogranulomatous gastritis is uncommon and extremely rare condition of stomach [1]. It is said to be associated with cholecystitis or other inflammatory lesions in the surrounding organs and can be misdiagnosed as gastric cancer. This uncommon inflammation can progressively invade adjacent organs, mimicking malignant tumour.<sup>2</sup> It is difficult to diagnose preoperatively as clinical, radiological and endoscopic findings may rise suspicion of early gastric cancer. Hence, histopathological examination is necessary to arrive at a proper diagnosis and to prevent unnecessary surgical interventions. Only a very few cases have been reported in literature. The exact etiology, age and sex predilection is not known [1, 2].

Therefore, the need to recognise this unique entity to avoid misdiagnosis and to prevent further complications.

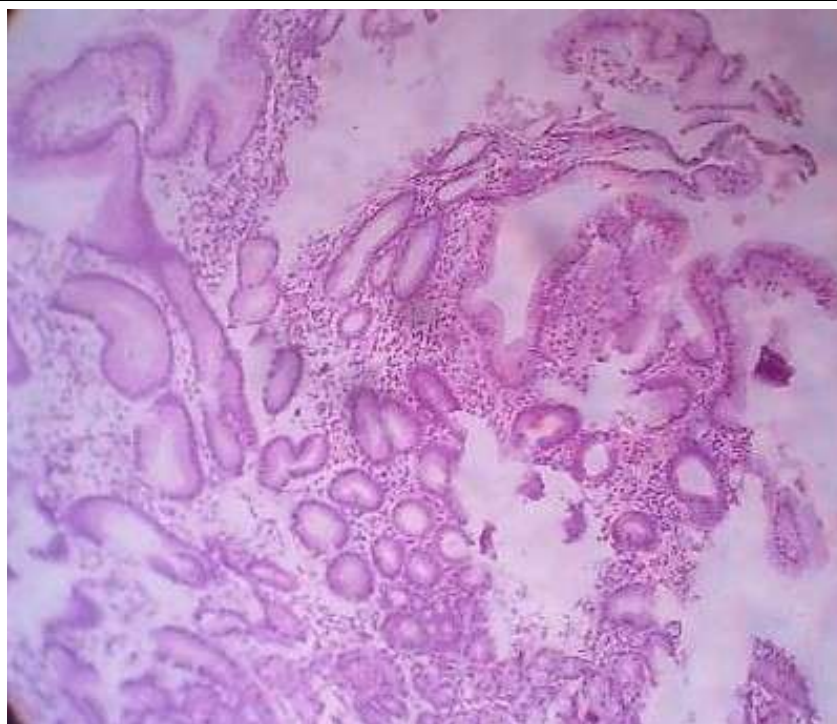
### CASE REPORT

A 68 years old female presented with epigastric pain and vomiting for 15 days. CT scan revealed thickening of the gastric wall in the lesser curvature. Rest of the abdominal organs including gallbladder and kidney were normal. Blood investigations were in normal range. An endoscopic examination revealed a solitary gastric nodule measuring 0.5x0.5 cm in the lesser curvature.

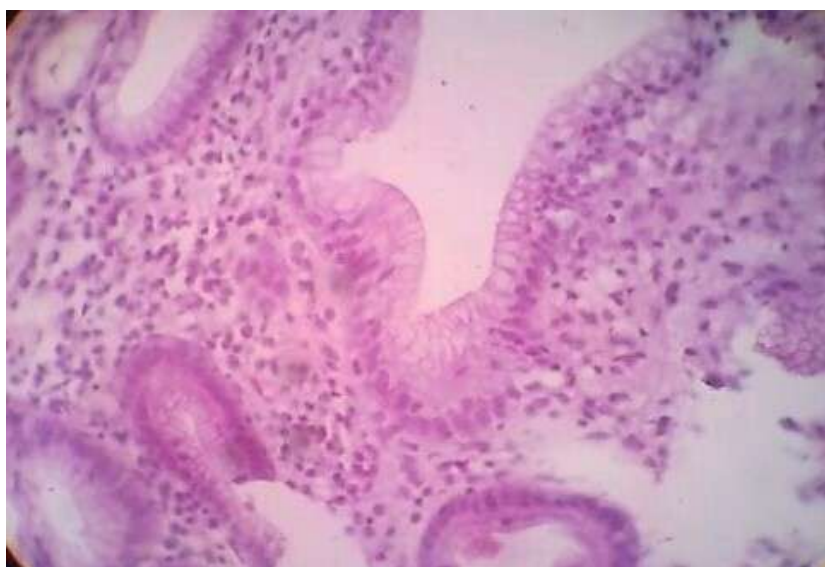Based on these features clinical diagnosis was suspicious of gastric carcinoma. Multiple biopsies were taken from solitary gastric nodule and was sent to histopathology section. No other lesions were found in the stomach.

Grossly we received multiple (4) tiny soft tissue bits altogether measuring 0.5 cm. All tissue processed.

Microscopy showed normal gastric mucosal lining and denselymphoplasmacytic infiltrate throughout the layers of stomach. Many aggregates of foamy macrophages and histiocytes were seen in lamina propria and submucosa displaying eccentric round small vesicular nuclei and abundant foamy cytoplasm. Areas of fibrosis surrounding the macrophages was noted. There was no evidence of epithelioid cell giant cells or H. pylori in serial sections studied. There was no evidence of atypia or malignancy. Based on these findings a diagnosis of xanthogranulomatous gastritis was made. Patient was then evaluated for features of cholecystitis or pyelonephritis, but no such association was seen. Finally, an isolated case of xanthogranulomatous gastritis was made. She was treated with medications for the same. On follow up there was no evidence of recurrence of inflammation.



**Fig-1: Sections showing normal gastric mucosal lining and dense lymphoplasmacytic infiltrate throughout the layers of stomach. H&E (4x)**



**Fig-2: Sections showing aggregates of foamy macrophages and histiocytes in lamina propria and submucosa displaying eccentric round small vesicular nuclei and abundant foamy cytoplasm .H&E (40x)**

## DISCUSSION

Xanthogranulomatous gastritis is a rare tumor like lesion first described by Oberling in 1935 [1].

It is said that xanthogranulomatous gastritis is macroscopically characterised by formation of multiple yellow nodules with or without ulcerative mucosa [2]. In our case, however it was a solitary, elevated nodule with thickening of the wall.

Xanthogranulomatous inflammation is common in the gallbladder and kidney. However, it has

also been reported in other organs including Stomach, colon, pancreas and uterus [1, 2]. Xanthogranulomatous gastritis presenting as an isolated entity, as in our case is extremely rare, as it is said to be associated with chronic cholecystitis in majority of cases reported in literature [2].

The pathogenesis of xanthogranulomatous gastritis remains unclear and the possible theories include chronic lesion associated with infection, immunologic disorders, lymphatic obstruction and lipid transport [1, 2].

Some of these lesions are said to have occurred in patients with previous gastric surgery as it was seen located the suture line. But in our case, there was no past history of surgery or any other ailment in the patient [2].

These can be misdiagnosed as either malignant gastrointestinal stromal tumor (GIST) or gastric cancers as endoscopic findings are marked FDP uptake on PET scan mimics advanced gastric malignancy. Therefore, preoperative diagnosis is seldom possible as seen in present case. The histopathological differential diagnosis of these lesions include chronic gastritis with regenerative changes, mucosa associated lymphoid tissue lymphoma (MALT), Signet ring cell carcinoma or *H. pylori* associated gastritis [2].

However, the presence of aggregates of histiocytes and foamy macrophages in the absence of malignant cells or *H.pylori* helps in arriving at the diagnosis of xanthogranulomatous gastritis.

#### **CONCLUSION**

Even though very rare, isolated xanthogranulomatous gastritis should be considered in the differential diagnosis of gastric growths as it clinically and endoscopically mimicks malignant condition.

#### **REFERENCES**

1. Kinoshita, H., Yamaguchi, S., Sakata, Y., Arie, K., Mori, K., & Kodama, R. (2011). A rare case of xanthogranuloma of the stomach masquerading as an advanced stage tumor. *World journal of surgical oncology*, 9(1), 67.
2. Okamura, A., Takahashi, T., Saikawa, Y., Nakadai, J., Ono, T., Nakamura, R., ... & Sasaki, A. (2016). Xanthogranulomatous gastritis of the remnant stomach mimicking a malignant tumor: A case report. *Oncology letters*, 11(2), 1453-1456.
3. Banerjee, S., Shah, S., Chandran, B. S., Pulimood, A., & Mathew, G. (2010). Chronic perforation in isolated xanthogranulomatous gastritis.
4. Zhang, L., Huang, X., & Li, J. (1992). Xanthogranuloma of the stomach: a case report. *European journal of surgical oncology: the journal of the European Society of Surgical Oncology and the British Association of Surgical Oncology*, 18(3), 293-295.
5. Kubosawa, H., Yanok, O., Shiobara, M., Ando, K., Nunomura, M., & Sarashina, H. (2007). Xanthogranulomatous gastritis with pseudosarcomatous changes. *PatholInt*.57: 291-295.