

## Rare Masquerader of Breast Carcinoma

Dr. Nazneen Abdul Kader\*, Dr. Rosemary Renjith, Dr. Sathi P. P, Dr. Sindhu K. Bhaskaran

Department of Pathology, Government Medical College, Kozhikode, Kerala, India

### Case Report

\*Corresponding author  
Dr. Nazneen Abdul Kader

#### Article History

Received: 07.07.2018

Accepted: 13.07.2018

Published: 30.07.2018

#### DOI:

10.21276/sjpm.2018.3.7.1



**Abstract:** A huge malignant tumour of breast for radiologists turned out to be a rare benign tumour. An ordinary tumour in an extra ordinary location in 80 year old female! Pleomorphic adenoma in breast was mistaken for a malignant tumour and radical surgery was performed. Hence, clinicians, radiologists and pathologists should be aware of this rare tumour and its clinical, mammographic and variable histological appearances, in order to avoid misdiagnosis and an unwarranted radical surgery.

**Keywords:** Pleomorphic adenoma breast, mimicker of carcinoma, benign breast lump.

### INTRODUCTION

Pleomorphic adenoma occurs only rarely in the breast. Yet its recognition is important because it can easily be mistaken for carcinoma. Histologically, the neoplasm is identical to that occurs in salivary glands. The differential diagnosis are ductal adenoma, carcinoma with mucoid, myxoid, cartilaginous, or osteoid changes. Differentiation from mucinous carcinoma, is sometimes difficult and depends on the benign nature of the epithelial cells.

### CASE REPORT

82 year old multiparous female complained of slow growing mass in the right breast for 25 years. The swelling was not associated with pain, nipple retraction or nipple discharge. She had attained menopause at 50 years. There were no other comorbidities.

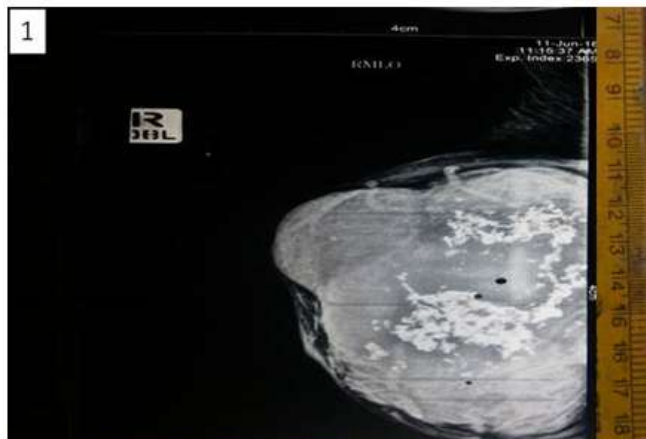
O/E a hard large lump filling almost the entire right breast. The lump was not fixed to skin or chest wall. There was no nipple discharge or nipple retraction. There was no axillary swelling. Left breast was normal.

Her routine blood and urine investigations were normal. Mammogram showed well defined hypoechoic lesion in the right measuring 8.5x 6.7x 8.6 cm with multiple foci of calcification and anechoic cystic areas-highly suggestive of malignancy (Fig-1). As the patient refused for FNA or biopsy and any further delay in the treatment, the surgeon proceeded with surgery.

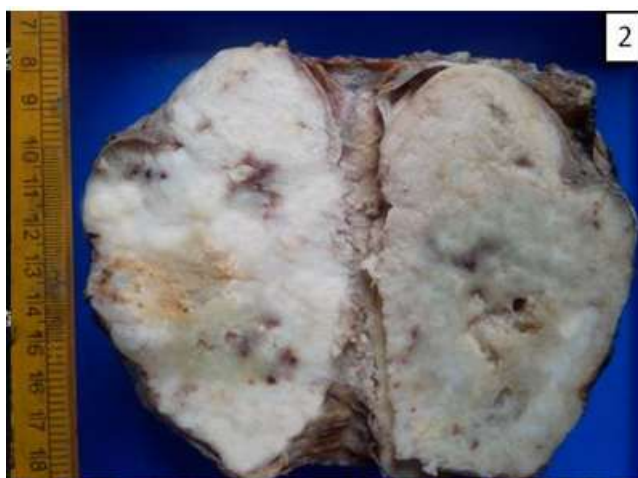Following modified radical mastectomy, we received a hard swelling with attached elliptical piece of skin and axillary pad of fat. The skin and nipple were normal. The mass measured 12 x 11x 11cm and was hard and gritty on cut section and showed well

circumscribed encapsulated grey white lobulated lesion with multiple tiny cystic areas (Fig-2). Focal extracapsular extensions were seen. No areas of hemorrhage or necrosis were seen.

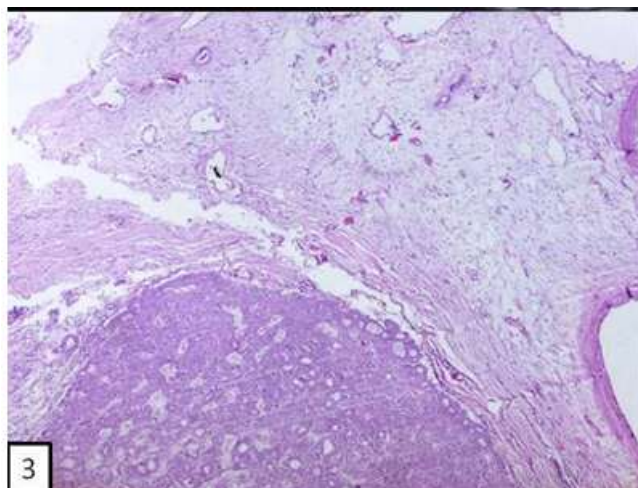
Microscopically, the tumour was a well circumscribed unencapsulated (Fig-3) lesion which consisted of strips of epithelium in various patterns embedded in pale blue chondromyxoid matrix. The patterns of epithelial strips included trabecular, cord-like, cibriform, reticulated and solid (Fig-4). There were no increased mitosis or necrosis or atypia. The epithelial cells were cuboidal, with pink cytoplasm and small oval nuclei. Stellate and spindle-shaped myoepithelial-type cells were seen in the stroma. The extra-capsular extensions were identical with that of the rest of the tumour. Margins were free of tumour. Her post-operative recovery was uneventful and is recurrence free at 1 year of follow up.



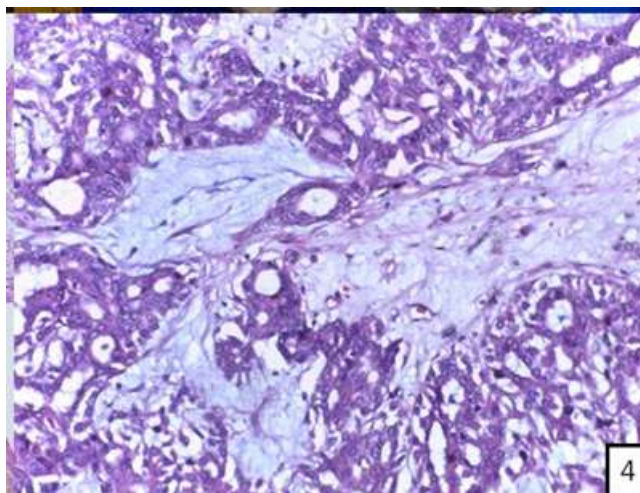
**Fig-1:** Mammogram of right breast showing well defined hypoechoic lesion with multiple foci of calcification and anechoic cystic areas



**Fig-2:** Gross morphology of the lesion- well circumscribed encapsulated grey white lobulated lesion with hard and gritty consistency.



**Fig-3:** Microscopy of the lesion- well circumscribed unencapsulated margins (H&E 5X)



**Fig-4: Tumour consisting of strips of epithelium in various pattens, embedded in chondromyxoid matrix (H&E 20X) with benign nuclear features.**

## DISCUSSION

Pleomorphic adenoma of breast (PAB) was first reported in 1906 by Lecene. Now accounts for 77 cases in the literature<sup>1</sup>. Pleomorphic adenoma mainly occurs in the salivary gland; have also been reported in sella turcica, lacrimal gland, larynx, skin, vulva, lungs and in the kidney [1]. Women are more affected than men (F:M=10:1) [2]. Patients range in age from 23 to 78 years (mean, 61 years) [1]. Ours is the oldest female reported so far. Most tumors of PAB occur in the right breast rather than left (right to left: 3:2) [3].

These are slow growing solitary painless tumours; often encapsulated, well defined ovoid and round masses [2]. Tumors range from 0.7 to 20 cm in diameter (mean-2cm) [1]. PAB has a tendency to occur in the juxta-areolar region, and this may suggest that it originates from the large duct [3]. PAB is firm to hard and well circumscribed. Skin involvement and nipple retraction are rare and may arouse suspicion of malignancy. On mammography, tumors appear circumscribed and homogeneous, with dense or speckled calcification [4].

Grossly, PAB are circumscribed, and has yellow-white appearance on sectioning. Microscopically, PAB is composed of a mixture of epithelial, myoepithelial, and stromal elements. Epithelial cells appear cuboidal to low columnar with bland cytologic nuclear features and minimal mitotic activity and may be arranged as tubules, islands, cords, or sheets and may exhibit apocrine differentiation. The surrounding myoepithelial cells appear polygonal, plasmacytoid, fusiform, stellate or clear which may be seen admixed with epithelial cells or dispersed throughout the stroma. The stroma may be loose and composed of one or more of the following matrices: (1) myxoid, (2) chondroid, or (3) osseous. Intraepithelial and stromal mucin may be demonstrated with colloidal iron and mucicarmine stains.

The epithelial cells are strongly positive for cytokeratin, carcinoembryonic antigen, and epithelial membrane antigen, and are occasionally positive for vimentin and glial fibrillary acidic protein. Myoepithelial cells are strongly positive for vimentin, muscle-specific actin, and cytokeratin [2].

The breast tissue surrounding a PAB may exhibit benign or malignant changes. The benign changes include fibrocystic changes and intraductal papillomas [4].

Misdiagnosis is common even in preoperative biopsy, and the common ones being mucinous carcinoma [5] and metaplastic carcinoma [6]. Features differentiating pleomorphic adenoma from mucinous carcinoma and metaplastic carcinoma are the circumscription, presence of chondromyxoid matrix, myoepithelial cells, lack of atypia, necrosis mitosis and high mib [2]. The extracellular mucin stains positively with alcian blue (at pH 1.0 and 2.5) and is not obliterated by hyaluronidase pretreatment (at pH 1.0 and 2.5) in mucinous carcinoma. Whereas, treatment with hyaluronidase bliterates alcian blue staining in pleomorphic adenoma. Hence this can be used to differentiate these two entities [4].

The local excision of tumor margin with a narrow (2 to 5 mm) rim of normal breast tissue was recommended for PAB. Patients should be informed of the risk of recurrence. Three cases of malignant PAB (i.e., carcinoma ex PAB) have been reported<sup>4</sup>; however, none had metastasized to axillary lymph nodes or distant sites. The histological features of malignant PAB are infiltrative growth patterns, marked atypia, high mitotic rate, necrosis and high Mib-1 index [1].

## CONCLUSION

Clinicians, radiologists and pathologists should be aware of this rare tumour and its clinical, mammographic and variable histological appearances,

in order to avoid misdiagnosis and an unwarranted mastectomy.

#### **REFERENCES**

1. Han, Y., Zhang, Q., Li, S. X., Feng, L., Zhang, L., Li, Z., ... & Chen, B. (2016). Case Report Pleomorphic adenoma of the breast: a report of two cases and a literature review. *Int J Clin Exp Pathol*, 9(2), 2459-2465.
2. Gupta, D., Agrawal, S., Trivedi, N., & Tewari, A. (2015). Pleomorphic adenoma of breast-a case report and distinction with metaplastic carcinoma. *Journal of Diagnostic Pathology*, 9(2).
3. Khamechian, T., Alizargar, J., & Mazoochi, T. (2014). Reporting a rare case of pleomorphic adenoma of the breast. *Case reports in medicine*, 2014.
4. Reid-Nicholson, M., Bleiweiss, I., Pace, B., Azueta, V., & Jaffer, S. (2003). Pleomorphic adenoma of the breast: a case report and distinction from mucinous carcinoma. *Archives of pathology & laboratory medicine*, 127(4), 474-477.
5. Iyengar, P., Cody III, H. S., & Brogi, E. (2005). Pleomorphic adenoma of the breast: case report and review of the literature. *Diagnostic cytopathology*, 33(6), 416-420.
6. Djakovic, A., Engel, J. B., Geisinger, E., Honig, A., Tschammler, A., & Dietl, J. (2011). Pleomorphic adenoma of the breast initially misdiagnosed as metaplastic carcinoma in preoperative stereotactic biopsy: a case report and review of the literature. *European journal of gynaecological oncology*, 32(4), 427.