

## Sonographic Differentiation of Pancreatic Appearance between Diabetic and Non-Diabetic Individuals of Age 45-55years

Izhar Ud Din<sup>1\*</sup>, M. Waqas Aleem<sup>2</sup>, Ali Ahmad<sup>3</sup>, Zaka Ullah<sup>4</sup>, Yasir Aziz<sup>5</sup>, Dr. Raham Bacha<sup>6</sup>, Zain Ul Hasan<sup>7</sup>, S. Muhammad Yousaf Farooq<sup>8</sup>, Rehan Afsar<sup>9</sup>

<sup>1</sup>Student of MID, The University of Lahore, Pakistan

<sup>2-5</sup>Student of MID, The University of Lahore, Pakistan

<sup>6</sup>PhD, M. Phil Ultrasound, The University of Lahore, Pakistan

<sup>7</sup>Assistant professor (UOL) PHD (scholar) M Phil, M Sc Ultrasound, The University of Lahore, Pakistan

### Original Research Article

#### \*Corresponding author

*Izhar Ud Din*

#### Article History

*Received: 02.10.2018*

*Accepted: 07.10.2018*

*Published: 30.10.2018*

#### DOI:

10.21276/sjimps.2018.4.10.1



**Abstract:** One of the most common chronic diseases in closely all states is Diabetes Mellitus. The world occurrence of diabetes amongst elderly (20-79) in 2010 was 6.4% distressing 285 million adult and all ages and probable to be increased to 7.7% distressing 439 million adult in 2030. In Pakistan Diabetes Mellitus (DM) the recent occurrence of type 2 diabetes mellitus is 11.77%. The prevalence is advanced between male than females, the occurrence of (DM) Diabetes Mellitus in urban areas are more common than rural areas. (DM) Diabetes Mellitus is a set of diseases categorized by great level of blood glucose causing from faults in insulin excretion, and its action or both. We compared the echogenicity of pancreas with the surrounding organ superior mesenteric artery (fat around (SMA)). The size of the pancreas is slightly decreased as compare to the normal individuals. To determine the sonographic differentiation of pancreatic appearance between diabetic and non-diabetic individuals of age 45-55years. A cross sectional comparative study was conducted at Gilani ultrasound clinic Lahore. Total 150 individuals of both diabetic and non-diabetic were included in this study to compare the sonographic appearance of pancreas in diabetic and non-diabetic individuals. Peoples from the age group of 45-55 years are only included in this study. According to the result Fatty pancreas was seen on ultrasound hyperechoic and the normal pancreas was hypoechoic. The size of the pancreas is slightly decreased in diabetic patients as compare to non-diabetic individuals. Glucose level in diabetic patients was more than normal individuals. The mean age group was 49.9133. Out of 75 patients 43 patient pancreas were seen hyperechoic. The mean of pancreatic head was 22.22mm, pancreatic body was 21.11mm and pancreatic tail was 21.87mm. In our study female were more than male. Highly echogenic pancreas is associated with diabetes mellitus (DM).

**Keywords:** Pancreatic appearance, diabetic individuals, non-diabetic individuals, sugar level.

## INTRODUCTION

One of the most common chronic diseases in closely all states is Diabetes Mellitus. The world occurrence of diabetes amongst elderly (20-79) in 2010 was 6.4% distressing 285 million adult and all ages and probable to be increased to 7.7% distressing 439 million adult in 2030 [1]. In Pakistan Diabetes Mellitus (DM) the recent incidence of type 2 diabetes mellitus is 11.77%. The prevalence is advanced between male than females, the occurrence of (DM) Diabetes Mellitus in urban areas are more common than rural areas<sup>2</sup>. Pancreas lies in the back segment of the upper mid-region behind the stomach [3]. (DM) Diabetes Mellitus is a set of diseases categorized by great level of blood glucose causing from faults in insulin excretion, and its action or both [4].

The Category 2 Diabetes Mellitus (T2DM) are disorders categorized through the variable level of insulin resistance affecting hyper glycaemia on the experience of an insulin secretion fault [5]. There are numerous reasons of fatty pancreas, including alcohol use and obesity. Intake foods rich in fat can lead to fatty infiltration nearby the pancreas and other body tissues. It can also be affected by the materials like alcohol which affect the pancreas to metabolize fats less proficiently, causing in buildup [6]. Another study has revealed that those who are overweight or obese have a higher possibility of fatty pancreas than those who are healthy weight. Many times, losing weight and the cutting out morbid diets from the nutrition is all that is required to eliminate fatty infiltration from the body organ [7]. Screening is the procedures by which asymptomatic person that are at high threat of the disease are identified for the advance analysis. Type 2

diabetes mellitus (T2DM) noticed with an abnormal Oral Glucose Tolerance Test and fasting plasma glucose test [8]. Diabetes Mellitus (DM) possibility assessment questionnaire generally comprise the following components, sex, age, family past and biometric sizes such as Body Mass Index (BMI), abdomen boundary, and belly to hip ratio and Past of Hypertension [9].

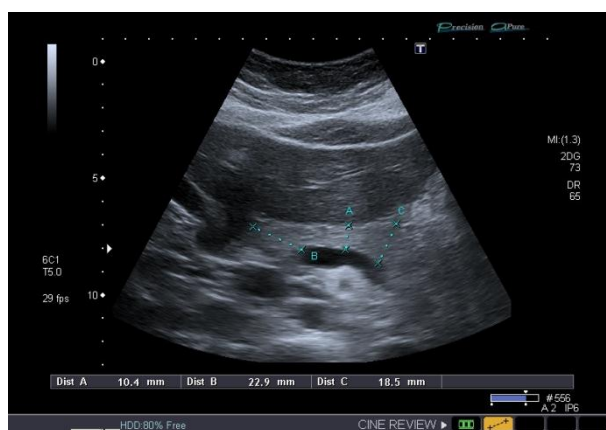
Role of the ultrasound, put on graded compression to the transducer in pancreatic scan air gases can be moved away and pancreatic crown, neck, body and tail can often be visualized clearly. Acoustic window for pancreatic scan can be obtained by fluid filled stomach and drinking two glasses of water for further improvement. Normal pancreatic echotexture is hyper echogenic compared to the normal liver. Increasing with age the echogenicity of the pancreas also improved. Pancreas AP diameters, crown is (2.5 cm), body (1.5 cm), tail (3.5 cm) and the pancreatic duct (< 2.5 mm)<sup>10</sup>. Patient should be in fasting at least 6 hours for all transabdominal ultrasound scans to improve image contrast<sup>11</sup>. For biliary pain the role of investigation is transabdominal ultrasound scan[12]. The sensitivity of endoscopic ultrasound is higher than M R I (36% Sensitivity and 87% specificity) and CT (37% Sensitivity and 79% specificity, respectively[13]. The accurate and reliable detection of fatty pancreas is ultrasonography due to safe and low cost[14].

First line of imaging is transabdominal ultrasonography to demonstrate the parenchymal changes in the pancreas. Transabdominal ultrasonography provides a comprehensive overview and it is a real time imaging modality. It is noninvasive,

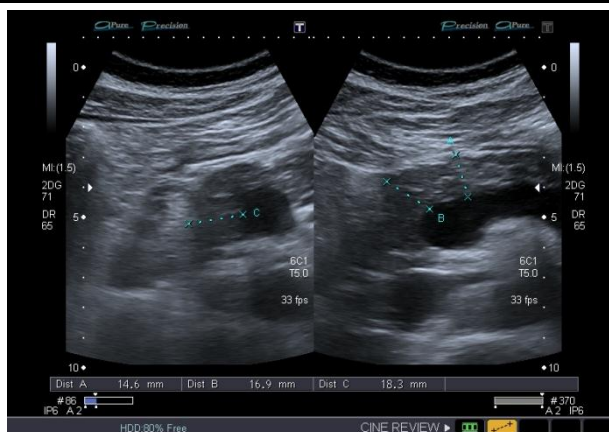
widely available, and inexpensive as compare to other imaging modalities<sup>10</sup>. Possible pancreatic cancer development due to non-alcoholic fatty pancreas disease [15]. On abdominal ultrasound increasing echogenicity of the pancreas (brighter pancreas) represent fatty changes [16]. A study conducted in 2009 by Jun seek lee *et al.* They concluded that sonographic fatty pancreas showed higher insulin resistance than normal pancreas [17]. A study conducted in 2016 in Nigeria by Agabi JO *et al.* AP diameter of the pancreas is smaller in diabetic patient as compared to normal individuals [18]. Individuals of type 1 and type 2 diabetes mellitus have reduced pancreas size as compare to the control subjects[19].

## METHODS

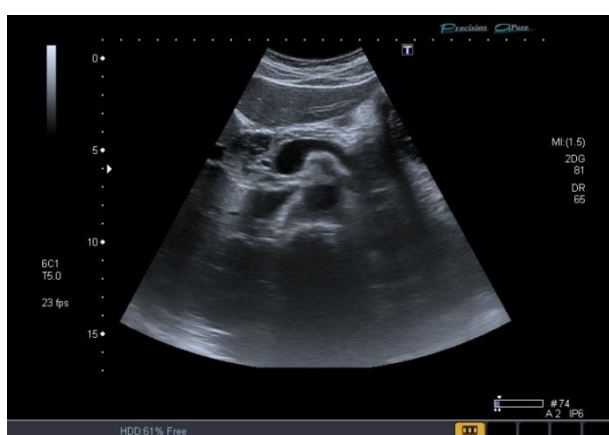A cross sectional comparative study was conducted at Gilani ultrasound Center, Opposite General Hospital Lahore. Our sample size was 150. Non probability sampling procedure will be done. 150 patients were included after approval of synopsis from institutional review Board (IRB). We took 75 diabetic and 75 non diabetic individuals. We took random sugar level of both diabetic and nondiabetic individuals. We used gel and extra compression for better resolution of the image. Toshiba xario was used to compare sonographic appearance between diabetic and nondiabetic individuals and also took the antero posterior (AP) of pancreatic head, body and tail. Pancreatic appearance and its sizes were evaluated on transabdominal ultrasound with frequency probe 2.5 to 5 MHz's. We did repeat scans for few patients who have excessive bowel gases. Data was tabulated and analyzed by SPSS version 21.0.



**Fig-1: In this transabdominal scan. Pancreas is seen fatty and its size also reduced as compare to normal individuals. (Diabetic patient age 53years)**



**Fig-2:** In this scan pancreas is seen fatty due to diabetic history and its size reduced as compare to normal individuals. (Diabetic patient age 48years)



**Fig-3:** This is the normal sonogram of the patient and his age was 50 years. (Pancreatic parenchyma is isoechoic)

## RESULTS

According to 150 patients were in this study (75 diabetic and 75 non diabetic). Pancreatic echogenicity of the diabetic individual's isoechoic patients, count was 22 (29.3%), hypoechoic count was 10 (13.3%) and hyperechoic count was 43 (57.3%). Pancreatic echogenicity of the non-diabetic individual's ISO echoic patients was 7(9.3%), hypoechoic was 68(90%) and hyperechoic pancreas was 0 (0.0%). The result of both diabetic and non-diabetic Individuals whose pancreatic echogenicity was isoechoic its count was 29 (19.3%), hypoechoic was 78(52.0%) and hyperechoic was 43(28.7%) (Table 1).

3, out of 150 patients, diabetic males patients were 35(46.7%) and females were 40 (53.3%) out of 75 individuals. Non diabetic males were 34 (45.3%) and females were 41(54.7%) out of 75 individuals. Total diabetic and non-diabetic males count were 69 (46%) and females were 81 (54%) (Table 2).

150 patients, hyperechoic individuals were 43 (28.7%), hypoechoic were 78 (52%) and isoechoic were 29 (19.3%) in both diabetic and non-diabetic individuals.

According to Mean of the pancreatic tail were  $21.87 \pm 2.41$ mm. The minimum size of the pancreatic tail was 18.70mm and the maximum size was 28.0. The range of the pancreatic tail was 9.30mm. (Table 3).

According to figure 7, Mean of the pancreatic body was  $21.11 \pm 1.92$ mm, the minimum size of the pancreatic body was 14.20mm and maximum size was 26.10mm. The range of the pancreatic body was 11.90.

According to figure 8, Mean of the pancreatic head was  $22.22 \pm 3.13$ mm, the minimum size of the pancreatic head was 13.10mm and maximum size was 32.70mm. The range of the pancreatic head was 19.60mm.

Out of 150 patients, Mean of the sugar level was  $160.58 \pm 66.44$ mg/dl. Minimum level of the sugar was 65mg/dl and maximum were 310mg/dl. The range of the sugar level was 245mg/dl.

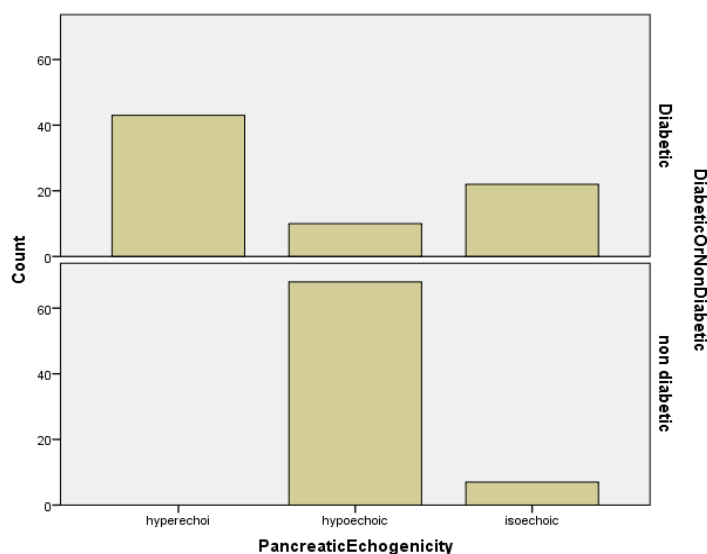
According to figure 10, Out of 150 patients mean age was  $49.91 \pm 3.22$  years. The minimum age was 45years and maximum age was 55years. The range of the age was 10 years. (Table-4).

According to table 4, Non diabetic pancreatic head was in N= 75 its mean was 23.310±3.80. Diabetic pancreatic head was in N= 75 its mean was 21.13±1.68 were significant difference as p-value 0.000< 0.05. Non diabetic pancreatic body was in N= 75 its mean was 22.05±2.06. Diabetic pancreatic body was in N= 75 its

mean was 20.168±1.162 were significant difference as p-value 0.000< 0.05. Non diabetic pancreatic tail was in N= 75 its mean was 23.31±2.49. Diabetic pancreatic tail was in N= 75 its mean was 20.44±1.169 were significant difference as p-value 0.000< 0.05

**Table-1: Pancreatic echogenicity were in both diabetic and non-diabetic individuals with isoechoic count, hypoechoic count and hyperechoic count**

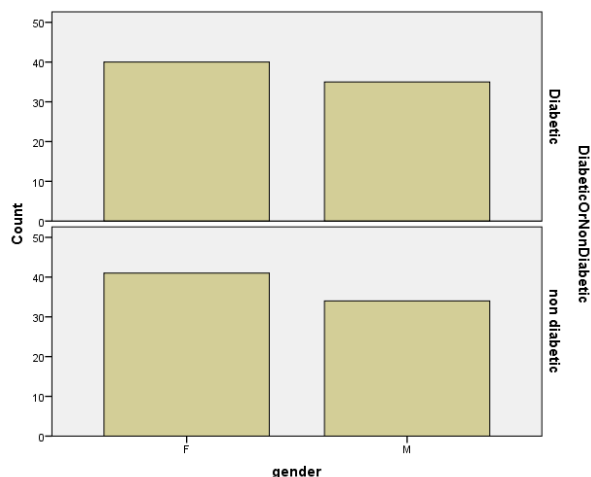
Pancreatic Echogenicity * Diabetic Or Non Diabetic Cross tabulation					
			Diabetic Or Non Diabetic		Total
			Diabetic	non diabetic	
Pancreatic Echogenicity	isoechoic	Count	22	7	29
		% within Diabetic Or Non Diabetic	29.3%	9.3%	19.3%
	hypoechoic	Count	10	68	78
		% within Diabetic Or Non Diabetic	13.3%	90.7%	52.0%
	hyperechoic	Count	43	0	43
		% within Diabetic Or Non Diabetic	57.3%	0.0%	28.7%
Total		Count	75	75	150
		% within Diabetic Or Non Diabetic	100.0%	100.0%	100.0%



**Graph-1: Pancreatic echogenicity of the diabetic and non-diabetic individuals cross tabulation.**

**Table-2: Gender wise distribution**

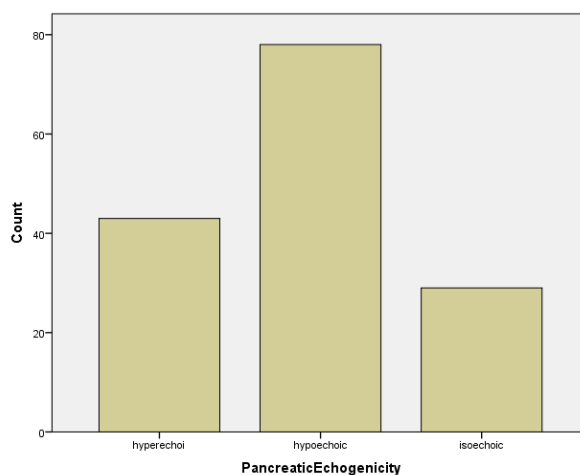
			Diabetic Or Non Diabetic		Total
			Diabetic	Non diabetic	
Gender	Male	Count	35	34	69
		% within Diabetic Or Non Diabetic	46.7%	45.3%	46.0%
	Female	Count	40	41	81
		% within Diabetic Or Non Diabetic	53.3%	54.7%	54.0%
Total		Count	75	75	150
		% within Diabetic Or Non Diabetic	100.0%	100.0%	100.0%



**Graph-2: Gender count of both diabetic and non-diabetic individuals**

**Table-3: Frequency and percentage of pancreatic echogenicity in all individuals.**

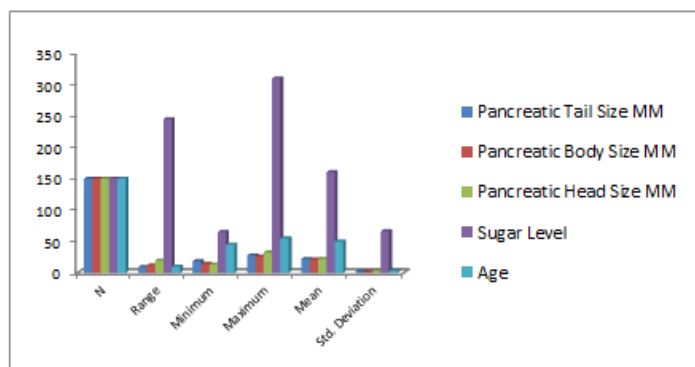
Pancreatic echogenicity	Frequency	Percent
hyperechoic	43	28.7
hypoechoic	78	52.0
isoechoic	29	19.3
Total	150	100.0



**Graph-3: Pancreatic echogenicity in both diabetic and non-diabetic individuals.**

**Table-4: Descriptive statistics of pancreatic tail variables**

Descriptive Statistics						
	N	Range	Minimum	Maximum	Mean	Std. Deviation
Pancreatic Tail Size MM	150	9.30	18.70	28.00	21.8773	2.41706
Pancreatic Body Size MM	150	11.90	14.20	26.10	21.1100	1.92077
Pancreatic Head Size MM	150	19.60	13.10	32.70	22.2240	3.13098
Sugar Level	150	245.00	65.00	310.00	160.5867	66.44271
Age	150	10.00	45.00	55.00	49.9133	3.22727



Graph-4: Descriptive statistics of pancreatic tail variables.

## DISCUSSION

In a current study it was noted that the fatty pancreas is hyperechoic mostly seen in diabetes mellitus and its size should be slightly reduced as compared to a normal pancreas. A study was conducted in Chinese population by Wang CY *et al.* They suggest that both nonalcoholic fatty liver disease and fatty pancreas were strongly associated with diabetes. They also found that fatty pancreas are important associated factors of newly diagnosed diabetes independent of age, gender [20]. A study was conducted in Jakarta Indonesia by Ilesmana CR *et al.* Fatty pancreas is a common finding during medical checkup with a prevalence of 35%. Fatty pancreas has significantly associated with metabolic function and it might have an important role in risk of malignancy [21]. Individuals with type 1 and type 2 diabetes mellitus have reduced pancreas size in comparison with control subjects. Patient with type 2 diabetes mellitus have increased pancreatic fat content [19].

## CONCLUSION

It was concluded that echogenic pancreas on ultrasound is a fatty pancreas. Highly echogenic pancreas is associated with diabetes mellitus (DM). Statistically Significant difference of anterior posterior diameter was found in mean of pancreatic head, body and tail in diabetes and non-diabetes.

## REFERENCES

- Shaw, J. E., Sicree, R. A., & Zimmet, P. Z. (2010). Global estimates of the prevalence of diabetes for 2010 and 2030. *Diabetes research and clinical practice*, 87(1), 4-14.
- Meo, S. A., Zia, I., Bukhari, I. A., & Arain, S. A. (2016). Type 2 diabetes mellitus in Pakistan: Current prevalence and future forecast. *JPMA. The Journal of the Pakistan Medical Association*, 66(12), 1637-1642.
- Longnecker, D. S., Gorelick, F., & Thompson, E. D. (2018). Anatomy, Histology, and Fine Structure of the Pancreas. *The Pancreas: An Integrated Textbook of Basic Science, Medicine, and Surgery*, 10-23.
- Onyeanus, C. G. (2017). *Effect of family support on medication adherence and glycemic control of type 2 diabetes outpatients in a tertiary hospital in south-eastern Nigeria* (Doctoral dissertation).
- Hordern, M. D., Dunstan, D. W., Prins, J. B., Baker, M. K., Singh, M. A. F., & Coombes, J. S. (2012). Exercise prescription for patients with type 2 diabetes and pre-diabetes: a position statement from Exercise and Sport Science Australia. *Journal of Science and Medicine in Sport*, 15(1), 25-31.
- Coccia, P., Ruggiero, A., Attina, G., Maurizi, P., Lazzareschi, I., Molinari, F., & Riccardi, R. (2007). Shwachman Diamond Syndrome: an emergency challenge. *Signa vitae: journal for intensive care and emergency medicine*, 2(2), 10-13.
- Rickes, S., & Malfertheiner, P. (2004). Echo-enhanced sonography—an increasingly used procedure for the differentiation of pancreatic tumors. *Digestive Diseases*, 22(1), 32-38.
- Abid, A., Ahmad, S., & Waheed, A. (2016). Screening for Type II Diabetes Mellitus in the United States: The Present and the Future.
- Adepoyibi, T., Weigl, B., Greb, H., Neogi, T., & McGuire, H. (2013). New screening technologies for type 2 diabetes mellitus appropriate for use in tuberculosis patients. *Public Health Action*, 3(1), 10-17.
- Dimcevski, G., Erchinger, F. G., Havre, R., & Gilja, O. H. (2013). Ultrasonography in diagnosing chronic pancreatitis: new aspects. *World Journal of Gastroenterology: WJG*, 19(42), 7247.
- Jeon, J. H., Kim, J. H., Joo, I., Lee, S., Choi, S. Y., & Han, J. K. (2018). Transabdominal Ultrasound Detection of Pancreatic Cysts Incidentally Detected at CT, MRI, or Endoscopic Ultrasound. *American Journal of Roentgenology*, 210(3), 518-525.
- Cao, A., Eslick, G. D., & Cox, M. R. (2018). Biliary Pain and a Normal Ultrasound. In *The Management of Gallstone Disease* (pp. 147-154). Springer, Cham.
- Gonçalves, B., Soares, J. B., & Bastos, P. (2015). Endoscopic Ultrasound in the Diagnosis and Staging of Pancreatic Cancer. *GE Portuguese journal of gastroenterology*, 22(4), 161-171.

14. Hernaez, R., Lazo, M., Bonekamp, S., Kamel, I., Brancati, F. L., Guallar, E., & Clark, J. M. (2011). Diagnostic accuracy and reliability of ultrasonography for the detection of fatty liver: a meta-analysis. *Hepatology*, 54(3), 1082-1090.
15. Lesmana, C. R., Gani, R. A., & Lesmana, L. A. (2018). Non-alcoholic fatty pancreas disease as a risk factor for pancreatic cancer based on endoscopic ultrasound examination among pancreatic cancer patients: A single-center experience. *JGH Open*, 2(1), 4-7.
16. Obora, A., Kojima, T., Kato, T., Endo, M., Miyawaki, K., Fukuta, N., ... & Hamaguchi, M. (2012). Associations between Bright Pancreas and Features of Metabolic Syndrome. *人間ドック (Ningen Dock)*, 26(6), 935-943.
17. Lee, J. S., Kim, S. H., Jun, D. W., Han, J. H., Jang, E. C., Park, J. Y., ... & Kim, Y. S. (2009). Clinical implications of fatty pancreas: correlations between fatty pancreas and metabolic syndrome. *World journal of gastroenterology: WJG*, 15(15), 1869.
18. Agabi, J. O., & Akhigbe, A. O. (2016). Comparative sonographic evaluation of the anteroposterior dimensions of the pancreas in diabetics and nondiabetics. *Nigerian journal of clinical practice*, 19(2), 176-181.
19. Garcia, T. S., Rech, T. H., & Leitão, C. B. (2017). Pancreatic size and fat content in diabetes: A systematic review and meta-analysis of imaging studies. *PloS one*, 12(7), e0180911.
20. Ou, H. Y., Wang, C. Y., Yang, Y. C., Chen, M. F., & Chang, C. J. (2013). The association between nonalcoholic fatty pancreas disease and diabetes. *PloS one*, 8(5), e62561.
21. Meo, S. A., Zia, I., Bukhari, I. A., & Arain, S. A. (2016). Type 2 diabetes mellitus in Pakistan: Current prevalence and future forecast. *JPMA. The Journal of the Pakistan Medical Association*, 66(12), 1637-1642.