

Devices and Special Designs for Oral and Maxillofacial Use

Dr. Alberto Andrade-Guerra^{1*}, Dr. Marielba Campos²

¹Oral Surgeon, Former Professor, West Hospital at Caracas, Venezuela

²Former Professor, General Practice, Central University, Venezuela

Original Research Article

*Corresponding author

Dr. Alberto Andrade-Guerra

Email:

aagve@yahoo.com

marielbacampos@yahoo.com

Article History

Received: 02.10.2018

Accepted: 13.10.2018

Published: 30.10.2018

DOI:

10.21276/sjodr.2018.3.10.4



Abstract: With this work it has been wanted to demonstrate that the reconstruction of any person, does not have limits. We have absolutely all and each of the tools to solve problems of aesthetic nature to patients. Many of these tools should be manufactured individually for a particular case. Oral and Maxillofacial Surgery and Cosmetic Surgery should not be divorced from Maxillofacial Prosthesis. The resolution of three cases is presented with prostheses specially made for a particular person, with their own measures and forms. It will be very comforting for each person to know that they have reached the exact place where they solve their aesthetic problem with special devices built for them. We have worked together with the surgeon and the prosthetist in order to study each case and build the most appropriate device for the type of problem to be solved. A work team will be essential to achieve excellence, because it represents a new alternative of care

Keywords: Oral, Mouth, Surgery, Devices, Reconstruction, apparatus, Maxillofacial, build, aesthetics, distraction, Osteogenesis, implants, prosthesis, combined treatment, combined devices, Appliances, Team

INTRODUCTION

There are cases in which it is very necessary to design a special device that leads to the resolution of a problem that is not usual at the private level, but very common at the hospital level.

We reiterate once again that we will never criticize the devices that have already been prefabricated and existing in the market. Nor are we going to say that they solve half the problems that are presented to us.

What is wanted is that it be understood that it does not exist as a device manufactured individually for a particular patient that has the dimensions and specifications for each person.

We have discovered that many times the devices that are available in the market, are not going to execute the work that we are looking for and we will necessarily have to go to individual jobs such as those that we want to show.

It is important to say that the design of Maxillofacial Devices dates back a long time. There is nothing empirical about our jobs. Our experimentation goes back years and we have chosen the best materials with specifications demanded by both the ASTM and the ADA. We also worry about choosing the best manufacturers that comply with the entire professional protocol so as not to give reasons for even thinking about an experimentation and taking advantage of each person's problem [1].

The important thing will be to design the right device, always using our inventiveness, so that the best

device that comes to execute what we want is generated.

The present work will deal with maxillofacial prostheses. Those who will provide us with support to dedicate ourselves to the reconstruction facial that make a person without complexes and incorporated into society [2].

It is propitious to mention the words of Dr. Gavril Ilizarov, who insisted on not being satisfied and thinking about the excellence of the treatments [3].

What is wanted is to show that we should not settle for an existing oral device that we will know in advance, that will not give us the desired results. That is why the manufacture of an individual design with measures and forms for a particular patient is commissioned.

It is not desired at any time, to underestimate the benefits of a device manufactured in series or prefabricated, which have been used by the best surgeons in the world. What this work is about is that

we have the best weapons to improve and modify the existing.

It will not be suitable or sympathetic for a patient who, with so much hope, comes to us, having to say that "there is no" an adequate device to solve their problem, even more, if we have been recommended and recognized as exceptional and infallible. This patient will not understand that in this era of so much technology, there is no solution for him. We will not want to lose it or go to other surgeons in other countries capable of facing the problem they suffer. We will be left very badly unemployed if another surgeon from another offers a solution, even more, if it is outside our borders.

The right thing to do is to show you that we own technology and demonstrate to him and the world, our ability.

That is why we insist on achieving the excellence of our treatments. That is why we go to the imagination and make an individual device that gives us pride and excellent results.

We want to insist once again that at no time are we going to pretend to experiment and even less in patients or our fellow human beings. Such conduct is not honest and incompatible with our procedures. What is manufactured are artifacts that help the operator to carry out a proven work.

MATERIALS AND METHODS

For the manufacture of prostheses, we have used a "Peerless" brand lathe made in the United States.

Computed Axial Tomography (CAT SCAN) has been very useful for us. Without it, it is impossible to carry out our work, since it will provide us with the exact dimensions of our patient.

It has been used titanium material whose formula is Ti90Al6V4 certified by the supplier, who guarantees that this alloy is the one that is supplied to us and thus we comply with all the norms and requirements of the ASTM and the ADA.

Now, based on our experience in the design of bone devices that induce osteogenesis, we have built

prostheses that come back to give the patient the quality of life they have lost.

The aesthetic factor and the incorporation of our patient into society has been extremely important. It is known that the face is the card of presentation of every person and we are concerned about the psychological rejection that occurs when a person has a defect.

It is for this reason that we have moved to perform a facial reconstruction through the manufacture of a prosthesis and not stay on the road relieving the reconstructive function and leaving it to a third party without a suggestion.

Remember that our work deals with the prosthetic inventiveness, not only the surgical one and it will not be complete until we look at a person who was treated in an integral way by us and who went to seek our help in a personal way.

Our designs have a good dose of hand finishing that makes them an attractive aesthetic appearance and a working condition and ideal functionality. We are ever careful in the principles of fabrication [6].

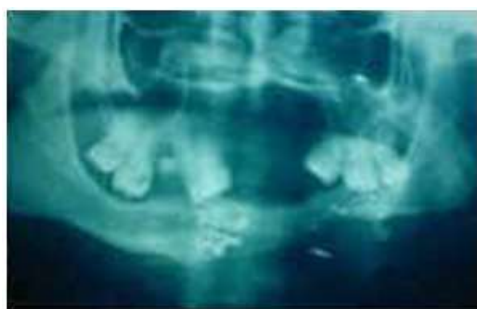Description of Cases

Case No. 1

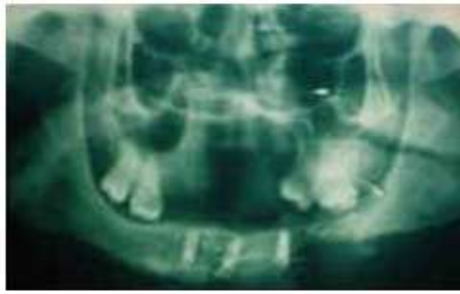A 48-year-old male patient with a missing mandibular body was presented to us as he received a gunshot wound.

To this patient the mandibular bone was reconstructed with an autologous rib graft and mini implants were placed in its center so that on them a tangential bar could be made that will support the prosthesis.

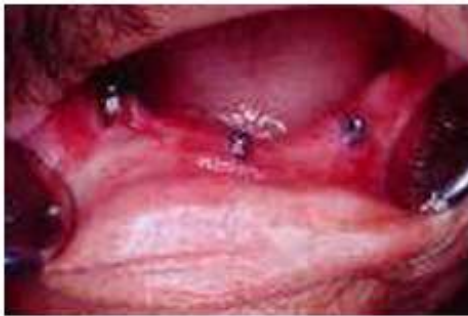This patient did not have the conventional long and wide implants since they were not the ones indicated and that is why some devices were manufactured with special measures that fulfilled their purpose of being placed in the thickness of a rib and being able to receive phase two, an artificial stump [4-9].



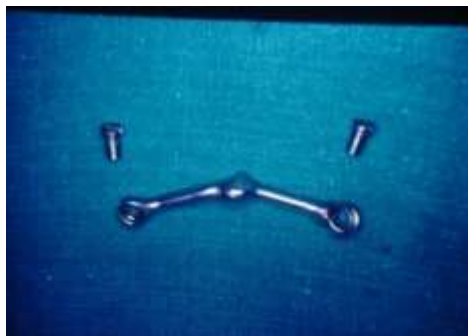Photograph No. 1: The lack of the body of the mandible



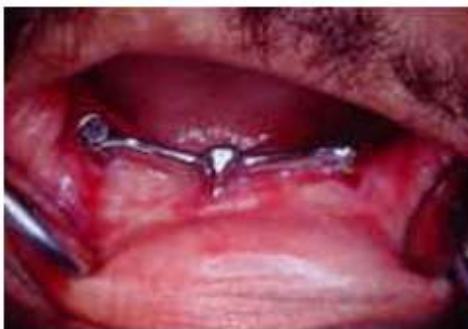Photograph No. 2: The more similar bone is the rib. We manufacture three implants for it



Photograph No. 3: Implants Emerging in the oral cavity



Photograph No. 4: The Tangential bar has been made



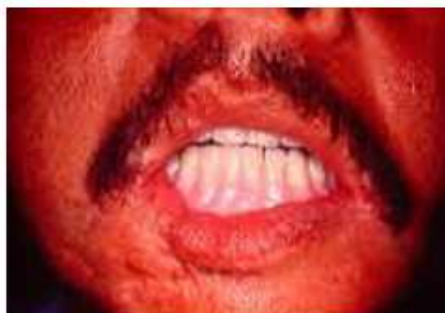Photograph No. 5: The Tangential bar is correctly placed in the mouth

We can clearly see in Photograph No. 1, the lack of the mandibular body and the state in which the patient is presented looking for our professional help.

In Photograph No. 2, we can see that three implants have been positioned in the implanted rib, ordered to be made according to the individual measurements.

In Photograph No. 3 the placement of implants that protrude into the oral mucosa. Once the special abutments have been placed.

In Photograph No. 4 we see the type of tangential bar that was made for this patient that is fixed with two screws for the distal implants. The implant that is in the middle, is used as support, without screw.



Photograph No. 6: The actual appearance

In Photograph No. 5 the bar in position, made to measure and in the buccal area. In photograph No. 6, we appreciate the total reconstruction of the patient and his appearance after having made a prosthesis in a directed way.

Case No. 2

It is a male patient with total absence of the pinna on the left side [6, 10, 11].

Always thinking about the osseointegration, the biointegration and the titanium material that is discovered to be highly biocompatible, we plan to make special Osseointegrated implants in order to position

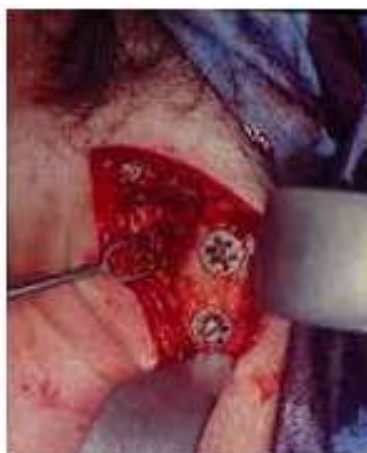them in such a way that they make contact with as much bone as possible since they will be designed for the temporal bone and that they will act as a support that will carry a prosthesis.

These implants had to be very short and to look for a greater bone-metal bone contact, a perforated fin is manufactured to generate the desired osteogenesis (Photograph No. 1).

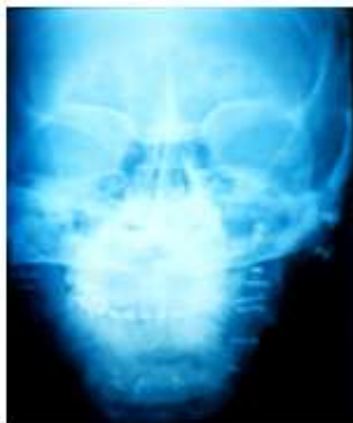In this way it has been possible to eliminate the facial defect and eliminate all kinds of complexes that our patient may have.



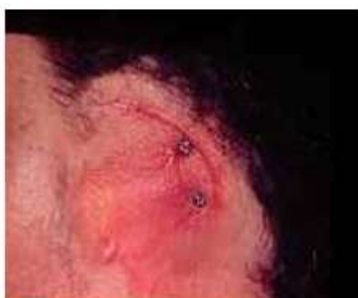Photograph No. 7: The Implants should be short and to get the maximum contact with temporal bone, a perforated fin has been manufactured



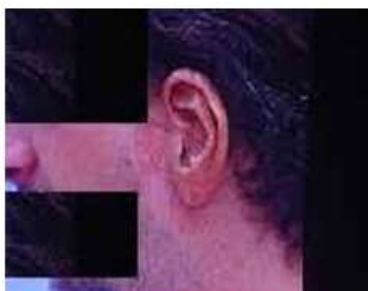Photograph No. 8: Only two implants are enough to make the prosthesis



Photograph No. 9: The X-Ray shows the implants placed in temporal bone



Photograph No. 10: The implants emerging in the skin



Photograph No. 11: The prosthesis in position

In photograph number 7 we can see the type of implants that are made for this patient. Given that they are implants made for the temporal bone, they will be designed very short taking into account the thickness of the temporal bone by means of the tomography, they present, as already said, a type of fin with six perforations that will be in contact with the temporal bone once positioned.

In photograph number 8 corresponds to the surgical moment in which the osseointegration implants are individually made for our patient.

In photograph number 9 we can see in an anteroposterior radiograph the implants placed in the left temporal bone, in quantity of two.

In photograph No. 10 the super structure that emerges to the skin is observed, on which a tangential bar will be built in which, screwed on the implants, it will be able to hold the prepared prosthesis taking into account the size and color of the implant natural skin of the patient (Photograph No. 11).

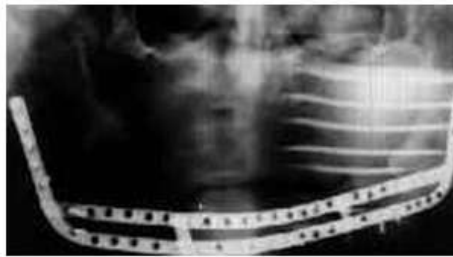
Case No. 3

These last cases refer to mandibular losses due to pathologies. We present a total absence of mandibular body to whom a prosthesis was made that is planned to be screwed into the remnants of ascending branches that the person presents [6].

Another patient is given a hemimandible. Both patients are restored the harmony and fullness of the face, so necessary for them to join society.



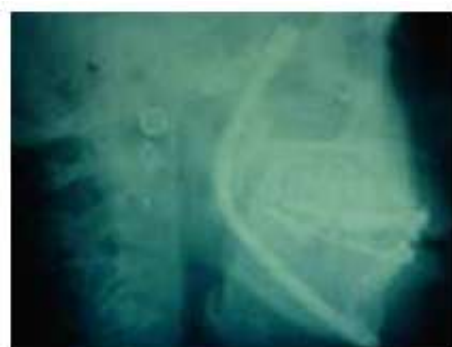Photograph No. 12: A complete titanium mandible is constructed



Photograph No. 13: The prosthesis is placed as we return the natural silhouette of the face



Photograph No. 14: The titanium Prosthesis is made following the forms and individual measurements



Photograph No. 15: The prosthesis located in correct position

In photographs No. 12 and No. 13, we can see the prosthesis made for a patient with total loss of the jaw and radiography when it has been positioned.

Similarly, we can see in photographs No. 14 and No. 15, when both correspond to a total absence of the right hemimandibula. The prosthesis is made with a

condyle and manufactured according to tomographies and individual measurements.

RESULTS & DISCUSSION

We have achieved results that purely with maxillofacial surgery, we can not get.

It is mandatory to go to the maxillofacial prosthesis to solve the surgical drama presented by a person.

If we think of placing ourselves in the footwear of patients with facial defects that come to us daily, we will not spare any expense or diligence if they appear effective and compatible with each person.

That is why we have one more weapon that has resulted in another alternative to attack effectively and deal with each case [2].

We go to our inventiveness and intellect, which, added to our experience and training in the area, we achieve in most cases, a 100% solution.

We will never say that existing and mass produced devices produce half results. We just want to say that there will never be a device manufactured individually, because they act in a way that gives us maximum effectiveness.

CONCLUSIONS

- We determine the effectiveness and complementation of our treatments by not having to go to third persons who, in many cases, are far away from us and the patient.
- We have developed treatment techniques based on our experiences and knowledge of each case in particular [12].
- We have also developed our intellect and inventiveness that will allow us to treat each person as something different from the others. Each case is different from the other [13].
- We have determined that the maxillofacial surgery and the maxillofacial prosthesis can not go divorced. It is our case that given the weapons that we have in the same place, it is much easier for us to channel the patient and to direct very effectively the problem that is presented to us.
- We have set ourselves the goal of being able to help everyone who seeks us by having all the necessary tools. We have proposed to treat each person effectively [2].
- We do not want to think about a type of experimentation. We will always be designing devices that represent another alternative treatment.
- All cases have been carried out by expert surgeons who have worked together with us to design the

best device individually and taking into account the bone shapes and measurements of each patient.

REFERENCES

1. Andrade-Guerra, A. (1999). Independent Simultaneous Bilateral Expansor Device. Distraction Osteogenesis. Interactive Course on CD ROM Global Mednet.
2. Casillas, L. A. (1971). Máquinas. Cálculos de Taller. Hispanoamericana. 25 Ed. Spain.
3. Ilizarov, G. (1992). Transosseous Osteosynthesis Reprint 1st ed.
4. Andrade-Guerra, A., & Lander, A. (1999). Corrections of Mandibular Bone Height and Width Using Distraction Osteogenesis Appliances. Distraction Osteogenesis. Interactive Course on CD ROM. Globalmednet.
5. Andrade-Guerra A. (1997). Diseño, Fabricación y Empleo de un sistema de Implantes Fabricados en Venezuela. *Odontología al Día*.
6. Tjellstrom, A., & Magnus, J. (1994). The Bone Anchored Maxillofacial Prosthesis, *Journal of Oral and Maxillofacial Surgery*, 235.
7. Garg, A. (1998). Oral Implantology course.
8. Bell, W. H., Harper, R. P., Gonzalez, M., Cherkashin, A. M., & Samchukov, M. L. (1997). Distraction osteogenesis to widen the mandible. *British journal of oral and Maxillofacial Surgery*, 35(1), 11-19.
9. Guerrero, C. A., Bell, W. H., Contasti, G. I., & Rodriguez, A. M. (1997). Mandibular widening by intraoral distraction osteogenesis. *British Journal of Oral and Maxillofacial Surgery*, 35(6), 383-392.
10. Wallace, S. (1990). Beyond Osseointegration; A periodontal perspective. *Irvine CA, Intepore International*.
11. Hamata, M. M., Yunomae, A., Cestari, T. M., de Assis, G. F., & Taga, R. (2004). A stereological analysis of the heterotopic osteogenesis induced by allogenic bone matrix grafts in rat subcutaneous tissue. *Braz J Morphol Sci*, 21(2), 81-8.
12. Andrade-Guerra, A. (1999). Tratamiento Combinado: Implantología y Distracción Osteogénica. *Revista Española Odontostomatológica de Implantes*. 4(7), 171-174.
13. Andrade-Guerra, A. (1997). Diseño y Fabricación de un Dispositivo Terminal Intermedio en Tenedor para la Fijación del Tornillo Expansor de Tipo Hirax. *Venezuela Odontológica*. Etapa II. Año 1. N° 1: 5-7.