

Original Research Article**Management of Deep Sternal Wound Infections: Open Dressing versus Vacuum Assisted Closure Device Therapy - An Institutional Experience**Sohal Ravdeep Singh¹, Satish Kumar Mishra^{2*}, Pushkarna Amit³, Nagi Gagandeep Singh⁴, Keshing Chuimei⁵, Sidhu HS⁶¹MS, Asst Prof, MCh, Cardiothoracic Surgery, Department of Cardiothoracic Surgery²MD, DM, Asst Prof, Cardiothoracic Anaesthesia, Department of Cardiothoracic Anaesthesia³MS, MCh, Asst Prof Cardiothoracic Surgery, Department of Cardiothoracic Surgery⁴MS, MCh, Prof Cardiothoracic Surgery, Department of Cardiothoracic Surgery⁵MS, MCh, Asst Prof, Cardiothoracic Surgery, Department of Cardiothoracic Surgery⁶MD, Prof, Department of Pathology^{1,3-5}Military Hospital Cardio Thoracic Centre, Pune, Maharashtra, India²Command Hospital Airforce Bangalore (CHAfB) Karnataka, India***Corresponding Author:**

Satish Kumar Mishra

Abstract: We present an ambispective analysis of the Management of Deep Sternal Wound Infections: Open Dressing versus Vacuum Assisted Closure Device Therapy at our Institute. **Aim:** The aim of our study is to compare and analyse our experience of Management of Deep Sternal Wound Infections with Open Dressing and Vacuum Assisted Closure Device Therapy and outcome. **Methods:** We analysed and compared our data (Group I) from 01 May 2009 to 31 May 2012 when the modality of management of DSWI was open dressings and irrigation (ie; Pre-VAC era at our institute) with data (Group II) from 01 May 2013 to 31 Apr 2016 when the modality of management of DSWI was changed to Vacuum Assisted Closure Device Therapy. 2228 patients underwent sternotomies from 01 May 2009 to 31 May 2012 and 2168 patients underwent sternotomies from 01 May 2013 to 31 Apr 2016. In Group I postoperative DSWI was diagnosed in 22 patients there were 14 (63.63 %) Males aged 45 to 81 years and 08 (36.37 %) Females aged 43 to 71 years, and in Group II postoperative DSWI was diagnosed in 20 patients. There were 11 (55 %) Males, aged 39 to 74 years and 09 (45 %) Females aged 44 to 66 years. The outcomes were investigated with Kaplan-Meier method, log-rank test, Student's test and Fisher's exact test. **Results:** In Group I - 17 (77.27 %) patients underwent secondary suturing with tension bands and 01 (4.5 %) patient required flap cover to cover the defect. The mortality was 04 (18.18 %) (03 Male and 01 Female), whereas in Group II- 16 (80%) patients underwent Secondary suturing with tension bands and 02 (10 %) patient required flap cover to cover the defect. The mortality was 02 (10%) (01 Male and 01 Female). **Conclusion:** As compared to open dressings and irrigation, VAC therapy is safe and reliable option in Deep sternal wound infection after cardiac surgery, with excellent survival and low failure rate. VAC reduces mortality, increases sternal stability, patient comfort and can be used in any Hospital. Pre-operative Diabetes Mellitus, Renal Failure and Obesity are risk factors for mortality in patients treated with both modalities.

Keywords: Deep Sternal Wound Infection (DSWI), Vacuum Assisted Closure Therapy (VAC), Wound Debridement, Cardiac Surgery.

INTRODUCTION

Post-sternotomy mediastinitis or deep sternal wound infection (DSWI) is a rare but a potentially devastating and life threatening complication following cardiac surgery often leading to prolonged hospital stay and higher mortality [1-3]. Despite many advances in prevention and perioperative care, DSWI remains a pressing concern in cardiac surgery, with a still relevant incidence and a considerable impact on in-hospital mortality and also on mid- and long-term survival [4]. The permanent high impact of this complication is partially related to the increasing proportion of patients at

high-risk for infection. The incidence of post cardiac surgery sternal wound infection and mediastinitis rate has been reported between 0.8 and 5.0% more so in diabetic patients, the mortality rate varies from 20 % to 30% in different sets of cardiac surgical patients [5-7]. Established treatment involves a combination of debridement followed by open packing or closed irrigation, primary or delayed closure, flap reconstruction, re-wiring and irrigation together with antibiotic therapy as per sensitivity of infection. In the last decades several treatment modalities have been described, of which vacuum-assisted closure (VAC) shows the most

promising results [8-10]. Emerging evidence of the efficacy and safety of VAC either as a single-line therapy, or as a “bridge” prior to final surgical closure has been established with promising results as compared to conventional treatment that has disadvantages such as destabilization of the sternum, prolonged immobilization and concomitant infections, that may complicate this fatal treatment period in poststernotomy mediastinitis that are also called deep sternal wound infections by various studies [12-16]. The aim of our study is to share our experience in Management of Deep Sternal Wound Infections with Open Dressing and irrigation versus Vacuum Assisted Closure Device Therapy and its outcome at our Centre.

Methods

We did a ambispective analysis after establishing a study design and protocol, approved by the ethics committee at our institution and compared our data (Group I) from 01 May 2009 to 31 May 2012 when the modality of management of DSWI was open dressings and irrigation (ie; Pre-VAC era at our institute) with data (Group II) from 01 May 2013 to 31 Apr 2016 when the modality of management of DSWI was changed to Vacuum Assisted Closure Device Therapy. 2228 patients underwent sternotomies from 01 May 2009 to 31 May 2012 (Group I) and 2168 patients underwent sternotomies from 01 May 2013 to 31 Apr 2016 (Group II). In Group I postoperative DSWI was diagnosed in 22 patients, 14 (63.63 %) Males aged 45 to 81 years and 08 (36.37 %) Females aged 43 to 71 years, and in Group II postoperative DSWI was diagnosed in 20 patients, 11 (55 %) Males aged 39 to 74 years and 09 (45 %) Females aged 44 to 66 years

Inclusion and Exclusion Criteria

Only patients with mediastinitis, those consisting of sternum and presternal tissue infection were included in the present study. Patients undergoing thoracic aortic surgery, congenital heart surgery were excluded from the study.

Rate of infection: In Group I: 22 patients (0.98 %) and in Group II: 20 patients (0.92 %) postoperative mediastinitis was diagnosed, based on the guidelines of Centre for Disease Control and prevention [17, 18]. Wound classification was defined and diagnosis required at least one of the following criteria:

- (1) Culture positivity for organism from mediastinal tissue or fluid;
- (2) Evidence of mediastinitis was seen during operation; or
- (3) One of the following conditions, chest pain, sternal instability (detachment), or fever ($>38^{\circ}\text{C}$) was present and there was either purulent discharge from the mediastinum or an organism isolated from blood culture or drainage culture from the mediastinal area.

Patients' characteristics were analysed ambispectively [19]. Group I patients were treated with Open dressings and irrigation and Group II patients were treated with VAC after initial wound debridement with removal of exposed or all sternal wires (Fig 1). In Group II the treatment modality was performed using the KCI system (KCI, San Antonio, Texas), with a vacuum pressure between 100 mmHg to 150 mmHg (Fig 2).

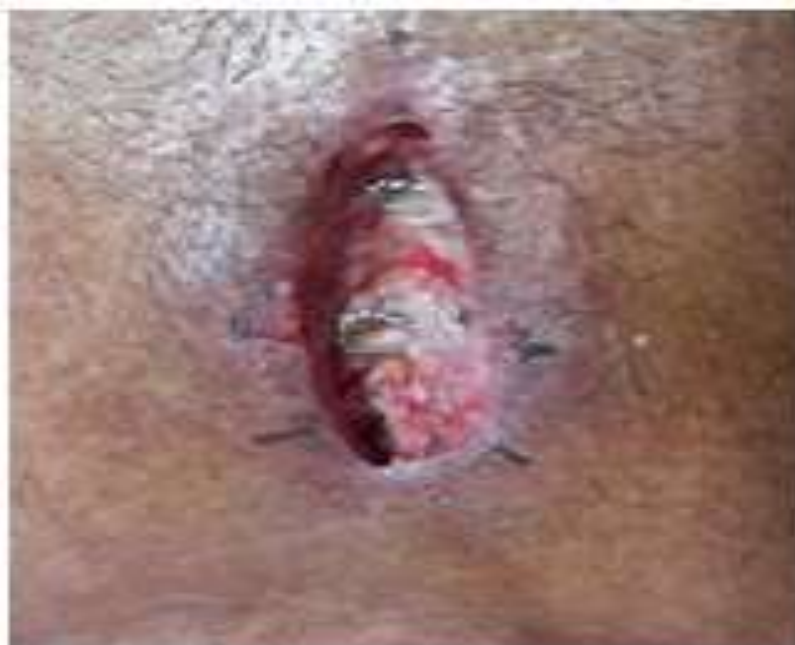

Fig-1



Fig-2

In Group I: the wound was managed with daily dressings and wound irrigation initially twice daily for 1st week, followed by once daily dressing. Wound debridement was performed once a week.

In Group II: the wound-healing technique is based on application local negative pressure to a wound [12]. This is achieved by placing polyurethane foam with an open pore structure of 400–600 μm in the wound. One end of a non-collapsible tube is then connected to the foam and the other end is connected to a vacuum-source in a closed system via connected to a fluid container. The foam and the entire wound are covered with an adhesive

drape thus ensuring an air-tight system (Fig 3&4). Finally, a predetermined, intermittent, negative pressure is applied to the wound. Debridement and exchange of the sponge was performed every 72 to 96 hours in the operation theatre. Substernal tissue cultures were collected for microbiological investigation and determination of the antibiotic resistance pattern. The wound was revised during VAC exchanges with sharp limited wound debridement and necrotic bone was removed if necessary, avoiding extensive sternectomy. Some required multiple wound debridement and VAC reapplication. Afterwards surgery for primary closure of the sternum was performed.



Fig-3

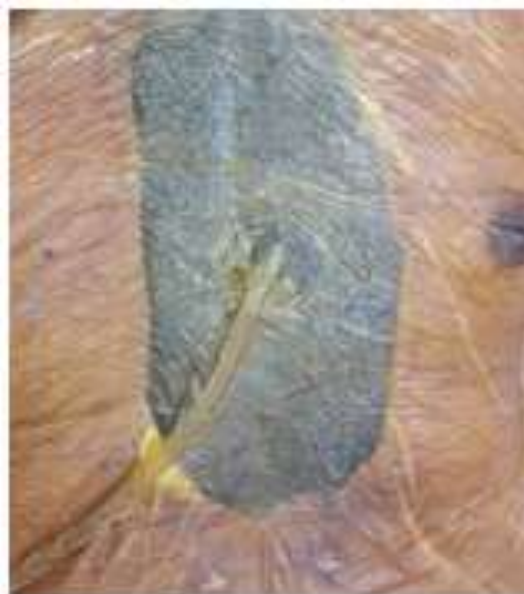

Fig-4

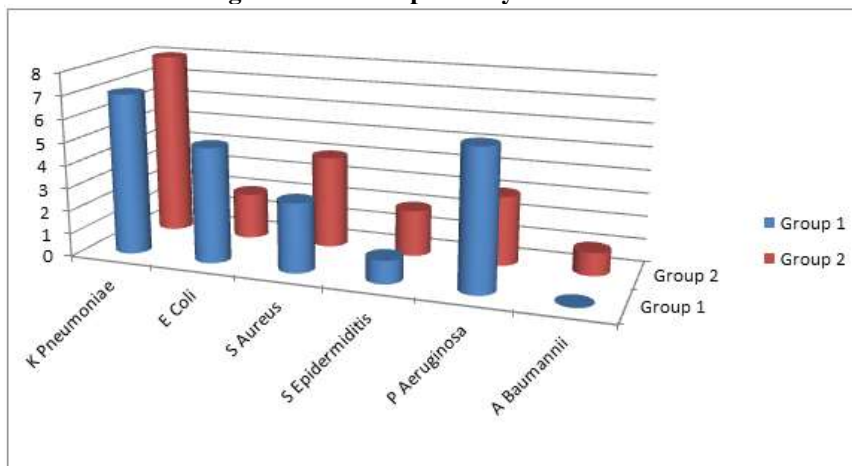
All patients prior to their primary operation received standardized preoperative antibiotic prophylaxis with two doses of intravenous Ceftriaxone 1 gm, on the day of operation and the first postoperative day. When the DSWI was diagnosed, the antibiotic therapy usually commenced with (Tazobectum + Piperacillin) 4.5 gm

intravenously and continued until the results of the wound cultures became available. The entire panorama of pathogens is presented in (Table 1&2). Thereafter, the antibiotic therapy was adjusted according to bacterial sensitivity and strain.

Table-1: Bacteriological spectrum (%)

Bacterial Strain	Group I		Group II	
	n	%	n	%
<i>K.pneumoniae</i>	07	31.8	08	40
<i>E.coli</i>	05	22.7	02	10
<i>S.aureus</i>	03	13.6	04	20
<i>S. epidermiditis</i>	01	0.45	02	10
<i>P.aeruginosa</i>	06	27.27	03	15
<i>A.baumannii</i>	-	-	01	05

Table-2: Pathogens in Culture positivity of sternal wound infection



The preoperative variables were collected from the department's database. In addition, risk factors considered relevant to poor wound healing and enhanced risk for sternal detachment, such as diabetes mellitus, obesity, low left ventricular ejection fraction (LVEF), chronic obstructive pulmonary disease (COPD), elderly age, renal failure, emergency surgery, re-do surgery, re-exploration, post perfusion syndrome, prolonged mechanical ventilation, prolonged intensive care unit (ICU) stay, prolonged use of inotropic drugs and immunosuppression therapy were collected from patients' medical records [20-22].

STATISTICAL ANALYSIS

The assessment of study data was investigated and the distribution of categorical measurements according to the frequency and percentages was done to describe our numerical parameters with mean and standard deviations. The survival function was calculated using the Kaplan-Meier method in both groups. The nonparametric survival functions were then compared using the log-rank test. The two-sample Student's test

was used to evaluate continuous variables. For categorical variables, Fisher's exact test was applied. The results were evaluated at a significance level of $p < 0.05$.

RESULTS

Demographic data and clinical characteristics of the patients are presented in (Table 3). In Group I: patients were counted from 2228 patients who underwent a cardiovascular surgery. The incidence of mediastinitis was found in 22 patients (0.98 %), and in Group II: patients were counted from 2168 patients who underwent a cardiovascular surgery. The incidence of mediastinitis was found in 20 patients (0.92 %). Wound swab cultures showed the presence of *K.pneumoniae* in the majority of patients. The preoperative risk factors relevant to poor wound healing were as per (Table 4). In Group I: Median hospital stay was 43 ± 7 and the treatment duration was 31 ± 10 days, whereas in Group II: Median hospital stay was 35 ± 6 and the treatment duration was 26 ± 9 days, when the modality of management of DSWI was changed to Vacuum Assisted Closure Device Therapy.

Table-3: Patients characteristics

Variable	Group I		Group II	
	Numbers	%	Numbers	%
Total Patients	22	100	20	100
Male	14	63.63	11	55
Female	08	36.37	09	45
Valvular Procedure	04	18.18	03	15
CABG or Combined procedure	18	81.81	17	85
NYHA Class III-IV	19	86.36	17	85
Age > 65 yrs	10	45.45	08	40
Obesity (BMI \geq 30)	10	45.45	11	55
EF \leq 30%	14	63.63	12	60
COPD	05	22.72	05	25
Emergency surgery	05	22.72	04	20
Re-do surgery	03	13.63	02	10
Re-exploration	06	27.27	03	15
Post perfusion syndrome	04	18.18	05	25
Prolonged mechanical ventilation (> 72 h)	15	68.18	13	65
ICU stay > 5 days	18	81.81	16	80
Renal failure*	05	22.72	03	15
Prolonged use of inotropic drugs (>72 h)	16	72.72	15	75
Immunosuppression	01	04.54	01	05
Prolonged use of inotropic drugs (>72 h)	16	72.72	15	75
	Mean	SD	Mean	SD
CPB time (minutes)	131	33.08	128	32.12
X-clamp time (minutes)	105	32.11	103	31.30
Age (y)	62.58		62.58	

*Serum creatinine >1.3 mg/dl.

VAC = Vacuum-assisted closure; CABG = Coronary artery bypass graft; BMI = body mass index; LVEF = left ventricular ejection fraction; NYHA = New York Heart Association; COPD = chronic obstructive pulmonary disease; CPB = cardiopulmonary bypass.

Table-4: Statistically significant risk factors

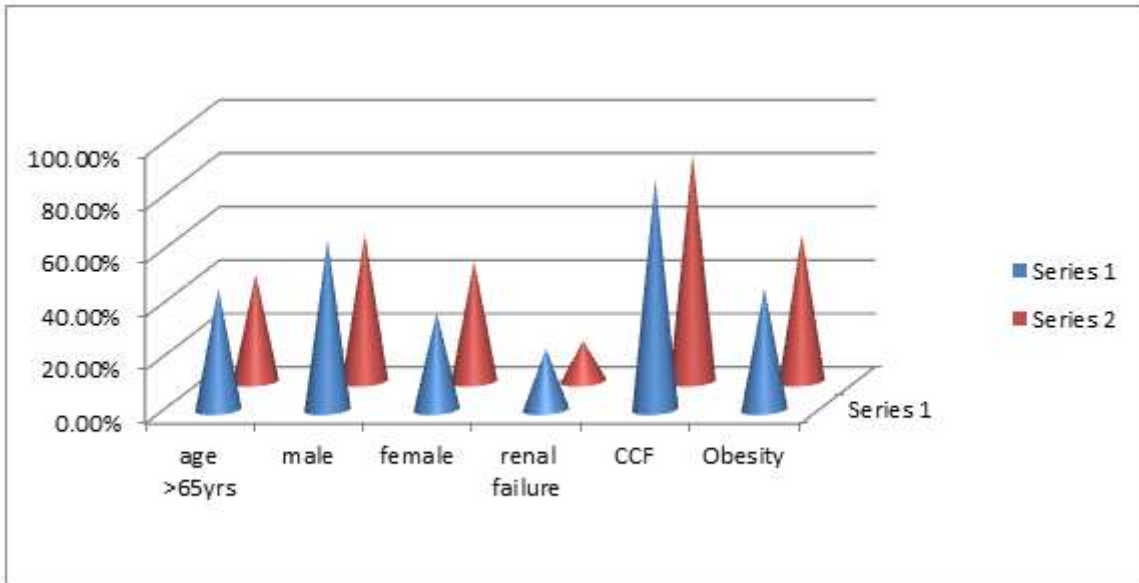


Table-5: Comparative variables

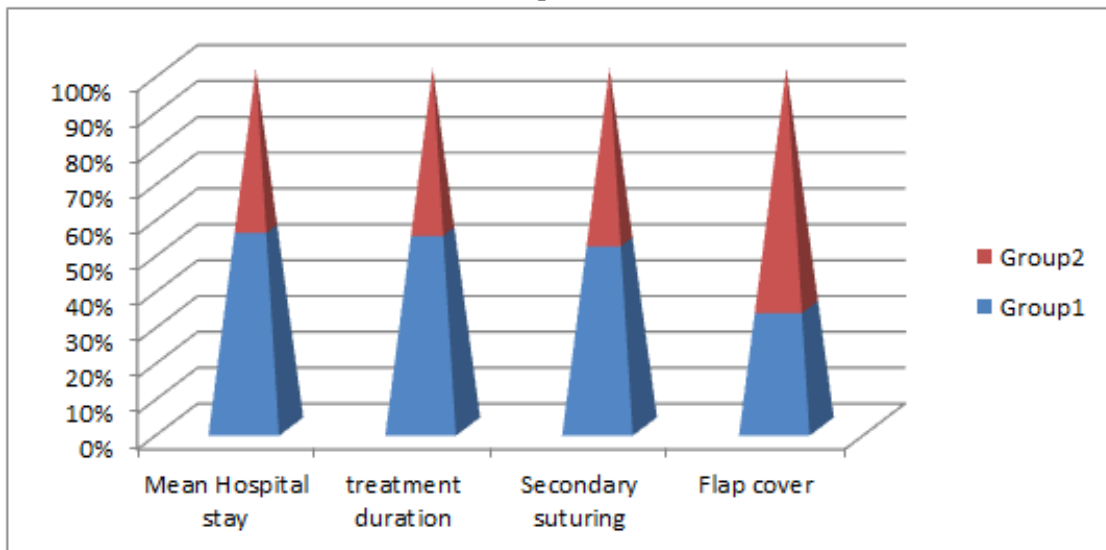
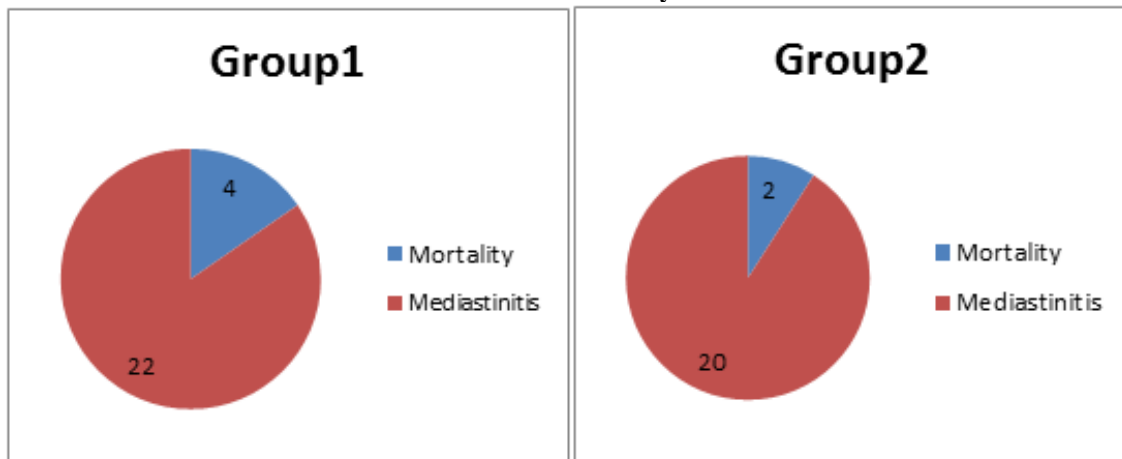


Table-6: Mortality



Group I: There were 14 (63.63 %) Males aged 45 to 81 years and 08 (36.37 %) Females aged 43 to 71 years. Mean age of patients was 64.34 years. 17 (77.27 %) patients underwent Secondary suturing with tension bands and 01 (4.5 %) patient required flap cover to cover the defect, after 3 consecutive bacteriologic cultures from substernal tissue became negative (Table 5). The mortality was 04 (18.18%) (03 Male and 01 Female), cause being multiorgan failure caused by severe sepsis (Table 6). 17 (77.27%) had undergone coronary artery bypass revascularization, 04 (18.18%) isolated valvular procedure and 01 (4.545%) combined valvular and coronary bypass procedures.

Group II: There were 11 (55 %) Males aged 39 to 74 years and 09 (45 %) Females aged 44 to 66 years. Mean age of patients was 62.58 years. 16 (80%) patients underwent Secondary suturing with tension bands and 02 (10 %) patient required flap cover to cover the defect, after 3 consecutive bacteriologic cultures from substernal tissue became negative (Table 5). The mortality was 02 (10%) (01 Male and 01 Female), cause being multiorgan failure caused by severe sepsis in both cases (Table 6). 15 (75%) had undergone coronary artery bypass revascularization, 03 (15%) isolated valvular procedure and 02 (10%) combined valvular and coronary bypass procedures.

DISCUSSION

According to the literature, the incidence of post sternotomy mediastinitis has been variously reported as between 0.8 and 5.0% in different series of adult cardiac surgical patients. Our findings correlate with those of guidelines of the Centre for Disease Control. In this study we found the incidence of post sternotomy mediastinitis at a rate of 0.95 %.

Sternal wound infection was initially treated with surgical revision, with or without multiple open dressing changes that have been previously reported with high mortality rates and has major disadvantages ie; sternal instability which requires mechanical ventilation, prolonged immobilization that increases additional complications as pneumonia, thrombosis and muscular weakening [4]. After some unsatisfying procedures an established method was the use of vascularized soft tissue flaps [23]. When Jurkiewicz and colleagues published the first pectoral muscle flap, a lot of studies have been reported varying results with pectoral muscle flaps in poststernotomy mediastinitis [23]. Other studies advocate the technique using omentum flaps first described by Lee and coworkers for poststernotomy mediastinitis [24]. These soft tissue flaps has relatively low mortality rate according to some reports, but may be associated with flap-related morbidity.

VAC therapy is a novel wound healing method. With this method, several advantageous features of conventional treatment are combined. VAC treatment allows open drainage that continuously absorbs the

exudate with simultaneous stabilization of the mediastinal cavity and isolation of the wound. This method stimulates granulation tissue formation in combination with increased blood flow in the adjacent tissue [25, 26]. Furthermore, VAC therapy approximates the wound edges and provides a mass filling effect with low degree of surgical trauma [25-27].

In this study, we retrospectively analysed the clinical outcome and survival in 20 patients undergoing VAC therapy for Sternal wound infections after cardiac surgery.

The bacteriologic spectrum, identified in bacteriologic cultures demonstrated *Klebsiella Pneumoniae* to be the predominant pathogen whereas other studies demonstrated a majority of *S aureus* infection (40%). There was no significant difference in terms of outcome based on organism in our study.

Various studies demonstrated a significantly greater number of treatment failures with continuous irrigation compared with VAC therapy [28]. However in our study there was no treatment failure. The fistulas were obliterated completely, without sternectomy.

Previous studies have reported that mediastinitis is an independent risk factor with negative influence on long-term survival after coronary bypass graft surgery [29]. The severe infection can lead other organ malperfusions such as the heart, kidneys and grafts. In our study we observed that patients better early and long-term survival.

CONCLUSION

With the increase in life expectancy we are likely to get older, more obese and co-morbid patients, with increased chances of Sternal wound infection despite improvement in surgical techniques and antibiotic prophylaxis. Pre-op hospital stay, DM, Obesity, Severe LV Dysfunction and prolonged bypass and X clamp time have significant role to play as predisposing factors. Our study demonstrates that VAC therapy is safe and reliable option in Sternal Wound Infection, with excellent survival as compared to open dressings and irrigation for managing sternal wound infection.

REFERENCES

1. Sarr, M. G., Gott, V. L., & Townsend, T. R. (1984). Mediastinal infection after cardiac surgery. *The Annals of thoracic surgery*, 38(4), 415-423.
2. Grossi, E. A., Culliford, A. T., Krieger, K. H., Kloth, D., Press, R., Baumann, F. G., & Spencer, F. C. (1985). A survey of 77 major infectious complications of median sternotomy: a review of 7,949 consecutive operative procedures. *The Annals of thoracic surgery*, 40(3), 214-223.
3. El Oakley, R. M., & Wright, J. E. (1996). Postoperative mediastinitis: classification and

- management. *The Annals of thoracic surgery*, 61(3), 1030-1036.
4. Loop, F. D., Lytle, B. W., Cosgrove, D. M., Mahfood, S., McHenry, M. C., Goormastic, M., ... & Taylor, P. C. (1990). Sternal wound complications after isolated coronary artery bypass grafting: early and late mortality, morbidity, and cost of care. *The Annals of thoracic surgery*, 49(2), 179-187.
 5. Ridderstolpe, L., Gill, H., Granfeldt, H., Åhlfeldt, H., & Rutberg, H. (2001). Superficial and deep sternal wound complications: incidence, risk factors and mortality. *European journal of cardio-thoracic surgery*, 20(6), 1168-1175.
 6. Omran, A. S., Karimi, A., Ahmadi, S. H., Davoodi, S., Marzban, M., Movahedi, N., & Moshtaghi, N. (2007). Superficial and deep sternal wound infection after more than 9000 coronary artery bypass graft (CABG): incidence, risk factors and mortality. *BMC infectious diseases*, 7(1), 1-5.
 7. Filsoofi, F., Castillo, J. G., Rahmanian, P. B., Broumand, S. R., Silvay, G., Carpentier, A., & Adams, D. H. (2009). Epidemiology of deep sternal wound infection in cardiac surgery. *Journal of cardiothoracic and vascular anesthesia*, 23(4), 488-494.
 8. Rand, R. P., Cochran, R. P., Aziz, S., Hofer, B. O., Allen, M. D., & Verrier, E. D. (1998). Prospective trial of catheter irrigation and muscle flaps for sternal wound infection. *The Annals of thoracic surgery*, 65(4), 1046-1049.
 9. Sakamoto, H., Fukuda, I., Oosaka, M., & Nakata, H. (2003). Risk factors and treatment of deep sternal wound infection after cardiac operation. *Annals of Thoracic and Cardiovascular surgery*, 9(4), 226-232.
 10. Fleck, T. M., Koller, R., Giovanoli, P., Moidl, R., Czerny, M., Fleck, M., ... & Grabenwoger, M. (2004). Primary or delayed closure for the treatment of poststernotomy wound infections?. *Annals of plastic surgery*, 52(3), 310-314.
 11. Sjögren, J., Malmsjö, M., Gustafsson, R., & Ingemansson, R. (2006). Poststernotomy mediastinitis: a review of conventional surgical treatments, vacuum-assisted closure therapy and presentation of the Lund University Hospital mediastinitis algorithm. *European journal of cardio-thoracic surgery*, 30(6), 898-905.
 12. Catarino, P. A., Chamberlain, M. H., Wright, N. C., Black, E., Campbell, K., Robson, D., & Pillai, R. G. (2000). High-pressure suction drainage via a polyurethane foam in the management of poststernotomy mediastinitis. *The Annals of thoracic surgery*, 70(6), 1891-1895.
 13. Steingrimsson, S., Gottfredsson, M., Gudmundsdottir, I., Sjögren, J., & Gudbjartsson, T. (2012). Negative-pressure wound therapy for deep sternal wound infections reduces the rate of surgical interventions for early re-infections. *Interactive cardiovascular and thoracic surgery*, 15(3), 406-410.
 14. Ennker, I. C., Pietrowski, D., Vöhringer, L., Kojcici, B., Albert, A., Vogt, P. M., & Ennker, J. (2009). Surgical debridement, vacuum therapy and pectoralis plasty in poststernotomy mediastinitis. *Journal of plastic, reconstructive & aesthetic surgery*, 62(11), 1479-1483.
 15. Fleck, T. M., Fleck, M., Moidl, R., Czerny, M., Koller, R., Giovanoli, P., ... & Grabenwoger, M. (2002). The vacuum-assisted closure system for the treatment of deep sternal wound infections after cardiac surgery. *The Annals of thoracic surgery*, 74(5), 1596-1600.
 16. Immer, F. F., Durrer, M., Mühlemann, K. S., Erni, D., Gahl, B., & Carrel, T. P. (2005). Deep sternal wound infection after cardiac surgery: modality of treatment and outcome. *The Annals of thoracic surgery*, 80(3), 957-961.
 17. Harrington, G., Russo, P., Spelman, D., Borrell, S., Watson, K., Barr, W., ... & Aberline, M. (2004). Surgical-site infection rates and risk factor analysis in coronary artery bypass graft surgery. *Infection Control & Hospital Epidemiology*, 25(6), 472-476.
 18. Lepelletier, D., Perron, S., Bizouarn, P., Caillon, J., Drugeon, H., Michaud, J. L., & Duveau, D. (2005). Surgical-site infection after cardiac surgery: incidence, microbiology, and risk factors. *Infection Control & Hospital Epidemiology*, 26(5), 466-472.
 19. Diez, C., Koch, D., Kuss, O., Silber, R. E., Friedrich, I., & Boergermann, J. (2007). Risk factors for mediastinitis after cardiac surgery—a retrospective analysis of 1700 patients. *Journal of cardiothoracic surgery*, 2(1), 1-8.
 20. Fu-Der, W., & Chang, C. H. (2000). Risk factors of deep sternal wound infections in coronary artery bypass graft surgery. *Journal of Cardiovascular Surgery*, 41(5), 709.
 21. Lu, J. C., Grayson, A. D., Jha, P., Srinivasan, A. K., & Fabri, B. M. (2003). Risk factors for sternal wound infection and mid-term survival following coronary artery bypass surgery. *European journal of cardio-thoracic surgery*, 23(6), 943-949.
 22. Abboud, C. S., Wey, S. B., & Baltar, V. T. (2004). Risk factors for mediastinitis after cardiac surgery. *The Annals of thoracic surgery*, 77(2), 676-683.
 23. Jurkiewicz, M. J., Bostwick III, J., Hester, T. R., Bishop, J. B., & Craver, J. (1980). Infected median sternotomy wound: successful treatment by muscle flaps. *Annals of surgery*, 191(6), 738.
 24. van Wingerden, J. J., Lapid, O., Boonstra, P. W., & de Mol, B. A. (2011). Muscle flaps or omental flap in the management of deep sternal wound infection. *Interactive cardiovascular and thoracic surgery*, 13(2), 179-188.
 25. Raja, S. G., & Berg, G. A. (2007). Should vacuum-assisted closure therapy be routinely used for management of deep sternal wound infection after cardiac surgery?. *Interactive cardiovascular and thoracic surgery*, 6(4), 523-527.
 26. Fleck, T., Gustafsson, R., Harding, K., Ingemansson, R., Lirtzman, M. D., Meites, H. L., & Wetzel-Roth, W. (2006). The management of deep sternal wound

- infections using vacuum assisted closure™(VAC®) therapy. *International wound journal*, 3(4), 273-280.
27. Damiani, G., Pinnarelli, L., Sommella, L., Tocco, M. P., Marvulli, M., Magrini, P., & Ricciardi, W. (2011). Vacuum-assisted closure therapy for patients with infected sternal wounds: a meta-analysis of current evidence. *Journal of plastic, reconstructive & aesthetic surgery*, 64(9), 1119-1123.
28. Yu, A. W., Rippel, R. A., Smock, E., & Jarral, O. A. (2013). In patients with post-sternotomy mediastinitis is vacuum-assisted closure superior to conventional therapy?. *Interactive cardiovascular and thoracic surgery*, 17(5), 861-866.
29. Toumpoulis, I. K., Anagnostopoulos, C. E., DeRose Jr, J. J., & Swistel, D. G. (2005). The impact of deep sternal wound infection on long-term survival after coronary artery bypass grafting. *Chest*, 127(2), 464-471.